



# INCREASING ARTERIOVENOUS FISTULAS IN HEMODIALYSIS PATIENTS: PROBLEMS AND SOLUTIONS IN MEDICAL COLLEGES AND HOSPITALS

Sainath G V B\*

Assistant Professor of General Surgery, Bhaarith Medical College and Hospital, Chennai, (Affiliated to Bhaarith University, Chennai), Tamil Nadu, India

## ABSTRACT

Dialysis using a peripheral access which has high patient compliance is easy to use and is inexpensive. Arteriovenous fistula is very essential for dialysis and the acceptance rate of failure for this procedure is important because it is not a curative procedure. Hence a failure in the technical aspect of procedure is unacceptable for the patient and the referring nephrologists. Hence a high success rate is mandatory. This experience from us will help for the doctors to improvise the skills. Our experience we preferred the standard left radiocephalic anastomosis (2/3rds of our patient). One on the right brachiocephalic was done due to failed previous Arteriovenous fistula surgery on the left wrist and forearm. And our anastomosis are mostly done end of the vein to side of the artery (83%). Our success rate is 83% which can be improved by preoperative Doppler study which will give the flow of the vessels and then the created fistula characters. Vascular access is a simple and convenient option for people on maintenance dialysis and can be done in our centre with a good success rate. The community of the patients with end stage renal disease can benefit since it is cost effective in our centre.

**Keywords:-** Dialysis, Diabetes Mellitus, Hypertension, End Stage Renal Disease.

Access this article online

Home Page:  
[www.mcmed.us/journal/abs](http://www.mcmed.us/journal/abs)

Quick Response code



Received:24.11.2022

Revised:10.12.2022

Accepted:21.12.2022

## INTRODUCTION

In today's world with a high incidence of diabetes mellitus and hypertension, end organs damage especially to the kidneys leading to end stage renal disease (ESRD) is common. The primary treatment in these patients is renal transplant but the availability of the organ and the cost factor means that there is always a significant waiting period before a patient gets a suitable donor match. During this delay, the only solution to their problem is DIALYSIS [1]. For dialysis, the primary requirement is a central vascular access. Central line is a temporary access for dialysis and has its own associated complications including mortality [2-3]. Another form of dialysis is peritoneal dialysis which is surgically simple

but has its own set of complications and is more expensive than dialysis via peripheral access. Therefore the only option left with is dialysis using a peripheral access which has high patient compliance, is easy to use and is inexpensive. The solution is an AV FISTULA. AV fistulae (AVF) are not risk free; complications range from failure, steal phenomenon, congestive heart failure, aneurysm, stenosis of central veins (Paget schroetter syndrome) and wound complications [4-5]. The most commonly done fistula is the radiocephalic AVF which is created between the left radial artery and the distal cephalic vein.

Corresponding Author: **Dr Sainath G V B** Email: [sai.gmc@yahoo.co.in](mailto:sai.gmc@yahoo.co.in)

If this radiocephalic fails a brachiocephalic anastomosis between the brachial artery and the cephalic vein proximally is done.

### Side-to-Side Anastomosis

The advantage of side-to-side anastomosis is its technical simplicity. The disadvantage is a definite risk of venous hypertension with swelling of the hand. This can be avoided by ligation of the distal run-off vein, thus achieving a functional side-to-end anastomosis.

### End-to-End Anastomosis

The advantage of end-to-end anastomosis is that the fistula flow is limited, thus avoiding a hypercirculatory state. The disadvantage is that the anastomosis is technically more difficult. Problems particularly arise when there are large discrepancies in the luminal diameters between the artery and the vein. The most serious problem is, however, that ligation of distal limb of the radial artery may predispose to ischemia of the hand. A final disadvantage is that if venous thrombosis supervenes it will automatically extend into the arterial limb of the fistula.

### Side-to-End Anastomosis

Although several techniques for anastomosis are available, the side-to-end anastomosis has deservedly become the most commonly used technique. It is absolutely indicated when artery and vein are far apart and must be brought closely together to create an anastomosis. As a further advantage, a venous thrombosis will affect only the venous limb if it supervenes. If the fistula has to be revised, it is easy to create an anastomosis at a more proximal site. This type of anastomosis poses a number of technical problems explain the high primary malfunction rates reported in some series [6].

### Our experience

Here at our dialysis center we have an excellent nephrology team and a dialysis unit. On an average 75 patient get dialyzed every month. The patients requiring AV fistulas are referred to the department of surgery and the basic work up and general condition is looked into. The patient is explained about the procedure and the complications. Forearm exercises are taught to make the vein distend. The dominant artery at the wrist is checked by the simple Allen's test. Dialysis is preferably done within days of surgery to reduce the tissue edema and risk of post operative infection. Consent is taken for surgery.

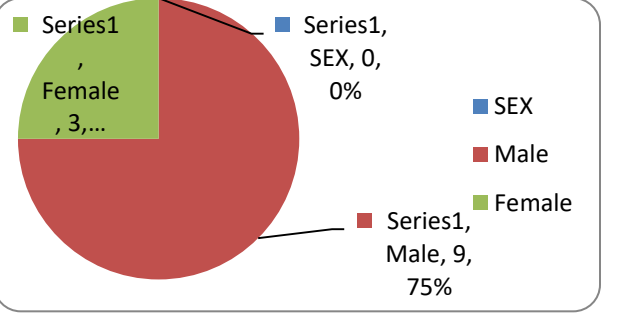
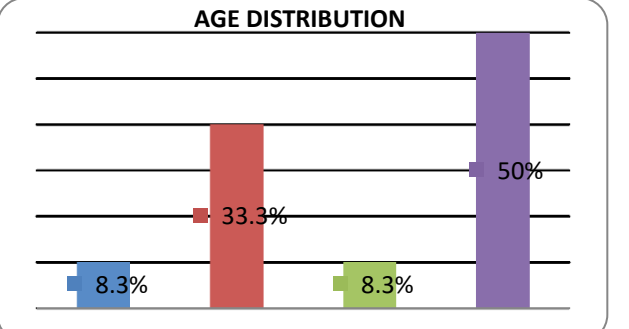
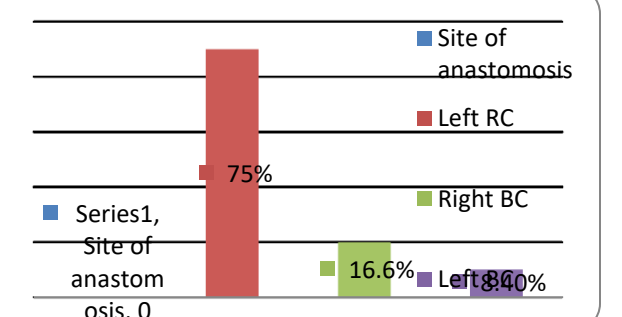
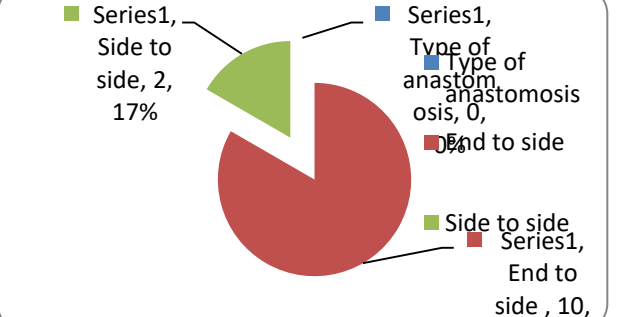
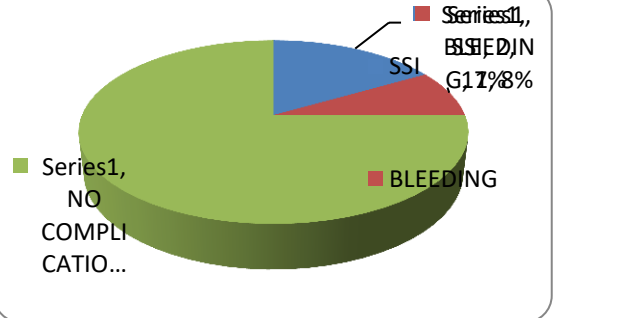
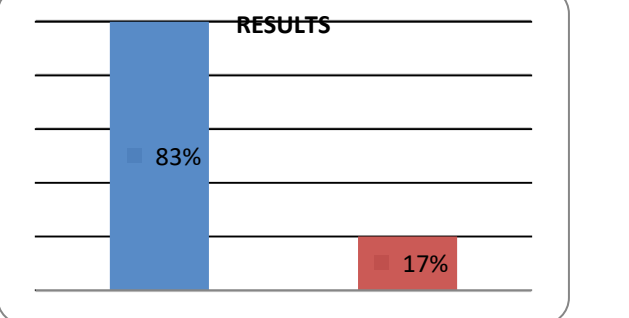
### Operative procedure

The procedure is done at Bhaarath Medical College and Hospital, under local anesthesia. Patient is supine with left arm extended supported by a hand trolley. A surgeon, skilled assistant surgeon and a scrub nurse are required. Subcutaneous 5000IU of heparin is given just prior to surgery. And an incision of about 5cms made. The vein is mobilized first then the artery. The lie of the vein is important to avoid kinking, twisting or acute angulation. A tension free anastomosis [Figure 1] is made with double arm 6-0 prolene using continuous sutures. A thrill in the venous limb of the fistula immediately after performing the anastomosis indicates a functional AV fistula. Subcutaneous tissue and skin is closed. After skin closure look for thrill again. Sterile non compressive dressing is then applied. And before shifting out of the OT the thrill is checked for again. The patient is asked to continue the hand exercises post operatively. The sutures were removed on post operative day 7 if the wound was healthy. Most fistulas mature within a month and ready for dialysis.

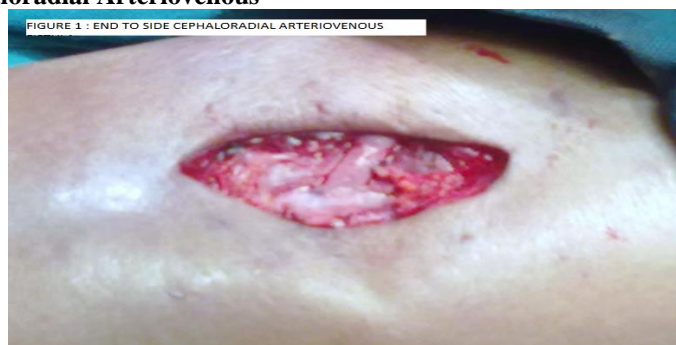**Table 1: Characteristics**

Sl.no	Sex	Age	Indications	Site of anastomosis	Type of anastomosis	Complications	Result
1	M	65	ESRD	Left RC	End to side	Nil	Failure
2	M	67	ESRD	Left RC	End to side	SSI	Working
3	F	68	ESRD	Left RC	End to side	Nil	Working
4	M	62	ESRD	Left RC	End to side	Nil	Working
5	M	60	ESRD	Left RC	End to side	Nil	Working
6	M	47	ESRD	Left RC	End to side	Nil	Working
7	F	50	ESRD	Right BC	End to side	Bleeding	Working
8	M	67	ESRD	Left BC	End to side	Nil	Working
9	M	45	ESRD	Left RC	End to side	SSI	Failure
10	M	21	ESRD	Right BC	Side to side	Nil	Working
11	F	55	ESRD	Left RC	End to side	Nil	Working
12	M	45	ESRD	Left BC	Side to side	Nil	Working

ESRD – end stage renal disease, RC- radiocephalic, BC – brachiocephalic, SSI –surgical site infections

<p><b>1. Distribution of patients with respect to sex, in our group predominantly males 75 percentage.</b></p>	<p><b>2. Age distribution- 50% of the patients were more than 60yrs of age. And 33.3% of patients were between 41 to 50yrs of age.</b></p>
 <p>Series1, Female, 3, ... Series1, Male, 9, 75% SEX, 0, 0% Male Female</p>	 <p><b>AGE DISTRIBUTION</b></p> <p>8.3% 33.3% 8.3% 50%</p>
<p><b>3. Site of the AV fistula - 75% of fistulae were left radiocephalic</b></p>	<p><b>83% (10) of our anastomosis were between end of the vein to side of the artery.</b></p>
 <p>Site of anastomosis, 0 Left RC, 75% Right BC, 16.6% Left BC, 8.4%</p>	 <p>Side to side, 2, 17% Type of anastomosis, 0, 0% End to side, 10, 83%</p>
<p><b>5. 75% of the patients had no post-operative complications.</b></p>	<p><b>6. The success rate of our series is the 83% and failure rate 17% which is at par with other centers.</b></p>
 <p>Series1, NO COMPLICATIONS, 75% Series1, BLEEDING, 17% Series1, SSI, 8%</p>	 <p><b>RESULTS</b></p> <p>83% 17%</p>

**Figure 1: End to side Cephaloradial Arteriovenous**



## DISCUSSION

The experience in Medical College and Hospital, Chennai, is a beginning to a new level of our services provided to our patients. This is the first of its kind done in the institute. That we did a successful AV fistula in a 21year old male patient after two failed fistulas done elsewhere is worth mentioning. Our results show that most of our patients are male, 75% of who are above the age of 60yrs. We preferred the standard left radiocephalic anastomosis (2/3rds of our patient). One on the right brachiocephalic was done due to failed previous AV fistula surgery on the left wrist and forearm. And our anastomosis are mostly done end of the vein to side of the

artery (83%). We had complications [7] in the form of surgical site infections in 17% which is expected in a uremic patient. One patient had bleeding due to heparin which managed with protamine. 75% had no complications. Our success rate is 83% which can be improved by preoperative Doppler study which will give the flow of the vessels and then the created fistula characters [8]. Vascular access is a simple and convenient option for people on maintenance dialysis and can be done in our centre with a good success rate. The community of the patients with end stage renal disease can benefit since it is cost effective in our centre.

## REFERENCES

1. Roy-Chaudhury P, Kelly BS, Zhang J, Narayana A, Desai P, Melham M, Duncan H, Heffelfinger SC.(2003). Hemodialysis vascular access dysfunction: from pathophysiology to novel therapies. *Blood Purif*; 21, 99-110.
2. Feldman HI, Kobrin S, Wasserstein A. (1996). Hemodialysis vascular access morbidity. *J Am Soc Nephrol*; 7, 523-35.
3. McCarley P, Wingard RL, Shyr Y, Pettus W, Hakim RM, Ikizler TA. (2001). Vascular access blood flow monitoring reduces access morbidity and costs. *Kidney Int*; 60, 1164-72.
4. Roy-Chaudhury P, Sukhatme VP, Cheung AK. (2006). Hemodialysis vascular access dysfunction: a cellular and molecular view point. *J Am Soc Nephrol*; 17, 1112-27.
5. Roy-Chaudhury P, Kelly BS, Melhem M, Zhang J, Li J, Desai P, Munda R, Heffelfinger SC. (2005). Vascular access in hemodialysis: issues, management, and emerging concepts. *Cardiol Clin*; 23, 249-73.
6. Patel ST, Hughes J, Mills JL Sr. (2003). Failure of arteriovenous fistula maturation: an unintended consequence of exceeding dialysis outcome quality initiative guidelines for hemodialysis access. *J Vasc Surg*; 38, 439-45
7. Allon M, Robbin ML: (2002). Increasing arteriovenous fistulas in hemodialysis patients: Problems and solutions. *Kidney Int* 62, 1109–1124,
8. Sivanesan S, How TV, Bakran A: (1998). Characterizing flow distributions in AV fistulae for haemodialysis access. *Nephrol Dial Transplant* 13, 3108–3110

### Cite this article:

Sainath G V B. Increasing Arteriovenous Fistulas In Hemodialysis Patients: Problems And Solutions In Medical Colleges And Hospitals. *ActaBiomedicaScientia*, 2022; 9(2),103-106.



Attribution-NonCommercial-NoDerivatives 4.0 International