



ABNORMAL BRANCHING PATTERN OF BRACHIAL ARTERY – A CASE REPORT

Saumya Shah¹ and Shaheen Sajid Rizvi^{2*}

¹Department of Anatomy, K. J. Somaiya Medical College, Somaiya Ayurvihar, Eastern Express Highway, Sion, Mumbai 400053, Maharashtra, India.

²Department of Anatomy, K. J. Somaiya Medical College, Somaiya Ayurvihar, Eastern Express Highway, Sion Mumbai 400053, Maharashtra, India.

ABSTRACT

While dissecting the right upper limb of a 70 year old donated embalmed male cadaver in the Department of Anatomy at K.J. Somaiya Medical College, Sion, Mumbai, India, I observed a high level trifurcation of the brachial artery into the radial, ulnar and common interosseous arteries. The trifurcation occurred just above the cubital fossa. The ulnar artery travelled downward superficial to the superficial flexor muscles of the forearm. The common interosseous artery was longer in length and divided at an unusual site in the cubital fossa into the anterior and posterior interosseous arteries. There were no associated altered anatomy of the nerves observed in the specimen. The variations were unilateral and the left upper limb was normal. The photographs of the high level trifurcation of the brachial artery into radial, ulnar and common interosseous artery were taken for proper documentation. Topographical anatomy of the normal and abnormal variations of the brachial artery are clinically important for surgeons, orthopaedicians operating on the supracondylar fracture of humerus and radiologists performing angiographic studies on the upper limb.

Keywords: Brachial Artery, Trifurcation, Radial Artery, Ulnar Artery, Common Interosseous Artery, Surgeons, Orthopaedicians, Radiologists, Angiographic Studies.

Access this article online

Home page:

<http://www.mcmed.us/journal/ijacr>

DOI:

<http://dx.doi.org/10.21276/ijacr.2019.6.1.4>

Quick Response code



Received:25.01.19

Revised:12.02.19

Accepted:15.02.19

INTRODUCTION

The brachial artery ends in the cubital fossa by dividing into the radial and ulnar arteries. The ulnar artery, the deeper and the larger of the two terminal branches of the brachial artery, begins a little below the bend of the elbow, and, passing obliquely downward, reaches the flexor carpi ulnaris muscle in its middle third, whereas the ulnar nerve is covered by the muscle throughout its entire course running under the tendon in the wrist region.

It then runs along the ulnar border up to the wrist, crosses the transverse carpal ligament on the radial side of the pisiform bone, and immediately beyond this bone divides into two branches, which enter into the formation of the superficial and deep palmar arches. The common interosseous artery is a short branch of the ulnar, about 1 cm. in length, arises immediately below the tuberosity of the radius from the ulnar artery. It passes back to the upper border of the interosseous membrane and divides into anterior and posterior interosseous arteries. Anterior interosseous artery descends on the anterior aspect of the interosseous membrane with the median nerve's anterior interosseous branch. Median artery, a slender branch from anterior interosseous artery, accompanies and

Corresponding Author

Dr. Shaheen Sajid Rizvi

Email: - rizvi shaheen68@gmail.com

supplies the median nerve [1]. The radial artery appears, from its direction, to be the continuation of the brachial, but it is smaller in calibre than the ulnar. It commences at the bifurcation of the brachial, just below the bend of the elbow, and passes along the radial side of the forearm to the wrist and takes part in the completion of the superficial and deep palmar arches.

CASE REPORT:

While dissecting the right upper limb of a 70 year old donated embalmed male cadaver in the Department of Anatomy at K.J. Somaiya Medical College, Sion, Mumbai, India, I observed a high level trifurcation of the brachial artery into the radial, ulnar and common interosseous arteries. The trifurcation occurred just above the cubital fossa. The ulnar artery travelled downward superficial to the superficial flexors of the

forearm and reached the flexor carpi ulnaris muscle in its middle third. It ran along the ulnar border of the forearm up to the wrist, crossed the radial side of the pisiform bone, and immediately divided into two branches, forming the superficial and deep palmar arches. Another branch, the common interosseous artery was longer in length. It divided at an unusual site in the cubital fossa into the anterior and posterior interosseous arteries. The third branch, the radial artery travelled downward along the radial side of the forearm to the wrist. There were no associated altered anatomies of the nerves observed in the specimen. The variations were unilateral and the left upper limb was normal. The photographs of the high level trifurcation of brachial artery into radial, ulnar and common interosseous artery were taken for proper documentation.

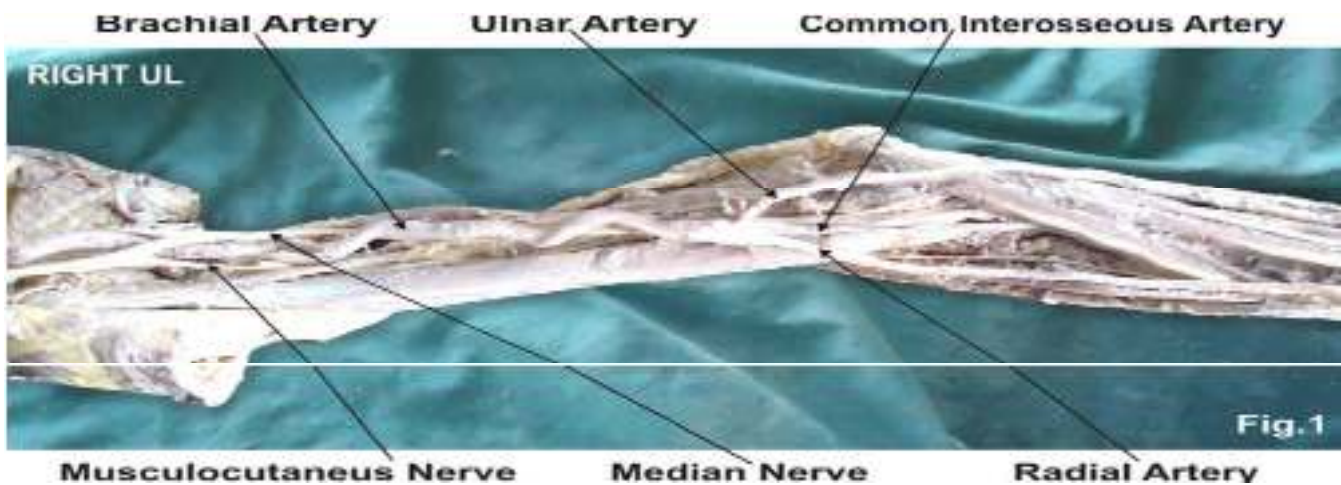


Figure 1: The photographic presentation of high level trifurcation of brachial artery into radial, ulnar and common interosseous artery. The ulnar artery travelled downward superficial to the superficial flexor muscles of the forearm. The common interosseous artery was longer in length.

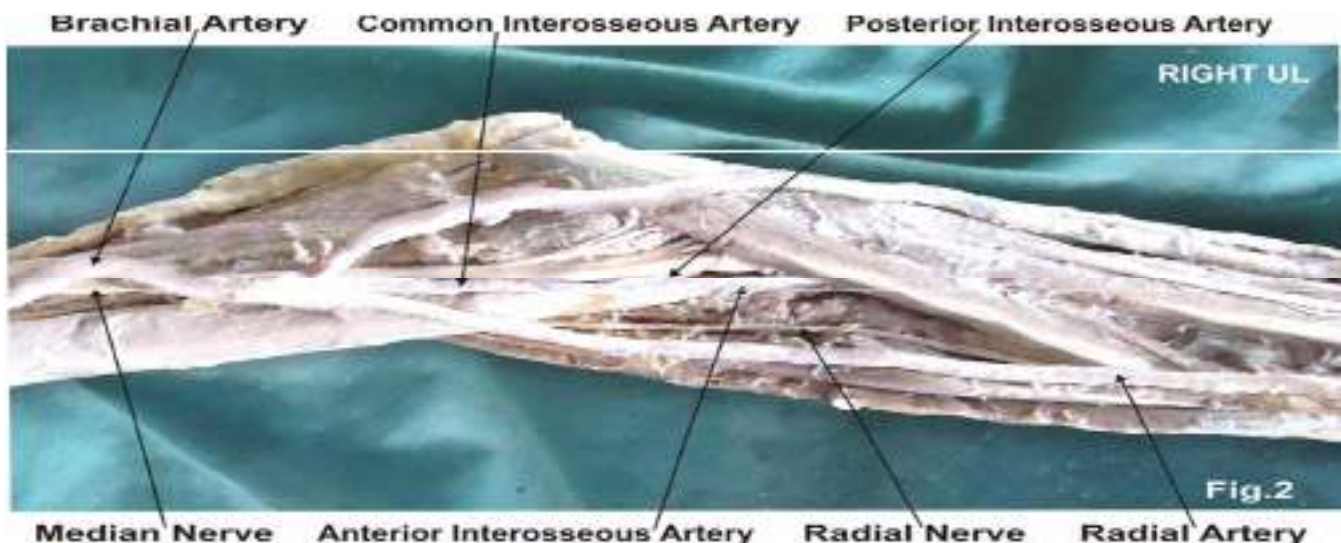


Figure 2: The photographic presentation of larger and superficial ulnar artery, smaller radial artery and unusual termination of the common interosseous artery into the anterior and posterior interosseous arteries in the cubital fossa.

DISCUSSION:

The brachial artery commonly terminates into radial and ulnar arteries within the cubital fossa. The trifurcation of the brachial artery into radial, ulnar and common interosseous arteries is uncommon [2]. In the present case the brachial artery trifurcated into the radial, ulnar and common interosseous arteries above the supracondylar line in the lower part of the arm. Various authors have made studies on termination of brachial artery. It may bifurcate proximally and reunite to form single trunk. Sometimes ulnar artery arises proximally. Rarely there may be a communicating vessel connecting axillary artery and brachial artery [3]. The supernumerary branches of brachial artery may be the radial recurrent artery or the median artery [4]. The radial recurrent arising from the lower part of brachial artery separately but not as a one of the terminal branch is reported in literature [5]. The trifurcation of brachial artery into ulnar, radial, and radial recurrent arteries in a right superior extremity of fifty years old male cadaver during dissection is documented in literature. The third branch was radial recurrent artery and the common interosseous artery was given off from the ulnar artery, which divided into anterior and posterior interosseous arteries. The radial artery was normal in that study [6]. In the present case, the brachial artery had trifurcated into ulnar, radial, and common interosseous arteries in the right upper limb. There were no communicating branches seen between radial and ulnar arteries. In high termination of brachial artery if one of the two arteries lies superficial to the superficial flexor group of muscles. The other artery is taking the usual course is crossed superficially by the median nerve [7]. In the present the ulnar artery was present superficial to the superficial flexor muscles of forearm and no aberrant artery was observed. The ulnar artery may take origin from the brachial artery proximally and then the brachial artery terminates into the radial artery and the common interosseous artery in the cubital fossa [8]. The radial artery also may take origin proximally from the brachial artery running superficial to forearm flexors or deep fascia or rarely subcutaneous. The common interosseous artery may take origin proximally [9]. Sometimes the radial artery may be absent and even the brachial artery may be absent [10].

DEVELOPMENTAL BASIS:

The seventh cervical intersegmental artery forms the axis artery of the upper limb and persists in the adult to form the axillary, brachial, and interosseous arteries. Transiently, the median artery arises as a branch of the interosseous artery, begins to regress and remains as a residual artery accompanying the median nerve [11]. The radial and the ulnar arteries are later additions to the axis artery. The ulnar artery and the median artery are branches of the axis artery [12,13]. The superficial brachial artery is a consistent embryonic vessel, coexisting or not with the brachial artery [14]. It has two

terminal branches, lateral and medial. The lateral continues as a part of the definitive radial artery [15] and the medial i. e. superficial antebrachial artery, which divides into the median and ulnar artery branches, which are the trunks of origin of the median and ulnar arteries. The arterial pattern of the upper limb develops from an initial capillary plexus by a proximal and distal differentiation, due to maintenance, enlargement and differentiation of certain capillary vessels, and the regression of others. The number of upper limb arterial variations arises through the persistence, enlargement and differentiation of parts of the initial network which would normally remain as capillaries or even regress [16].

CLINICAL SIGNIFICANCE:

The knowledge of presence of the unusual high level trifurcation of brachial artery is clinically important for clinicians, surgeons, orthopaedicians and radiologists performing angiographic studies. Undoubtedly, such variations are important for diagnostic evaluation and surgical management of vascular diseases and injuries. Therefore both the normal and abnormal anatomy of the region should be well known for accurate diagnostic interpretation and therapeutic intervention.

CONCLUSION:

These variations are compared with the earlier data & it is concluded that variations in termination in brachial artery are a rule rather than exception. The high level trifurcation of brachial artery in the lower part of arm may result in excessive haemorrhage during supracondylar fracture of the humerus. A lack of knowledge of such type of variations with different patterns may complicate the surgery and may cause unnecessary bleeding.

ACKNOWLEDGEMENT:

Authors are thankful to Dean Dr. Vinayak Sabnis Sir for his support and encouragement. Authors are thankful to Dr. S. P. Sawant, Professor and Head, Department of Anatomy for his help. Authors are also thankful to Mr. M. Murugan, Mrs. Pallavi Kadam, Mr. Shivaji Dalvi, Mr. Kishor Rangle, Mr. Shankush Adkhale, Mr. Sanjay Shinde, Mr. Kishor Beradiya and Mr. Panduj for their help. Authors also acknowledge the immense help received from the scholars whose articles are cited and included in references of this manuscript. The authors are also grateful to authors / editors / publishers of all those articles, journals and books from where the literature for this article has been reviewed and discussed.

CONFLICT OF INTEREST:

The authors declare that they have no conflict of interest.

STATEMENT OF HUMAN AND ANIMAL RIGHTS:

All procedures performed in human participants were in accordance with the ethical standards of the institutional research committee and with the 1964

Helsinki declaration and its later amendments or comparable ethical standards. This article does not contain any studies with animals performed by any of the authors.

REFERENCES:

1. Williams PL, Bannister LH, Berry MM, Collins P, Dyson M, Dussek JE and Ferguson MWJ. (1999) Gray's Anatomy. In : Cardiovascular system. Gabella G Edr. 38th Edn. Churchill Livingstone, New York, 1537-44.
2. Huber GC. (1930) Piersol's Human Anatomy. In : The vascular system. 9th Edn. Vol. 1, J.B. Lippincott Co., Philadelphia, pp.767-791.
3. Massie G. (1944) Surgical anatomy. In: the upper limb. 4th Edn., J & A Churchill Ltd, London, 1944.pp. 136-139
4. Thorek P. (1951) Anatomy in surgery. In : Superior Extremity Arm - Brachial region. 2nd Edn. J.B. Lippincott Co, Philadelphia, 702-8.
5. Sharadkumar Pralhad Sawant. (2015) Study of the level of the termination of the brachial artery. *European Journal of Molecular Biology and Biochemistry*. 2(3):133-136.
6. Patnaik VVG, Kalsey G, Singla Rajan. (2001) Trifurcation of Brachial artery-A case Report. *Journal of Anatomical Society of India*, 50(2), 163-165.
7. Rodriguez-Baeza A, Nebot J, Ferreira B, Reina F, Perez J, Sanudo JR and Rolg M. (1995) An anatomical study and ontogenic explanation of 23 cases with variations in the main pattern of the human brachio-antebrachial arteries. *Journal of Anatomy*, 187, 473-479.
8. Singer E. (1933) Embryological pattern persisting in the arteries of the arm, *Anatomical Record*, 55, 403-409.
9. Romanes GJ. (1964) Cunningham's Textbook of Anatomy. In: The Blood vascular system - arteries of the upper limb, E.W. Walls Eds. 10th Edn. Oxford University Press, New York, 885- 893.
10. Clerve A, Kahn M, Pangilinan AJ and Dardik H. (2001) Absence of the brachial artery : report of a rare human variation and review of upper extremity arterial anomalies. *Journal of Vascular Surgery*, 33, 191-194.
11. Aharinejad S, Nourani F and Hollensteiner H. (1997) Rare case of high origin of ulnar artery from the brachial artery. *Clinical Anatomy*, 10, 253-258.
12. Celik HH, Germus G, Aldur MM and Ozcelik M. (2001) Origin of the radial and ulnar arteries: variation in 81 arteriograms. *Morphologie*, 85, 25-27.
13. Suganthy J, Koshy S, Indrasingh I and Vettivel S. (2002) A very rare absence of radial artery: A case report. *Journal of the Anatomical society of India*, 51(1), 61-64.
14. Moore KL & Persand TVN. The Cardio vascular system. In the developing Human, Clinically oriented embryology.7th Ed. Elsevier, India, 2003. pp. 329-80
15. Hamilton WJ & Mossman HW. (1978) Cardiovascular System. In. Human Embryology. 4th Ed. Baltimore, Williams &Wilkins, 1978. pp. 268-72.
16. Boyd JD, Clark WE, Hamilton WJ, Yoffey JM, Zuckerman S and Appleton AB. (1956) Textbook of Human Anatomy In : Cardiovascular System - Blood vessels; MacMillan and Co. Ltd. St. Martin's Press, New York, 341-346.

Cite this article:

Saumya Shah and Shaheen Sajid Rizvi. Abnormal Branching Pattern of Brachial Artery –A Case Report. *International Journal Of Advances In Case Reports*, 6(1), 2019, 10-13. DOI: <http://dx.doi.org/10.21276/ijacr.2019.6.1.4>



Attribution-NonCommercial-NoDerivatives 4.0 International