



## OSELTAMIVIR INDUCED BRADYCARDIA

Shwetha Dharmesh, Pradeep M. Venkategowda\*, Sheetal Kamat, Ashwini Murthy

Department of Critical Care Medicine, Apollo Hospital, Sheshadripuram, Bengaluru – 560020, India.

### ABSTRACT

Oseltamivir is commonly used for Influenza viral infection. It can cause bradycardia rarely when used for influenza treatment. This is a case of 29 years old female who got admitted with history of fever, generalized weakness, cough and multiple episodes of loose stools for 3 days. She was diagnosis of acute viral pneumonia / acute gastroenteritis was made and she received levofloxacin (500mg once daily orally) and Oseltamivir (75mg twice daily orally) for 3 days at outside hospital. In our hospital the Electro-cardiogram (ECG) showed sinus bradycardia which was suspected to be due to Oseltamivir induced, hence it was stopped since. Patient had asymptomatic bradycardia hence no medication was administered for it. Just withdrawal of Oseltamivir resulted in gradually improvement in heart rate. Later patient was discharged on 4<sup>th</sup> day of admission in a hemodynamically stable condition.

**Key words:** Oseltamivir, Bradycardia, Influenza, Pneumonia.

Access this article online

Home page:

<http://www.mcmed.us/journal/ijacr>

DOI:

<http://dx.doi.org/10.21276/ijacr.2018.5.2.1>

Quick Response code



Received:21.03.18

Revised:02.04.18

Accepted:08.04.18

### INTRODUCTION

Oseltamivir is an effective drug against all strains of influenza A and B virus [1]. It acts by inhibiting neuraminidase, the enzyme necessary for the release of progeny virions from infected cells [2]. This mechanism reduces the amount and duration of viral shedding [3] causing reduction of symptoms by 0.7 to 1.5 days [4]. Oseltamivir is used in the management of uncomplicated acute influenza infection. This drug if used within 48 hours of infection then the clinical efficacy is about 60-70%.

### CASE REPORT

We present a case of 29 years old female (after informed consent) a known case of diabetes mellitus for 4 years on regular treatment (Gliclazide, Metformin and Dapagliflozin). Patient experienced fever, generalized

weakness, cough and multiple episodes of loose stools for 3 days and got admitted for the same at local hospital. Working diagnosis of acute viral pneumonia / acute gastroenteritis was made and she received levofloxacin (500mg once daily orally) and Oseltamivir (75mg twice daily orally) for 3 days. Patient got better and discharged home on 4<sup>th</sup> day. On the same day of discharge, patient experienced pain abdomen and vomiting for which she came to our hospital for further evaluation and management. In ER (Emergency room) on examination; patient was conscious, afebrile, pulse rate – 38 beats / min, blood pressure – 134/58 mmHg, respiratory rate – 22 /min and spo2 of 95% (room air). Initial lab report revealed Hb-11.2 gm/dl, TLC-3700 cells/cumm, PLT-1,43,000, Urea-18, Sr. Creatinine - 1.1, S. Sodium 143 meq/L and S. Potassium of 3.8meq/L. Electro-cardiogram (ECG) showed sinus bradycardia (Figure – 1). Investigations such as (2 Dimensional Transthoracic

#### Corresponding Author

**Pradeep M Venkategowda**

Department of Critical Care Medicine, Apollo Hospital, Sheshadripuram, Bengaluru – 560020, India.

**Email:** drpradeepmarur@gmail.com

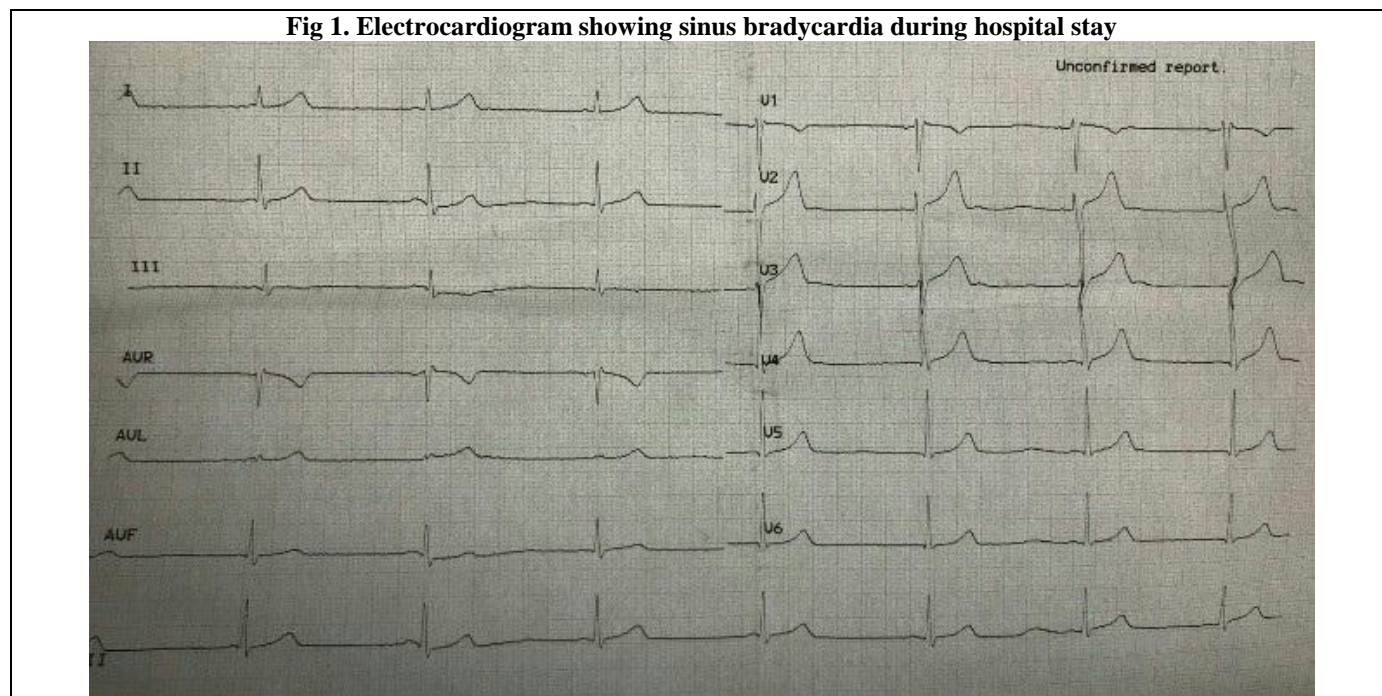
Echocardiogram) 2D-Echo, cardiac enzymes, fundus examination, thyroid function test, ultrasound abdomen, amylase and lipase enzymes were normal. Nasal and throat swab was positive for H1N1 infection. Patient received one more dose of Oseltamivir and it was stopped since we suspected that the bradycardia may be secondary

Oseltamivir. Patient had asymptomatic bradycardia (Hemodynamically stable) hence no medication was administered for it. Just withdrawal of Oseltamivir resulted in gradually improvement in heart rate (Table-1). Later patient was discharged on 4<sup>th</sup> day of admission in a hemodynamically stable condition.

**Table 1. Showing heart rate of our patient during her admission in our hospital.**

DAYS	HEART RATE
DAY - 1	38 bpm
DAY - 2	42 bpm
DAY - 3	52 bpm
DAY - 4	64 bpm

**Fig 1. Electrocardiogram showing sinus bradycardia during hospital stay**



**DISCUSSION**

Oseltamivir treatment is not without complications. Gastrointestinal side effects are most common [5, 6] which includes nausea, vomiting, abdominal pain and diarrhoea. Neuropsychiatric manifestations include insomnia, headache, dizziness, vertigo, seizures, confusion, psychological disorder and suicidal tendencies. Skin reactions, toxic epidermal necrolysis and swelling of face and tongue are minor allergic reactions. Rare side effects include liver (Hepatitis) and cardiac manifestations. Cardiovascular side effects include arrhythmias and rarely bradycardia. Torsade de pointes were not found in proarrhythmic model and action potential assay following intravenous Oseltamivir use [7]. Two suspected case of Oseltamivir induced bradycardia has been noted by Karplus R et al [8] and they concluded that the heart rate returned to normal level following stopping of the Oseltamivir treatment. The mechanism of

bradycardia is not known. The adverse drug reaction probability scale (Naranjo scale) was 6 [9] which indicate probable case of association with Oseltamivir. The ADR (Adverse drug reaction) was reported to ADR monitoring centre of our hospital.

Awareness about this rare side effect (Bradycardia) following administration of Oseltamivir can help the physicians in better management of the patient. Alternatives to Oseltamivir such as Zanamivir may be considered during such situations.

**STATEMENT OF HUMAN AND ANIMAL RIGHTS**

All procedures performed in human participants were in accordance with the ethical standards of the institutional research committee and with the 1964 Helsinki declaration and its later amendments or comparable ethical standards. This article does not contain any studies with animals performed by any of the authors

## ACKNOWLEDGEMENTS

We gratefully acknowledge the nurses and management of the hospital for their valuable support.

## DECLARATION OF INTEREST

None declared.

## REFERENCES

1. Hanshaworakul W, Simmerman JM, Narueponjirakul U, Sanasuttipun W, Shinde V, Kaewchana S et al. (2009). Severe human influenza infection in Thailand: Oseltamivir treatment and risk factors for fatal outcome, 4, 6051.
2. Bardsley EA, Noble S. (1999). Oseltamivir. *Drugs*, 58, 851-60.
3. Mendel DB, Tai CY, Escarpe PA, Li W, Sidwell RW, Huffman JH, et al. (1998). Oral administration of a prodrug of the influenza virus neuraminidase inhibitor GS 4071 protects mice and ferrets against influenza infection. *Antimicrob Agents Chemother*, 42, 640-6.
4. McNicholl IR and McNicholl JJ. (2001). Neuraminidase inhibitors: Zanamivir and oseltamivir. *Ann Pharmacother*, 35, 57-70.
5. Schirmer P, Holodny M. (2009). Oseltamivir for treatment and prophylaxis of influenza infection. *Expert Opin Drug Saf*, 8, 357-71.
6. Treanor JJ, Hayden FG, Vrooman PS, Barbarash R, Bettis R, Riff D, et al. (2000). Efficacy and safety of the oral neuraminidase inhibitor oseltamivir in treating acute influenza: A randomized controlled trial. *JAMA*, 283, 1016-24.
7. Nakamura Y, Sugiyama A. (2016). Intravenous anti-influenza drug Oseltamivir will not induce Torsade de pointes: Evidences from proarrhythmia model and action-potential assay. *Drugs*, 131, 72-75.
8. Karplus R, Sanset S, Zaidenstein R, Schneider D, Berkovitch M. (2010). Suspected Oseltamivir-induced bradycardia. *Clinical Pharmacology*, 145, 374-375.
9. Naranjo CA, Busto U, Sellers EM, Sandor P, Ruiz L, Roberts EA et al. (1981). A method for estimating the probability of adverse drug reactions. *ClinPharmacolTher*, 30, 239-45.

### Cite this article:

Shwetha Dharmesh, Pradeep M. Venkategowda, Sheetal Kamat, Ashwini Murthy. Oseltamivir Induced Bradycardia. International Journal Of Advances In Case Reports, 5(1), 2018,13-15.DOI: <http://dx.doi.org/10.21276/ijacr.2018.5.2.1>



Attribution-NonCommercial-NoDerivatives 4.0 International