



MORNING GLORY DISC ANOMALY: A CASE REPORT

Rakesh Verma^{1*}, Neebha Anand², Sunil Verma³

¹Resident, Department of Ophthalmology, RIO (PGIMS) Rohtak, Haryana, India.


²Professor, Department of Ophthalmology, RIO (PGIMS) Rohtak, Haryana, India.

³Resident, Department of Ophthalmology, BPS Government Medical College for Women, Khanpur Kalan, Haryana, India.

ABSTRACT

A rare case of congenital anomaly of the optic disc is presented to draw attention to the occurrence of this anomaly in rural India. The typical case presented with excavated, enlarged colobomatous optic nerve head filled with glial tissue surrounded by peripapillary pigmentary abnormalities. Ocular complications in affected eye may include reduced visual acuity, strabismus, and retinal detachment. Contralateral eye may also be involved as a part of anterior chamber cleavage syndrome. Comprehensive ophthalmic examination of both eyes using various ocular investigations for its early diagnosis and of associated systemic disorders and complications is essential.

Key words: Congenital anomalies, Morning glory, Optic disc anomaly.

Access this article online		
Home page: http://www.mcmed.us/journal/ijacr DOI: http://dx.doi.org/10.21276/ijacr.2017.4.8.2	Quick Response code 	
Received:02.12.17	Revised:10.12.17	Accepted:12.12.17

INTRODUCTION

Morning glory disc anomaly (MGDA) is a rare congenital malformation that results from incomplete formation of the optic nerve in utero [1]. This condition has been first reported by Pedlar in 1961. According to Pedlar [2] the defect was secondary to faulty closure of the posterior sclera with herniation of the optic disc. The term was coined by Kindler in 1970 because of the resemblance of malformed optic nerve head with the tropical morning glory flower [3]. Usually, the condition presents unilaterally [2,4] and is reported more commonly in women [2,5,6] However, there are rare cases of bilateral presentation [7]. The embryonic origin of this syndrome is still not known [8]. The most likely developmental interruption occurs at the 4–5 weeks stage of embryonic growth [9]. In contrast, Pollock argued that there was distal optic stalk dysgenesis, which failed to close, leaving

anomalous persistence of the optic cup cavity into the optic stalk[6]. This report reviewed the clinical features and characteristics of MGDA and its possible systemic associations, with the role of various ocular investigations in its diagnosis.

Case Report

An 8-year-old boy presented for eye examination in Outpatient department. According to his father, the boy was not able to see clearly for distance from right eye since early childhood. The birth history and family history were not eventful and mental status was normal. His best corrected visual acuity for distance with cycloplegic refraction was Oculus Dexter (Right eye) (OD) –3.5 Dioptic Spherical (DS), –1.5 Dioptic Cylindrical (DC) × 110°, 6/18; Oculus Sinister (Left eye) (OS) –0.25 DS, 6/6 using Snellen's chart. Examination of anterior segment and intraocular pressures were within the normal range (Goldman applanation tonometry OD=13 mmHg; OS =16 mmHg). Ocular alignment was orthophoric and extra ocular movements were full in all directions of gazes. Keratometric values were OD K1/K2 43.00/43.50 and OS

Corresponding Author

Dr. Rakesh Verma

Resident, Department of Ophthalmology, RIO (PGIMS) Rohtak, Haryana, India.

Email: verma.rakesh88@gmail.com

K1/K2 42.00/42.50. Fundus examination of RE presented an enlarged and excavated funnel-shaped disc with elevated tuft of glial tissue (whitish tissue) centrally, thin radial retinal vessels emerging at the margins of the optic disc from under the central tissue and followed a relatively straight course to the periphery of the retina with annulus of peripapillary pigmentary changes. The A/V ratio was approximately 1/1.5. The foveal reflex was dull with no involvement of macula in the excavation, and peripheral retina was intact without suggestion of retinal detachment figure 1.

Fundus of left eye (LE) was normal. B-scan ultrasonography RE, at posterior pole, showed an anomalous excavation conoid in shape with the disc at the base. Scan of posterior pole of LE was normal. Magnetic resonance imaging (1.5 T) of the cranium and both the

orbits with gadolinium reveals mild bilateral peritrigonal leukomalacia with mildly thickened right optic nerve with prominent CSF sleeve. Cirrus High Definition (Spectral Domain) Optical Coherence Tomography (HD-OCT) RE showed [Figure 2] centrally excavated enlarged disc (disc area 2.56 mm²) with enlarged C: D ratio and loss of neuroretinal rim with reduced retinal nerve fibre layer thickness in superior, nasal and temporal quadrant. Normal central macular sub-field thickness implicated the sparing of macula as shown in (figure 3). Scan for LE was found to be within the normal limit.

Fundus fluorescein angiography (FFA) was done to look for any determined retinal break or fluid in sub-retinal layer in the posterior pole. Both eye images were normal.

Figure 1. (a) RE colored fundus photograph showing an enlarged and excavated funnel-shaped optic disc with an elevated central tuft of whitish glial tissue with thin radiating retinal vessels emerging at the optic disc margin from under the central tissue and following a relatively straight course to the periphery of the retina with annulus of peripapillary pigmentary changes. (B) Fundus of left eye was normal.

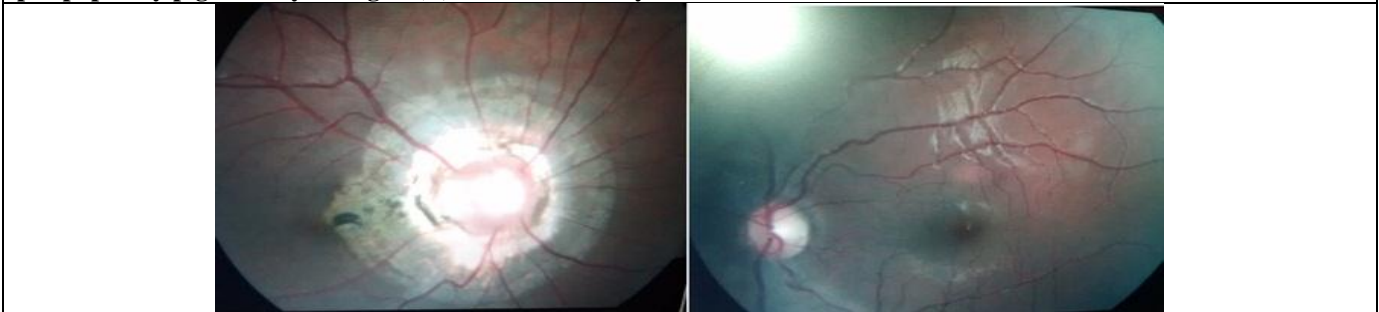


Figure 2. Cirrus HD-OCT RE shows centrally excavated disc with enlarged C:D ratio and reduced retinal nerve fibre layer thickness.

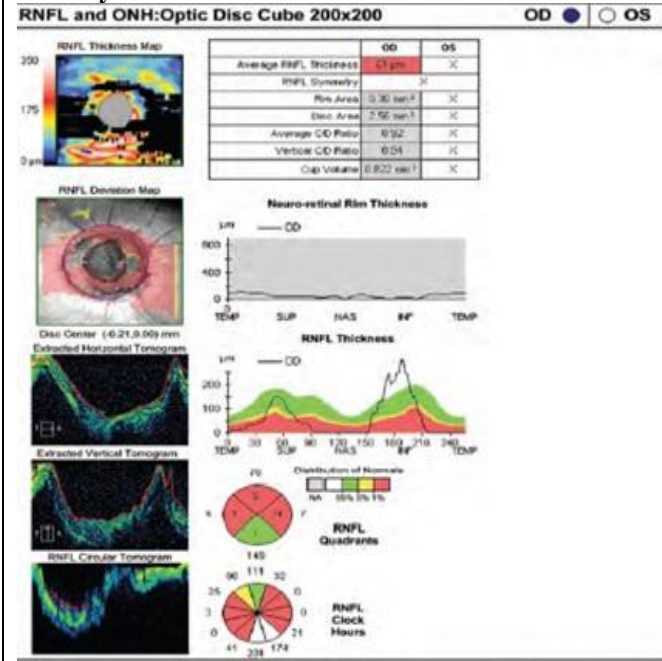
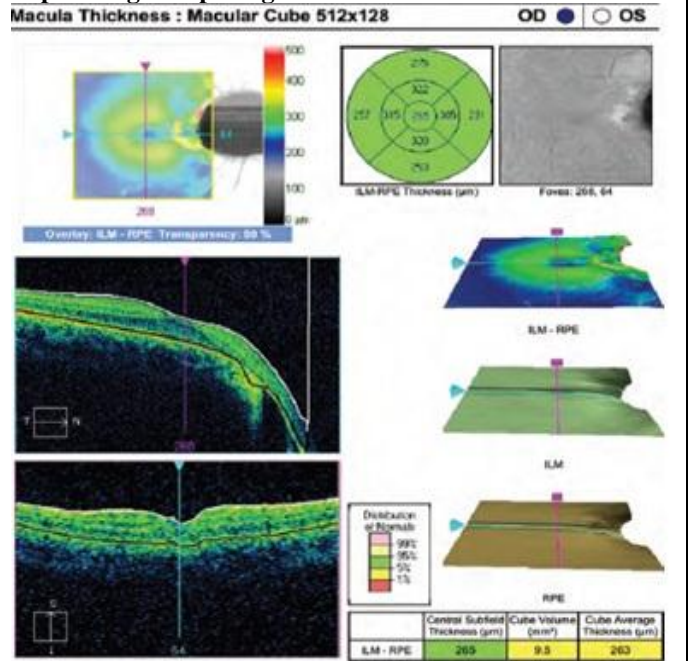


Figure 3. Cirrus HD-OCT RE macular cube (512x128) scan shows normal central macular sub-field thickness implicating the sparing of macula.



DISCUSSION

The diminution of vision in Morning Glory Syndrome (MGS) may be because of the presence of macular abnormalities or secondary to development of anisometropic or strabismic amblyopia [9]. In our case, the cause of reduced visual acuity in RE is anisometropic amblyopia. OCT analysis (quantitative) of a case of isolated MGDA by Srinivasan et al^[10] showed an enlarged optic disc and cup with increased RNFL thickness temporally, thus violating inferior, superior, nasal and temporal (ISNT) rule and subnormal macular thickness. This case report shows an enlarged optic disc and cup with thinning of RNFL and normal macular thickness. OCT plays a significant role in early diagnosis and evaluation of possible sub-retinal fluid, thus providing information regarding the pathogenesis and associated clinical features [11]. Various systemic associations have been well documented in MGS [4-6] including congenital forebrain abnormalities such as basal encephalocele (trans-sphenoidal and sphenothmoidal) and endocrine alterations [9] midline facial defects including hypertelorism, cleft lip or cleft palate[4,5,12] renal hypoplasia and other renal abnormalities[5]. Rarely, it can, however, be associated with syndromes such as Aicardi's syndrome[13] and Down's syndrome[14]. It should be differentiated from other congenital optic disc anomalies such as optic disc coloboma and peripapillary staphyloma. Typical optic disc coloboma is bilateral and presents as a central crater that may resemble glaucomatous cupping. In peripapillary

staphyloma there is developmental weakness of the posterior sclera leading to stretching of choroid and exposure of sclera with normal appearing sunken optic disc below the surrounding retinal level. As a result of variable presentation, various ocular investigations such as B-scan, OCT and FFA are only helpful in confirming the diagnosis and early detection of complications. In view of the presence of a tuft of whitish tissue within the colobomatous elevated optic disc and abnormal presentation of central retinal vessels, our case would be best classified as a case of isolated MGDA. It is non-progressive in nature and does not require treatment [12]. However, because of its association with other ocular anomalies, high risk for developing neuro-sensory retinal detachment and possible systemic abnormalities, early accurate diagnosis and monitoring are essential. Management of a patient with MGDA requires advising the patient about the need for protective eyewear for two compelling reasons. As the individual with MGDA usually has useful vision in only one eye, preservation of sight in the normal eye is essential. The strong association between MGDA and retinal detachment also means that contact sports should be avoided, and if this is not possible, protective eyewear designed to reduce the risk of ocular trauma should be worn. Educating the patient about the symptoms of retinal detachment will also be helpful as prompt medical attention may prevent aggravation of the detachment and will allow close monitoring of the condition.

REFERENCES

1. Magrath GN, Cheeseman EW, Sarrica RA. Morning glory disc anomaly. *Pediatr Neurol*, 49, 2013, 517.
2. Pedlar C. Unusual coloboma of the optic nerve entrance. *Br J Ophthalmol*, 45, 1961, 803-7.
3. Kindler P. Morning glory syndrome: Unusual congenital optic disk anomaly. *Am J Ophthalmol*, 69, 1970, 376-84.
4. Jacobs M, Taylor D. The systemic and genetic significance of congenital optic disk anomalies. *Eye*, 5, 1991, 470-5.
5. Jackson W, Freed S. Ocular and systemic abnormalities associated with morning glory syndrome. *Ophthalmic Pediatr Genet*, 5, 1985, 111-5.
6. Pollock S. The morning glory disc anomaly: Contractile movement, classification, and embryogenesis. *Doc Ophthalmol*, 65, 1987, 439-60.
7. Murphy BL, Griffi JF. Optic nerve coloboma (morning glory syndrome): CT findings. *Radiology*, 191, 1994, 59-61.
8. Golnik KC. Cavitory anomalies of the optic disc: Neurologic significance. *Curr Neurol Neurosci Rep*, 8, 2008, 409-13.
9. Debney S, Vingrys AJ. Case report: The morning glory syndrome. *Clin Exp Optom*, 73, 1990, 31-5.
10. Srinivasan G, Venkatesh P, Garg S. Optical coherence tomographic characteristics in morning glory disc anomaly. *Can J Ophthalmol*, 42, 2007, 307-9.
11. Cennamo G, de Crecchio G, Lacarino G, Forte R, Cennamo G. Evaluation of morning glory syndrome with spectral optical coherence tomography and echography. *Ophthalmology*, 117, 2010, 1269-73.
12. Steinkuller PG. The morning glory disk anomaly: Case report and literature review. *J Pediatr Ophthalmol Strabismus*, 17, 1980, 81-7.
13. Ganesh A, Mitra S, Koul RL, Venugopalan P. The full spectrum of persistent fetal vasculature in Aicardi syndrome: An integrated interpretation of ocular malformation. *Br J Ophthalmol*, 84, 2000, 227-8.
14. Cao XG, Li XX, Bao YZ. Morning glory syndrome associated with posterior lenticonus. *Open Neurol J*, 3, 2009, 45-7.

Cite this article:

Rakesh Verma, Neebha Anand, Sunil Verma .Morning Glory Disc Anomaly: A Case Report. *International Journal Of Advances In Case Reports*, 4(8), 2017, 250-252. DOI: <http://dx.doi.org/10.21276/ijacr.2017.4.8.2>