



SOLITARY PLEXIFORM NEUROFIBROMATOSIS PRESENT ON LOWER BACK: A RARE CASE REPORT


AK Agarwal^{1*}, Nishant Kumar², Digvijay Mishra³, Sourav Shukla⁴

Vivekananda Polyclinic & Institute of Medical Sciences, – 226007, Lucknow, Uttar Pradesh, India.

ABSTRACT

Neurofibroma is a benign tumour of peripheral nerves and presents with cosmetic & functional impairment in some of the cases, we present a case of Plexiform Neurofibromatosis who presented to us as stunted growth in a girl child. She was having soft swelling in her lower back, with multiple café-au-lait macules & MRI finding revealed Plexiform Neurofibromatosis around dorsolumbar area.

Key words: Plexiform, Neurofibromatosis, lumbar spine.

Access this article online		
Home page: http://www.mcmed.us/journal/ijacr	Quick Response code 	
DOI: http://dx.doi.org/10.21276/ijacr.2017.4.7.2		
Received:25.06.17	Revised:12.07.17	Accepted:29.07.17

INTRODUCTION

Neurofibromatosis is term derived from neural tissue which is also associated with various other clinical features. Although it is of various types, most common form is neurofibromatosis 1 which is also called as von Recklinghausen disease and often present in 90 % of all patient suffering from neurofibromatosis. It is the most common single gene disorder reported 1 in 2600 to 3000 people approximately [1]. We present case of 8 year old girl child with multiple hyper pigmented macules along with plexiform neurofibromatosis on lower back having problem of short stature only.

CASE REPORT

History

A female aged 8 years presented in our orthopaedic surgery opd VPIMS, Lucknow with complaints of short stature with mild to moderate swelling in lower back, her mother noticed small swelling 2 years after birth and was worried for the same. There is no

Corresponding Author

AK Agarwal

Email:- drashokagarwal@yahoo.co.in

significant history of fever, injury, drug intake. She is having two brothers and one sister and all of them are normal without similar complaints. Antenatal history – mother was having uneventful antenatal period. Natal and Postnatal history – within normal limit

On examination

General examination: well built, active, well oriented with no lymphadenopathy

Systemic examination: Cardio – respiratory, Renal, Hepatobiliary systems showed no abnormality

PHYSICAL EXAMINATION

Dermatological manifestation: A total of nine café au lait spot > 0.5 cm with mild swelling at the back of lumbar region (fig 1, 2) are present on whole body, in trunk dorsal side has two and ventral side has five cafe – au – lait macules, while upper extremity have one and lower extremity on left side has one largest of all of size 5 cm cafe – au – lait macule. No axillary freckling or cutaneous neurofibromatosis seen in her.

Local examination:

Soft swelling of 4 cm X 5 cm size present in lower lumbar area with feel of worms in bag (fig 3,4). The swelling is non tender without rise of local temperature, no tuft of hair in lower back, presence of obliteration of lumbar lordosis. The neurological examination of both lower limbs is within normal limit with no bowel bladder dysfunction. Ophthalmic examination revealed no LISCH nodule and optic glioma.

LAB AND IMAGING STUDIES

The standard laboratory test values were in normal range, Digital X-ray of Dorsolumbar spine anterior-posterior and lateral (fig 5) showed incomplete fusion of spinous process of Lumbar vertebrae 5.

MRI of dorsal lumbar spine with screening of whole spine (fig no 6) showed ill-defined heterogeneously enhancing soft tissue mass lesion in the skin and subcutaneous fat plane of the back extending from D12 to L5 levels with no vertebral destruction or extension into spinal canal ? Neoplastic lesions (plexiform neurofibroma)

USG: High Resolution Sonography reveals findings suggestive of homogenous soft tissue mass over the mid line of lumbar spine with multiple vessels feeding the mass: possibility of vascular tumour cannot be ruled out (fig 7).

DIAGNOSIS

The diagnosis of NF 1 was made by presence of any two or more of following diagnostic criteria: [2]

Table 1 Diagnostic Criteria for NF1

- a) 6 or more café-au-lait spots, >0.5 cm in prepubertal children >1.5 cm in postpubertal individuals
- b) Two or more neurofibromas of any type, or one or more plexiform neurofibromas
- c) Freckling in axillae or groin
- d) Optic glioma
- e) two or more Lisch nodules
- f) dysplasia of the sphenoid ; dysplasia or thinning of long bone
- g) First degree relative with NF1

Fig 1. showing cafe-au-lait macules in back of the child

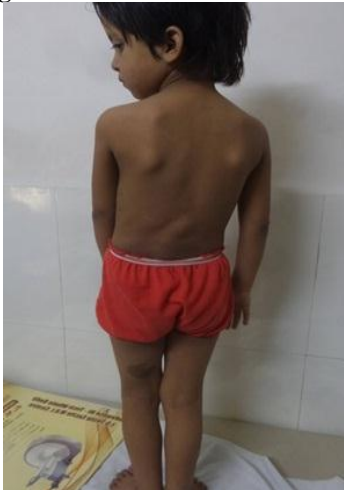

Fig 2. showing cafe-au-lait macules in front of the child

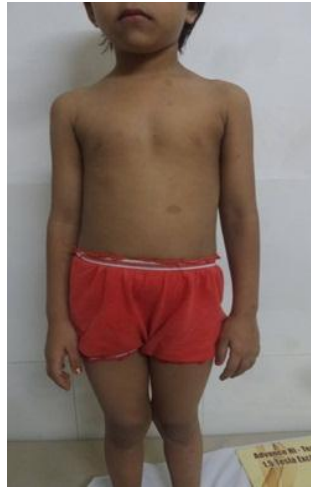

Fig 3. showing soft swelling in lower dorso-lumbar area

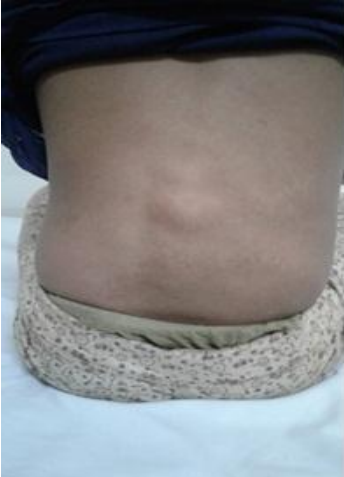

Fig 4. showing soft swelling in back

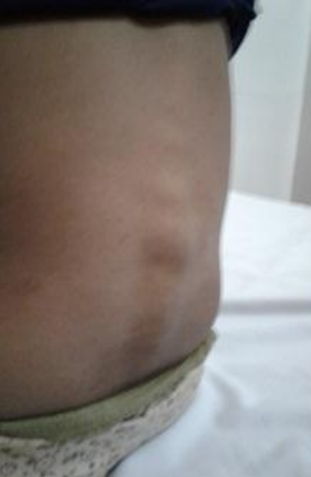

Fig 5. Digital Xray of dorso-lumbar spine anteroposterior and lateral view showing incomplete fusion of spinous process of dorso-lumbar vertebrae 5

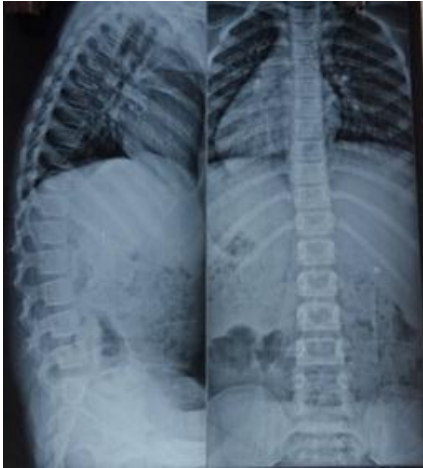


Fig 6. MRI Dorsolumbar spine shows ill-defined heterogeneously enhancing soft tissue mass lesion in the skin and subcutaneous fat plane of the back extending from D12 to L5 levels with no vertebral destruction or extension into spinal canal? Neoplastic lesions (plexiform neurofibroma)

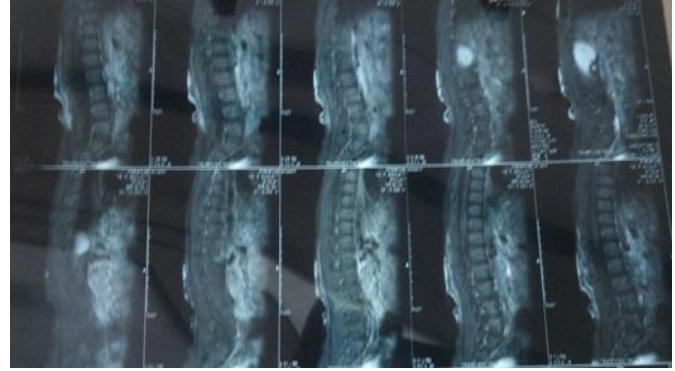
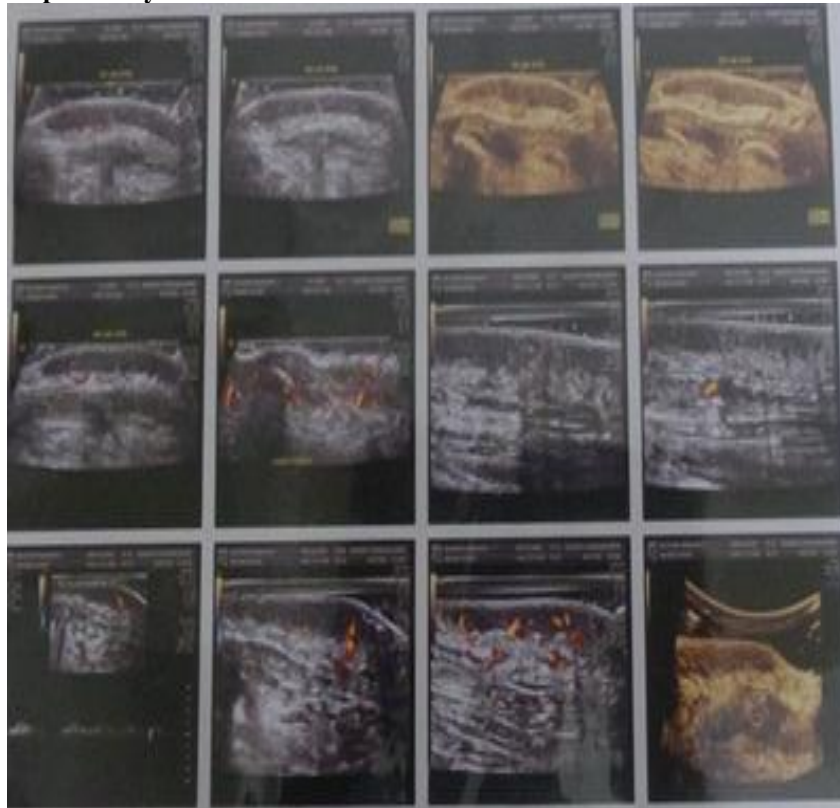

Fig 7. USG shows findings suggestive of homogenous soft tissue mass over the mid line of lumbar spine with multiple vessels feeding the mass: possibility of vascular tumour cannot be ruled out



DISCUSSION

In the present case, out of seven diagnostic criteria, A and B were present hence diagnosis of Neurofibromatosis type 1 was made in present case.

The literature shows solitary Plexiform Neurofibromatosis as a solitary subcutaneous cord running on abdominal wall where in histologically diagnosis of

Plexiform Neurofibroma was made by Aloï FG and Massobrio R [3].

Another case was reported having swelling of calf and muscular weakness where in MRI demonstrated abnormal signal and diffuse enlargement of Gastrocnemius muscle followed by diagnosis of Plexiform Neurofibroma was made on histological examination by Sullivan TP [4].

Korf BR [5] reported Plexiform Neurofibromas are among the most common debilitating complication of neurofibromatosis of type – I. Huson SM et al [6] (1988) reported the complication of von Recklinghausen Neurofibromatosis in his cohort (n = 135 unless stated) were Plexiform Neurofibromas (40/125), severe mental retardation (1), epilepsy (6), optic glioma (2), spinal neurofibroma (2), aqueduct stenosis (2), meningioangiomas (1), scoliosis requiring surgery (6), pseudoarthrosis (3), delayed puberty (2), visceral and endocrine tumours (6), and congenital glaucoma (1). Another study in relation to short stature in children and adult with Neurofibromatosis published by Vassilopoulou-Sellin R et al [7] concluded that the children with neurofibromatosis are short and have increased risk of becoming short adult.

Agarwal –et al [8] published a case of plexiform neurofibromatosis presented as Pachydermatocele in one lower limb , with degenerative changes in hip and knee joints of affected limb, this patient was operated and debulking procedure and excessive loose skin was removed from thigh and leg along with subcutaneous fascia, extra fat. His microscopic examination revealed diffuse neurofibroma.

The obliteration of lumbar lordosis is generally seen due to trauma, infection (Pott’s spine) and neoplastic lesion. In the present case we have ruled out trauma, tuberculosis and tumour as probable causes of lumbar lordosis obliteration. Finally diagnosis was based on presence of multiple cafe – au – lait macules, mild soft swelling and MRI finding of spine shows ill-defined

heterogeneously enhancing soft tissue mass lesion in the skin and subcutaneous fat plane of the back extending from D12 to L5 levels with no vertebral destruction or extension into spinal canal Neoplastic lesions (plexiform neurofibroma).

We should always have high degree of suspicion when child presents with retarded growth along with obliteration of lumbar lordosis with soft swelling having feeling of bag full of worms along with multiple cafe – au –lait macules, the possibility of plexiform neurofibromatosis should be kept. The diagnosis is confirmed by MRI of involved part that is spine in present case.

CONCLUSION

We hereby present a case of young female child with general physical growth retardation having obliteration of lumbar spine along with soft swelling due to Plexiform Neurofibromatosis.

Acknowledgement: None.

Conflict of interest:

The authors declare that they have no conflict of interest.

Statement of human and animal rights:

All procedures performed in human participants were in accordance with the ethical standards of the institutional research committee and with the 1964 Helsinki declaration and its later amendments or comparable ethical standards. The article does not contain any studies with animals performed by any of the authors.

REFERENCES

1. Lammert M, Friedman JM, Kluwe L, Mautner VF. (2005) Prevalence of neurofibromatosis 1 in German children at elementary school enrollment. *Arch Dermatol*, 141(1), 71-74.
2. Kevin P. Boyd, Bruce R. Korf, Amy Theos. (2009) Neurofibromatosis type 1. *J Am Acad Dermatol*. 2009 Jul; 61(1), 1–16.
3. Aloï FG, Massobrio R. (1989) Solitary plexiform neurofibroma. *Dermatologica*, 179(2), 84-86.
4. Sullivan TP, Seeger LL, Doberneck SA, Eckardt JJ. (1994) Case report 828: Plexiform neurofibroma of the tibial nerve invading the medial and lateral gastrocnemius muscles and plantaris muscle. *Skeletal Radiol*, 23(2), 149-152.
5. Korf BR. (1999) Plexiform neurofibromas. *Am J Med Genet*, 89(1), 31-37.
6. Huson SM, Harper PS, Compston DA. (1988) Von Recklinghausen neurofibromatosis. A clinical and population study in south-east Wales. *Brain*, (Pt 6), 1355-1381.
7. Vassilopoulou-Sellin R, Woods D, Quintos MT, Needle M, Klein MJ. (1995) Short stature in children and adults with neurofibromatosis. *Pediatr Nurs*, 21(2), 149-153.
8. Agarwal AK, Gupta Anil Kumar, Kumar Dileep, Kumar Vijay, Yadav Ganesh. (2013) Plexiform Neurofibromatosis with Abnormal Pachydermatocele: A Rare Case Report. *Indian Journal of Physical Medicine & Rehabilitation*, 4(4), 110-113.

Cite this article:

Agarwal AK, Nishant Kumar, Digvijay Mishra, Sourav Shukla. Solitary Plexiform Neurofibromatosis Present On Lower Back: A Rare Case Report. *International Journal Of Advances In Case Reports*, 4(7), 2017, 230-233.

DOI: <http://dx.doi.org/10.21276/ijacr.2017.4.7.2>



Attribution-NonCommercial-NoDerivatives 4.0 International