



VARIANT EXTENSOR CARPI RADIALIS LONGUS IN FOREARM– A CASE REPORT

Komal L. Daswani^{1*}, Sharadkumar P. Sawant², Shaheen Rizvi³

¹First MBBS, ²Professor and Head, ³Assistant Lecturer, Department of Anatomy, K. J. Somaiya Medical College, Somaiya Ayurvihar, Eastern Express Highway, Sion, Mumbai-400 022, Maharashtra, India.

ABSTRACT

During routine dissection, of the right upper limb of 70 years old donated embalmed male cadaver in the Department of Anatomy, K.J. Somaiya Medical College, Sion, Mumbai, India, we observed the variant extensor carpi radialis longus muscle. The extensor carpi radialis brevis was absent and the extensor carpi radialis longus was giving two tendons in the second compartment of extensor retinaculum before its insertion while passing deep to the abductor pollicis longus. The one tendon of extensor carpi radialis longus inserted into the radial side of the dorsal surface of the base of the second metacarpal bone while the other tendon inserted into the lateral dorsal surface of the base of the third metacarpal bone, with a few fibres inserting into the medial dorsal surface of the second metacarpal bone. The variant extensor carpi radialis longus was supplied by the radial nerve. The finding was noted after thorough and meticulous dissection of the upper limbs of both sides. The arterial pattern of upper limb was also observed. The variation was unilateral. The left upper limb was normal. The photographs of the variations were taken for proper documentation. The variant extensor carpi radialis longus muscle is clinically important for surgeons dealing with entrapment or compressive neuropathies, orthopaedicians operating on the fractures of the lower end of the humerus, anaesthetist performing pain management therapies on the upper limb and physiotherapist doing electromyography for evaluating and recording the electrical activity produced by skeletal muscles. A lack of knowledge of such type of variations might complicate surgical repair.

Key words: Extensor Carpi Radialis Longus, Variation, Radial Nerve, Surgeons, Compressive Neuropathies, Orthopaedicians, Fractures, Anaesthetist, Pain Management Therapy, Physiotherapist, Electromyography.

Access this article online

Home page:

<http://www.mcmed.us/journal/ijacr>

DOI:

<http://dx.doi.org/10.21276/ijacr.2017.4.3.18>

Quick Response code



Received:25.02.17

Revised:12.03.17

Accepted:25.03.17

INTRODUCTION

The extrinsic extensor muscles of the hand are located in the back of the forearm and have long tendons connecting them to bones in the hand, where they exert their action. Extrinsic denotes their location outside the hand. Extensor denotes their action which is to extend, or

open flat, joints in the hand. They include the extensor carpi radialis longus, extensor carpi radialis brevis, extensor digitorum, extensor digiti minimi, extensor carpi ulnaris, abductor pollicis longus, extensor pollicis brevis, extensor pollicis longus, and extensor indicis [1]. The extensor carpi radialis longus has the most proximal origin of the extrinsic hand extensors. It originates just distal to the brachioradialis at the lateral supracondylar ridge of the humerus, the lateral intermuscular septum, and by a few fibers at the lateral epicondyle of the humerus. Distal to this, the extensor carpi radialis brevis, extensor digitorum,

Corresponding Author

Komal L. Daswani

Department of Anatomy, K.J. Somaiya Medical College, Somaiya Ayurvihar, Eastern Express Highway, Sion, Mumbai-400 022, Maharashtra, India.

Email: komal.l.daswani@gmail.com

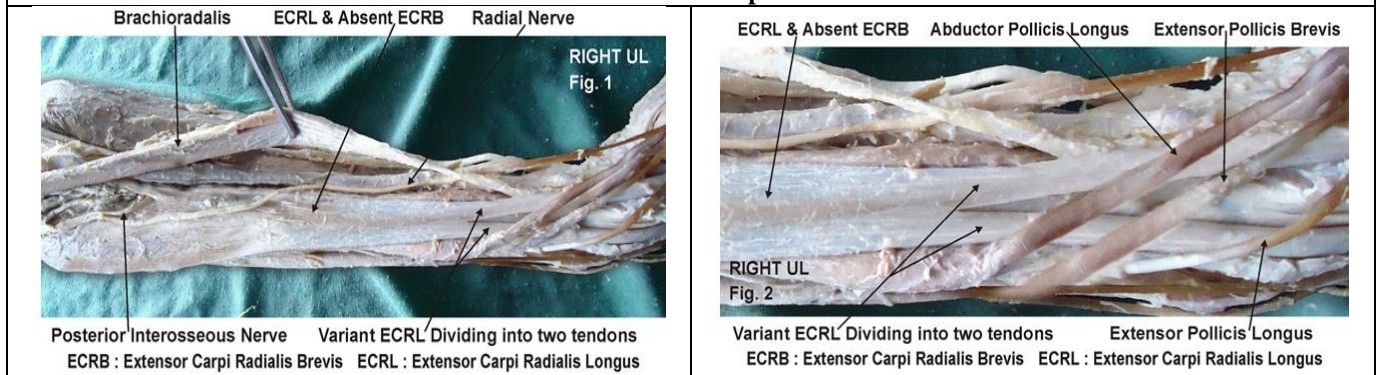
extensor digiti minimi, and extensor carpi ulnaris originate tendon. The extensor carpi radialis brevis has additional origins from the radial collateral ligament, the extensor carpi ulnaris from the dorsal border of the ulna (shared with the flexor carpi ulnaris and flexor digitorum profundus), and all four also originate from various fascia. The extensor carpi radialis longus and extensor carpi radialis brevis, (with the brachioradialis) form the lateral compartment. Their muscle fibers end at the upper third and the mid forearm respectively, continuing as flat tendons along the lateral border of the radius, beneath the abductor pollicis longus and extensor pollicis brevis. They then pass beneath the extensor retinaculum and dorsal carpal ligament, where they lie in a groove on the back of the radius, immediately behind the styloid process, and continue into the second tendon compartment. The extensor carpi radialis longus inserts into the dorsal surface of the base of the second metacarpal bone on its radial side to extend and abduct the wrist. The extensor carpi radialis brevis inserts into the lateral dorsal surface of the base of the third metacarpal bone, with a few fibres inserting into the medial dorsal surface of the second metacarpal bone, also to extend and abduct the wrist [2]. The extensor carpi ulnaris is supplied by the ulnar artery [3]. The abductor pollicis longus, extensor pollicis brevis, extensor pollicis longus, extensor indicis extensor digitorum and extensor digiti minimi are supplied by the posterior interosseous artery, a branch of the ulnar artery. The extensor carpi radialis longus and extensor carpi radialis brevis receive blood from the radial artery [4]. The extensor carpi radialis longus and extensor carpi radialis brevis muscles may split into two or three tendons of insertion to the second and third or even the fourth metacarpal. The two muscles may unite into a single belly with two tendons. The cross slips

from the lateral epicondyle via the common extensor between the two muscles may occur. The extensor carpi radialis intermedius rarely arises as a distinct muscle from the humerus, but is not uncommon as an accessory slip from one or both muscles to the second or third or both metacarpals. The extensor carpi radialis accessorius is occasionally found arising from the humerus with or below the extensor carpi radialis longus and inserted into the first metacarpal, the abductor pollicis brevis, the first dorsal interosseous, or elsewhere [5].

Case Report:

During routine dissection, of the right upper limb of a 70 years old donated embalmed male cadaver in the Department of Anatomy, K.J. Somaiya Medical College, Sion, Mumbai, India, we observed the variant extensor carpi radialis longus muscle. The extensor carpi radialis brevis was absent and the extensor carpi radialis longus was giving two tendons in the second compartment of extensor retinaculum before its insertion while passing deep to the abductor pollicis longus. The one tendon of extensor carpi radialis longus inserted into the radial side of the dorsal surface of the base of the second metacarpal bone while the other tendon inserted into the lateral dorsal surface of the base of the third metacarpal bone, with a few fibres inserting into the medial dorsal surface of the second metacarpal bone. The variant extensor carpi radialis longus was supplied by the radial nerve. The finding was noted after thorough and meticulous dissection of the upper limbs of both sides. The arterial pattern of upper limb was also observed. The variation was unilateral. The left upper limb was normal. The photographs of the variations were taken for proper documentation.

Figure 1 showing the photographic presentation of the variant extensor carpi radialis longus dividing into two tendons and the absent extensor carpi radialis brevis.



DISCUSSION

The variations in the superficial group of extensors are rarely observed. Occasionally the aberrant muscle slips are seen among the superficial group of extensors of forearm [6]. The accessory head of extensor carpi radialis longus travelled through a separate

compartment of the extensor retinaculum and inserted in the middle of the first metacarpal bone was documented in the literature [7]. In the present case extensor carpi radialis longus was passing as two tendons in the second compartment of extensor retinaculum before its insertion. The supernumerary tendons of the extensor carpi radialis

longus and the extensor carpi radialis brevis were found in literature whereas the presence of an accessory tendon making the union between the tendons of the extensor carpi radialis longus and the extensor carpi radialis brevis was also registered [9]. In tennis elbow the muscle involved is the extensor carpi radialis brevis [9]. The non-inflammatory, chronic degenerative changes occurs in the origin of the extensor carpi radialis Brevis muscle [10]. The knowledge of the variant extensor carpi radialis longus muscle is important before injecting corticosteroid injections in the treatment of tennis elbow [11]. The surgeons performing Z-shaped tenotomy on tennis elbow to lengthen the tendon of extensor carpi radialis brevis must be aware of this variation in order to avoid unwanted complications [12, 13]. Recently, extensor carpi radialis brevis has also gained importance for use in 'free functional muscle transfer' i.e. transfer of a muscle with its motor nerve and vascular pedicle from one site of the body to another distant site, in order to restore the motor function [14,15]. The knowledge of the variations is thus important while extensor carpi radialis brevis muscle is being harvested. In lower mammals the two extensores carpi radiales are represented by one muscle. Anatomical variations always have underlying cause as developmental arrest in the different stages of gestation. Ontogeny repeats phylogeny hence, the pattern of muscular arrangement in this case can be said to be less evolved than the usual arrangement [16].

Clinical significance

The variant extensor carpi radialis longus muscle is clinically important for surgeons dealing with entrapment or compressive neuropathies, orthopaedicians operating on the fractures of the lower end of the humerus, anaesthetist performing pain management therapies on the

upper limb and physiotherapist doing electromyography for evaluating and recording the electrical activity produced by skeletal muscles. A lack of knowledge of such type of variations might complicate surgical repair.

CONCLUSION

The variant extensor carpi radialis longus muscle with absent extensor carpi radialis brevis muscle is a rare occurrence. The knowledge of such variation is important for plastic surgeons performing 'free functional muscle transfer' and the extensor tendon repair.

Acknowledgement:

Authors are thankful to Dean Dr. Vinayak Sabnis Sir for his support and encouragement. Authors are also thankful to Mr. M. Murugan, Mrs. Pallavi Kadam, Mr. Shivaji Dalvi, Mr. Kishor Rangle, Mr. Shankush Adkhale, Mr. Sanjay Shinde, Mr. Kishor Beradiya and Mr. Panduj for their help. Authors also acknowledge the immense help received from the scholars whose articles are cited and included in references of this manuscript. The authors are also grateful to authors / editors / publishers of all those articles, journals and books from where the literature for this article has been reviewed and discussed.

Conflict of Interest

The authors declare that they have no conflict of interest.

Statement of Human and Animal Rights

All procedures performed in human participants were in accordance with the ethical standards of the institutional research committee and with the 1964 Helsinki declaration and its later amendments or comparable ethical standards. This article does not contain any studies with animals performed by any of the authors.

REFERENCES

1. Williams PL, Bannister LH, Berry MM, Collins P, Dyson M, Dussek JE, et al. (2005). The Nervous system. In: *Gray's Anatomy*, 39th edn, Churchill Livingstone, New York, 879 - 880.
2. Hamilton WJ. (1976) *Textbook of the Human Anatomy*, 2nd edn, Macmillan Press Ltd., London, 651.
3. Last RJ. (1984) *Anatomy: Regional and Applied*, 7th edn, Churchill Livingstone, Edinburgh, 89.
4. Snell RS. (1995) *Clinical Anatomy for Medical Students*, 5th edn, Little Brown and Company, USA, 434.
5. Tountas CP, Bergman RA. (1993) *Anatomic variations of the upper extremity*, Churchill Livingstone, New York, 11.
6. Hollinshead WH. (1969) *Anatomy for Surgeons. The Back and Limbs*. Vol 3. 2nd Ed. Harper and Row Publishers, New York, pp.428-41.
7. Claassen H & Wree A. (2002) Multiple variations in the region of Mm. extensores carpi radialis longus and brevis. *Ann. Anal*, 754, 489-91.
8. Caetano FM, Albertoni MW, Caetano BE & Pérez MR. (2004) Anatomical study of insertions of the extensor carpi radialis longus and brevis. *Int. J. Morphol*, 22(4), 245-51.
9. Garden RS. (1961) Tennis elbow. *J Bone Joint Surg*, 43B(1), 100-106.
10. Kalainov D, Cohen MS. (2005) Posterolateral rotatory instability of the elbow in association with lateral epicondylitis. A report of three cases. *J Bone Joint Surg Am*, 87(5), 1120-1125.
11. Edwards SG, Calandruccio JH. (2003) Autologous blood injections for refractory lateral epicondylitis. *J Hand Surg [Am]*, 28(2), 272-278.
12. Boyer MI, Hastings H (1999). Lateral tennis elbow: Is there any science out there?. *Journal of Shoulder and Elbow Surgery*, 8 (5), 481-91.

13. Meyer NJ, Walter F, Haines B, Orton D, Daley RA. (2003) Modeled evidence of force reduction at the extensor carpi radialis brevis origin with the forearm support band. *J Hand Surg [Am]*, 28(2), 279–287.
14. Binhammer P, Manktelow RT, Haswell T. (1994) Applications of the extensor carpi radialis brevis for facial reanimation. *Journal of Reconstructive Microsurgery*, 10, 109.
15. Bergman RA, Thompson SA, Afifi, AK & Saddeh, FA. (1988) *Copendium of Human Anatomical Variation*. Urban and Schwarzenburg, Baltimore, pp.138-9.
16. Anson BJ & McVay CB. (1971) *Surgical Anatomy*. 5th ed. W.B. Saunders Company, Philadelphia, pp.1012-7

Cite this article:

Komal L. Daswani, Sharadkumar P. Sawant, Shaheen Rizvi. Variant extensor carpi radialis longus in forearm– a case report. *International Journal Of Advances In Case Reports*, 4(3), 2017, 161-164.

DOI: <http://dx.doi.org/10.21276/ijacr.2017.4.3.18>



Attribution-NonCommercial-NoDerivatives 4.0 International