



MEDIAN NERVE PASSING THROUGH BICEPS BRACHII MUSCLE

Prasad S. Desale¹, Sharadkumar P. Sawant², Shaheen Rizvi³

¹First MBBS, ²Professor and Head, ³Assistant Lecturer, Department of Anatomy, K. J. Somaiya Medical College, Somaiya Ayurvihar, Eastern Express Highway, Sion, Mumbai-400 022, Maharashtra, India.

ABSTRACT

During the routine dissection of the axillary region and the arm for the undergraduate student on a 75 years old donated embalmed cadaver in the department of Anatomy of K.J.Somaiya Medical College, Sion, Mumbai, India, the median nerve was found passing through supernumerary head of biceps brachii muscle. This was observed on the right upper limb of a male cadaver. The short and long heads have their normal origin, supernumerary head had originated from the anteromedial surface of the superior part of the shaft of the humerus. The common tendon then got inserted into the posterior rough part of the radial tuberosity. The knowledge of such variations is important for anatomists and clinicians especially for plastic surgeons in flap surgery. The photographs of the variations were taken for proper documentation.

Key words: Biceps brachii muscle, Supernumerary head of biceps brachii, Median nerve, Plastic surgeons.

Access this article online

Home page:

<http://www.mcmed.us/journal/ijacr>

DOI:

<http://dx.doi.org/10.21276/ijacr.2017.4.3.10>

Quick Response code



Received:25.02.17

Revised:12.03.17

Accepted:25.03.17

INTRODUCTION

The biceps brachii is a muscle with two heads in the flexor compartment of the arm. The short head arises from the tip of coracoid process along with the coracobrachialis and, the long head from the supraglenoid tubercle of scapula. The origin of long head is intracapsular and extra synovial. The tendon of the long head then descends on the humerus lying in the bicipital groove. The two heads of the muscle fuse in the middle of the arm forming a common tendon and inserts on the radial tuberosity and into the deep fascia on the medial aspect of the forearm by an aponeurotic band named bicipital aponeurosis (also called lacertus fibrosis). The muscle is the prime supinator of the forearm and a powerful flexor of the elbow joint as well. It is also a weak flexor of the shoulder joint. The biceps brachii muscle is innervated by the musculocutaneous nerve [1,2].

Many authors have documented variations of biceps brachii muscle [3,4,5,6]. It is well known that a Supernumerary Head may extend from the superomedial part of the brachialis to the bicipital aponeurosis and medial side of the tendon in 10 % of the cases [1].

CASE REPORT

During the routine dissection of the axillary region and the arm for the undergraduate student on a 75 years old donated embalmed cadaver in the department of Anatomy of K. J. Somaiya Medical College, Sion, Mumbai, the median nerve was found passing through supernumerary head of biceps brachii muscle. This was observed on the right upper limb of a male cadaver. The short and long heads have their normal origin; supernumerary head had originated from the anteromedial surface of the superior part of the shaft of the humerus. The common tendon then got inserted into the posterior rough part of the radial tuberosity. After piercing the accessory head the median nerve descends over the brachialis muscle and enters to the forearm passing between the two heads of

Corresponding Author

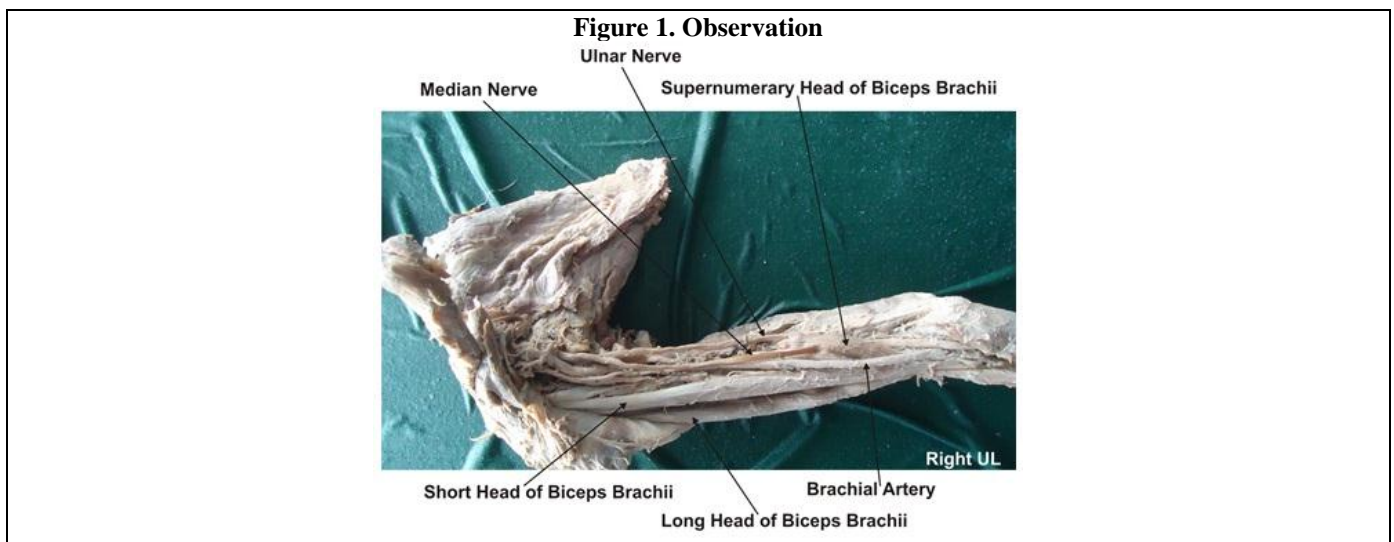
Prasad S. Desale

Department of Anatomy, K.J. Somaiya Medical College, Somaiya Ayurvihar, Eastern Express Highway, Sion, Mumbai-400 022, Maharashtra, India.

Email: pdesale9999@gmail.com

pronator teres in its usual course. It was observed that the accessory head was innervated by the muscular branches of musculocutaneous nerve as the main two heads. The

vascular supply of this third head was also the brachial artery.



DISCUSSION:

The variations of the biceps brachii muscle are very common [4,6,7,8,9]. According to some authors the most frequent variations of biceps brachii was in the number of the bellies [10] Supernumerary heads of the biceps brachii can be three-, four-, five or even seven headed biceps brachii [11] Supernumerary third head of Biceps brachii is frequently reported in literature [6]. Racial difference is found in the number of supernumerary heads i.e. in 8% of Chinese, 10% of European populations, 12% of African blacks, and 18% of Japanese population (7). A high incidence of the third head has also been reported in South African Blacks (20.5%), as compared to the African Whites (8.3%) [4]. Though some of the authors claim that there were no clear racial differences, some of them mention significant differences between the populations [4,10,12,13,14].

As found in literature it has been concluded that in the white race the incidence of the accessory heads of the biceps brachii muscle was relatively rare, high in the yellow race and intermediate in Blacks [15]. No significant differences in the prevalence of variations has been reported between male and female or between left and right sides, but the variation was high unilaterally [6]. Classification of the accessory heads is according to their location as superior, infero-medial, and infero-lateral humeral heads. The most commonly seen one was the infero-medial humeral head (9%) in which the accessory head was continuous with the insertion of the coracobrachialis muscle and closely related to medial intermuscular septum and brachialis muscle. According to the literature the three principal origins of the accessory head of biceps brachii muscle were the humeral shaft

inferior to and common with the insertion area for the coracobrachialis muscle, a brachial origin where the muscle originated distally from the medial humeral shaft, adjacent to and in common with the brachialis muscle or a dual origin where the medial fibers originated from the short head of biceps brachii muscle and the lateral fibers from the deltoid fascia and the insertion area of this muscle. In another study an accessory head has been reported arising from the distal part of the pectoralis major muscle [16]. In another study an accessory head was seen originating from the anterior surface of the humerus distal to the crest of the lesser tubercle and was lying behind the long and short heads of biceps brachii [11]. The accessory third head of biceps brachii observed in the present study arises from the anteromedial surface of humeral shaft just lateral to the insertion of coracobrachialis as it was in the study by many authors [4,6]. It lies just between the bellies of biceps brachii and brachialis muscles and inserts into the posterior aspect of the common biceps tendon as reported in literature [11], but the dual origin of the accessory head in the present study should be emphasized; a few fibers from the medial side of the accessory head arise from the fascia of brachialis muscle. Those fibers were seen crossing the median nerve before inserting into the common tendon of biceps brachii. In other words the median nerve was piercing the accessory head before entering into the forearm.

Clinical Significance

The presence of accessory head of the muscle may cause compression on the median nerve since it passes between the fibers of the accessory head. So, information

on such a variation is of importance for the differential diagnoses of the other compression causes such as enlarged veins [17,18] or a fibrovascular band [19]. Biceps brachii is without doubt a considerable component in plastic surgery [20,21] but it is known that accessory heads of biceps brachii would be expandable and possibly has more value in flap surgery rather than the two main heads. In the cases such as presented in this study the nerve or the vascular structure piercing the accessory head would probably cause difficulty during elevating or transferring the flaps.

CONCLUSION:

The knowledge of such variations is important for anatomists and clinicians for preventing untoward complications during surgery especially for plastic surgeons in flap surgery.

ACKNOWLEDGEMENT:

Authors are thankful to Dean Dr. Vinayak Sabnis Sir for his support and encouragement. Authors are also

thankful to Mr. M. Murugan, Mrs. Pallavi Kadam, Mr. Shivaji Dalvi, Mr. Kishor Rangle, Mr. Sankush Adkhale, Mr. Sanjay Shinde, Mr. Kishor Baradiya and Mr. Panduj for their help. Authors also acknowledge the immense help received from the scholars whose articles are cited and included in references of this manuscript. The authors are also grateful to authors / editors / publishers of all those articles, journals and books from where the literature for this article has been reviewed and discussed.

CONFLICT OF INTEREST

The authors declare that they have no conflict of interest.

STATEMENT OF HUMAN AND ANIMAL RIGHTS

All procedures performed in human participants were in accordance with the ethical standards of the institutional research committee and with the 1964 Helsinki declaration and its later amendments or comparable ethical standards. This article does not contain any studies with animals performed by any of the authors.

REFERENCES:

1. Williams PL, Warwick R, Dyson M & Bannister LH. (1989). *Gray's Anatomy*. 37th ed. Edinburgh, Churchill Livingstone, 1989.
2. Snell RS. *Clinical Anatomy*. (2004). 7th ed. Lipincott Williams & Wilkins.
3. Kosugi K, Shibata S & Yamashita H. (1992.) Supernumerary head of biceps brachii and branching pattern of the musculocutaneous nerve in Japanese. *Surg. Radiol. Anat*, 14, 175-85.
4. Asvat, R, Candler P & Sarmiento EE. (1993). High incidence of the third head of biceps brachii in South African populations. *J. Anat*. 182, 101-4.
5. Jakubowicz M & Ratajczak W. (2000). Variation in morphology of the biceps brachii and coracobrachialis muscles associated with abnormal course of blood vessels and nerves. *Folia Morphol. (Warsz)*, 58, 255-8.
6. Rodriguez-Niedenführ N, Vazquez T, Choi D, Parkin I & Sanudo JS. (2003) Supernumerary humeral heads of the biceps brachii muscle revisited. *Clin. Anat*, 16, 197-203.
7. Bergman RA, Thompson SA & Afifi AK. (1984). *Catalogue of Human Variation*. Munich, Urban and Schwarzenberg. 27-30.
8. Greig HW, Anson BJ & Budinger JM. (1952). Variations in the form and attachments of the biceps brachii muscle. *Bull. Northwest Univ. Med Sch*, 26, 241-4.
9. Tamura H. (1971). Case of the brachial biceps with two accessory heads in each. *Kaibogaku Zasshi*, 46, 12-6.
10. Bergman RA, Afifi AK & Miyauchi R. (2000). Part I, Muscular system. In, *Illustrated encyclopedia of human anatomic variation*.
11. Swieter MG & Carmichael SW. (1980). Bilateral three-headed biceps brachii muscles. *Anat. Anz*, 148, 346-9.
12. Nakatani T, Tanaka S, Mizukami S. (1998). Bilateral four headed biceps brachii muscles, the median nerve and brachial artery passing through a tunnel formed by a muscle slip from the accessory head. *Clin Anat*, 11, 209-12.
13. Neto HS, Camilli JA, Andrade JCT, Filho JM & Marques MJ. (1998). On the incidence of the biceps brachii third head in Brazilian whites and blacks. *Ann. Anat*, 180, 69-71.
14. El-Naggar MM & Zahir FI. (2001). Two bellies of the coracobrachialis muscle associated with a third head of the biceps brachii muscle. *Clin Anat*, 14, 379-82.
15. Khaledpour C. (1985). Anomalies of the biceps muscle of the arm. *Anat. Anz*, 58, 79-85.
16. Sargon FM, Tuncali D & Celik H. (1996). An unusual origin for the accessory head of biceps brachii muscle. *Clin Anat*, 9, 160-2.
17. Braun RM, Spinner RJ. (1991). Spontaneous bilateral median nerve compressions in the distal arm. *J Hand Surg*. 16, 244-7.
18. Holtzman RN, Patel MR & Mark MH. Median nevre neuralgia caused by a fibrovascular band in the distal forearm. *J. Hand Surg*, 11, 894-5.
19. Muneuchi D, Suzuki S, Ito O, Saso Y. (1986). One-stage reconstruction of both the biceps brachii and triceps brachii tendons using a free anterolateral thigh flap with a fascial flap. *J. Reconstr. Microsurg*, 20, 139-42, 2004.

20. Willcox TM, Teotia SS, Smith AA & Rawlings JM. (2002). The biceps brachii muscle flap for axillary wound coverage. *Plast. Reconstr. Surg*, 110, 822-6.
21. Har-Shai Y, Kaufman T, Hasmonai M, Hirsowitz B & Schramek A. (1988). External longitudinal splitting of the biceps brachii muscle for coverage of repaired brachial vessels, an anatomical study and clinical application. *Ann Plast Surg*, 21, 158-64.

Cite this article:

Prasad S. Desale, Sharadkumar P. Sawant, Shaheen Rizvi. Median nerve passing through biceps brachii muscle. *International Journal Of Advances In Case Reports*, 4(3), 2017, 133-136.

DOI: <http://dx.doi.org/10.21276/ijacr.2017.4.3.10>



Attribution-NonCommercial-NoDerivatives 4.0 International