



AN UNUSUAL ORIGIN OF MUSCULOCUTANEOUS AND ULNAR NERVE FROM MEDIAN NERVE

Shriya Ravichandran^{1*}, Sharadkumar P. Sawant², Shaheen Rizvi³

¹First MBBS, ²Professor and Head, ³Assistant Lecturer, Department of Anatomy, K. J. Somaiya Medical College, Somaiya Ayurvihar, Eastern Express Highway, Sion, Mumbai-400 022, Maharashtra, India.

ABSTRACT

During routine dissection of a 60 year old embalmed male cadaver in the department of Anatomy at K. J. Somaiya Medical College, Sion, Mumbai, India, the unusual origin of musculocutaneous and ulnar nerve from median nerve were observed in the right upper limb. The thorough and meticulous dissection of axilla, arm, forearm and palm of both the upper limbs were done to note the course of the median nerve. However, the distribution of the anomalous median nerve was normal in arm, forearm and palm. The arterial pattern in the arm (axillary and brachial arteries) was also normal. The photographs of the variations were taken for proper documentation. The median nerve and its roots are close to the axillary vein, which is used as the most cranial limit for axillary lymph node dissection, a procedure used in treating certain tumours, such as breast carcinoma and melanoma. The variations in the formation, course & distribution of median nerve are clinically important for surgeons, orthopaedicians and anaesthetist performing pain management therapies on the upper limb. These variations are compared with the earlier data & it is concluded that variations in branching pattern of cords of brachial plexus are a rule rather than exception. A lack of awareness of variations with different patterns might complicate surgical repair and may cause ineffective nerve blockade.

Key words: Brachial Plexus, Anomalous Median Nerve, Lateral Roots, Breast Carcinoma, Surgeons, Pain Management Therapy.

Access this article online

Home page:

<http://www.mcmed.us/journal/ijacr>

DOI:

<http://dx.doi.org/10.21276/ijacr.2017.4.3.3>

Quick Response code



Received:25.02.17

Revised:12.03.17

Accepted:25.03.17

INTRODUCTION

The arm is particularly vulnerable to neurological injury due to an intimate anatomical relationship between the brachial plexus and the traction zones. The brachial plexus has two fixed points, an upper one at the vertebrae and a lower one at the axillary fascia. During surgery, the combination of the arm abduction and the contralateral rotation of the head increases the stretch on the brachial plexus. Similarly, the posterior positioning of the abducted arm creates a considerable traction on it [1].

Kroll et al (1990) found ulnar neuropathies to be the most frequent causes of nerve injury litigations for pain, suffering and financial losses (33%), followed by brachial plexus injuries, which represented 23% of all the nerve injuries [2]. The risk factors which are attributed to such injuries include abnormal posture, anaesthetic agents [1], spinal analgesia, prolonged hospitalization, neuropathies and the last but the most important one, the anatomical anomalies. Apart from the surgeons, the variations in the nerves which supply the upper limb are of interest, not only to the radiologists who interpret plain computerized imagings and MRI and anaesthesiologists who place needles in the neck to administer anaesthetic blocks, but also to the neurosurgeons, neurologists, vascular surgeons and orthopaedic surgeons [3].

Corresponding Author

Shriya Ravichandran

Department of Anatomy, K.J. Somaiya Medical College, Somaiya Ayurvihar, Eastern Express Highway, Sion, Mumbai-400 022, Maharashtra, India.

Email: shriya1407@gmail.com

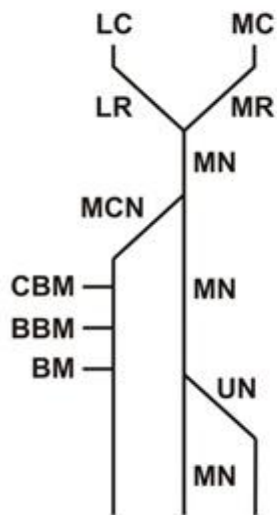
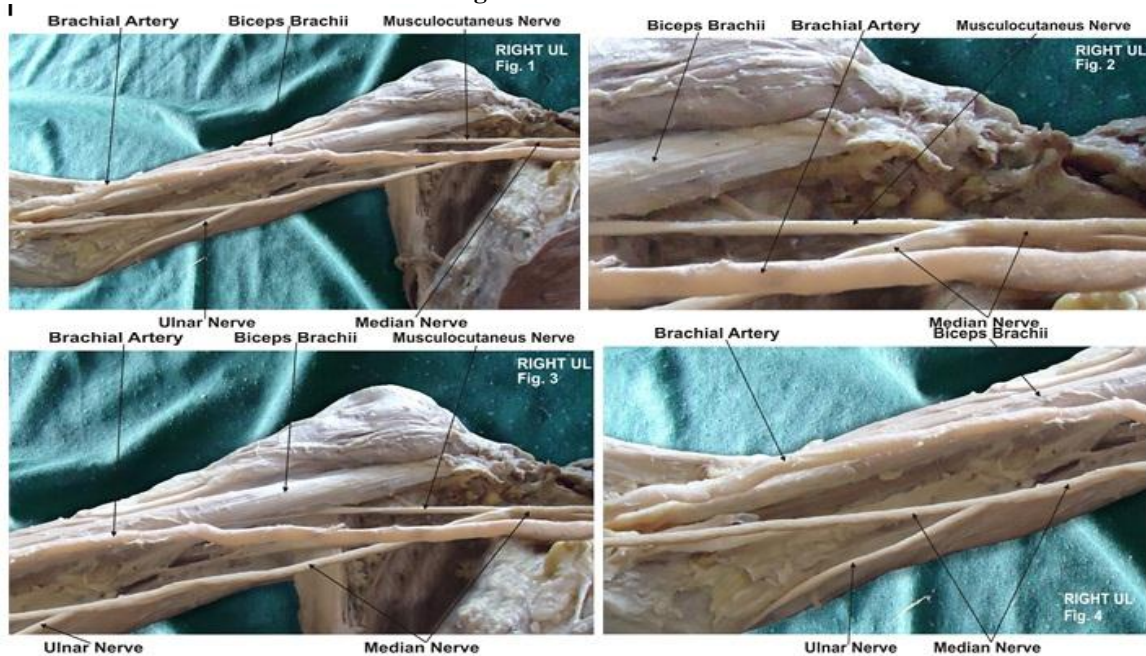
According to the standard textbooks of Anatomy, in the lower axilla, the cords of the brachial plexus divide into the nerves of the upper limb. The ulnar nerve arises as a branch of the medial cord, but it often receives fibres from the lateral root of the median nerve. On the other hand, the median nerve is formed by the union of the lateral and the medial roots of the median nerve, arising from the lateral and the medial cords of the brachial plexus respectively.

CASE REPORT

During routine under graduate dissections in the left, upper limb of a 60 year old male, the medial cord was

found to be formed normally by the fusion of the anterior divisions of C8 and T1. After its formation, instead of dividing into the medial root of the median nerve and the ulnar nerve, it bifurcated into the medial root of the median nerve and the medial cutaneous nerve of the forearm. The medial root of the median nerve fused with the lateral root of the median nerve (from the lateral cord) to form median nerve. After a course of 4 cm, the median nerve bifurcated into the median nerve proper and the ulnar nerve. The rest of the course and the branches of the median nerve and the ulnar nerve were normal. No other muscular or neurovascular anomaly was seen in this limb. The contralateral limb showed no anomaly.

Figure 1. Observation



- LC : LATERAL CORD OF BRACHIAL PLEXUS
- MC : MEDIAL CORD OF BRACHIAL PLEXUS
- LR : LATERAL ROOT OF MEDIAN NERVE
- MR : MEDIAL ROOT OF MEDIAN NERVE
- MN : MEDIAN NERVE
- MCN : MUSCULOCUTANEOUS NERVE
- CBM : CORACOBRACHIALIS MUSCLE
- BBM : BICEPS BRACHII MUSCLE
- BM : BRACHIALIS MUSCLE
- UN : ULNAR NERVE

DISCUSSION

Many variation patterns of the branches of the brachial plexus have been described earlier. These include the communication between the median nerve and the musculocutaneous nerve [4]; the absence of the posterior cord, merging of all the cords to form a single cord [5]; the ulnar nerve arising from the posterior cord [6]; and the communication between the median and the ulnar nerves [7,8]. An anomalous median-to-ulnar forearm communication, which is known as the Martin-Gruber anastomosis, has been well reported in the literature, while the Marinacci communication, the reverse of the Martin-Gruber anastomosis, with a forearm ulnar-to-median communication, has been under-recognized [9].

However, none of the authors have commented upon a variation where the whole of the ulnar nerve arose from the median nerve, as in the present case. Miller (1934) summarized the work which was done by earlier authors on the brachial plexus in amphibians, reptiles, birds, monotremes, dogs, primates in general and in anthropoid apes [9]. He observed that in animals with poorly developed hand structures, the ulnar and the median nerves were undifferentiated and that a single nerve trunk supplied the region. This condition is especially marked in the wing of the bird. In reptiles, the two nerves are formed from the trunk, although at a distance, peripherally. The actual differentiation of the ulnar nerve is evident in the monotremes and marsupials, in which the forelimbs are better developed and have a greater range of action. Conversely, the nerves to the compressed forefeet of dogs are fused or anastomosed for a greater part of their extent. The differentiation of the separate ulnar and median nerves is more definite in higher animals with well-developed forelimbs. The pattern which was observed in the present case was similar to the patterns which were usually observed in lower animals like reptiles and dogs.

Clinical Significance:

The anomalies at the high humeral level of the brachial plexus may present as a complicating factor during a surgical attempt to cause a nerve blockade. At high humeral levels, the median nerve descends from the

axilla in close proximity to the brachial artery, frequently lying just lateral to the artery. Likewise, the ulnar nerve remains close to the artery to this point and is especially found just medial to the artery [10]. But in a case like ours, when the ulnar nerve originates at a distal level from the median nerve; an attempted ulnar nerve block at a proximal level may fail or an attempted median nerve blockade may result in an associated ulnar nerve blockade. An effective brachial plexus blockade requires a thorough understanding of the anatomy of the plexus, as well as an appreciation of the anatomical variations that may occur. Variant nerve communications may cause ineffective nerve blockade and also, the blockade of unexpected areas. During a surgical procedure, such variations may lead to possible complications. Therefore, it is very important to know all the variants of the brachial plexus for a successful regional nerve blockade and operations.

ACKNOWLEDGEMENT:

Authors are thankful to Dean Dr. Vinayak Sabnis Sir for his support and encouragement. Authors are also thankful to Mr. M. Murugan, Mrs. Pallavi Kadam, Mr. Shivaji Dalvi, Mr. Kishor Rangle, Mr. Sankush Adkhale, Mr. Sanjay Shinde, Mr. Kishor Baradiya and Mr. Panduj for their help. Authors also acknowledge the immense help received from the scholars whose articles are cited and included in references of this manuscript. The authors are also grateful to authors / editors / publishers of all those articles, journals and books from where the literature for this article has been reviewed and discussed.

CONFLICT OF INTEREST

The authors declare that they have no conflict of interest.

STATEMENT OF HUMAN AND ANIMAL RIGHTS

All procedures performed in human participants were in accordance with the ethical standards of the institutional research committee and with the 1964 Helsinki declaration and its later amendments or comparable ethical standards. This article does not contain any studies with animals performed by any of the authors.

REFERENCES

1. Neto EPS, Durand PG, Sassolas F, Vial C, Lehot JJ. (1998). Brachial plexus injury during cardiac catheterisation in children. *Acta Anaesthesiol Scand*, 42, 876-9.
2. Kroll DA, Caplan RA, Posner K, Ward RJ, Cheney FW. (1990). Nerve injury which is associated with anaesthesia. *Anesthesiology*, 73, 202-7.
3. Collins JD, Shaver ML, Disher AC, Miller TQ. (1995). Compromising abnormalities of the brachial plexus as displayed by magnetic resonance imaging. *Clin Anat*, 8, 1-16.
4. Li Minor JM. (1992). A rare variant of the median and the musculocutaneous nerves in man. *Arch Anat Histol Embryol*, 73, 33-42.
5. Pandey SK and Kumar S. (2004). Anomalous formation of the brachial plexus cords and the median nerve. In, Jethani SL, editor. *J Anat Soc Ind* 2004.

6. Goncalves J, Duparc F, Auquit- Auckbur I, Milliez PY. (2002). Constitutional anomalies of the terminal branches of the brachial plexus in the axial and the brachial regions. Results of 42 cases and review of literature. *Ann Chir Plast Esthet*, 47(1), 30-5.
7. Kazakos KJ, Smyrnis A, Xarchas KC, Dimitrakopoulou A, Verettas DA. (2005). Anastomosis between the median and the ulnar nerve in the forearm. An anatomical study and literature review. *Acta Orthop Belg*, 71, 29- 35.
8. Meenakshi-Sundaram S, Sundar B, Arunkumar MJ. Marinacci. (2003). Communication, an electrophysiological study. *Clin Neurophysiol Dec*, 114(12), 2334- 37.
9. Miller RA. (1934). Comparative studies on the morphology and the distribution of the brachial plexus. *Am J Anat*, 54(1), 143-66.
10. Stanescu S, Post J, Ebraheim NA, Bailey AS, Yeasting R. (1996). Surgical anatomy of the radial nerve in the arm, practical considerations of the branching patterns to the triceps brachii. *Orthopedics* 19, 311-15.

Cite this article:

Shriya Ravichandran, Sharadkumar P. Sawant, Shaheen Rizvi. An unusual origin of musculocutaneous and ulnar nerve from median nerve. *International Journal Of Advances In Case Reports*, 4(3), 2017, 104-107.

DOI: <http://dx.doi.org/10.21276/ijacr.2017.4.3.3>



Attribution-NonCommercial-NoDerivatives 4.0 International