



A CASE REPORT - DOUBLE PROFUNDA BRACHII ARTERY

Riya B. Vakil^{1*}, Sharadkumar P. Sawant², Shaheen Rizvi³

¹First MBBS, ²Professor and Head, ³Assistant Lecturer, Department of Anatomy, K. J. Somaiya Medical College, Somaiya Ayurvihar, Eastern Express Highway, Sion, Mumbai-400 022, Maharashtra, India.

ABSTRACT

During the routine dissection on a donated embalmed cadaver in the department of Anatomy at K. J. Somaiya Medical College, Sion, Mumbai, a double profunda brachii artery was found in a male cadaver of 65 years in the left upper limb. The profunda brachii artery - 1 was originating from the posteromedial aspect of the brachial artery, distal to teres major muscle. The profunda brachii artery - 2 was originating from the posterior circumflex humeral artery in quadrangular space around the surgical neck of the humerus. The profunda brachii artery - 2 divides into the anterior descending (Radial collateral) & the posterior descending (middle collateral) arteries. The profunda brachii artery - 1 gives nutrient artery to the humerus and runs with posterior descending (middle collateral) artery & ends by anastomosing with interosseous recurrent artery behind the lateral epicondyle. The presence of double profunda brachii arteries in the radial groove may result in excessive haemorrhage during fractures. Topographical anatomy of the normal and abnormal variations of the brachial artery is clinically important for surgeons, orthopaedicians and radiologists performing angiographic studies on the upper limb.

Key words: Profunda Brachii Artery, Brachial Artery, Posterior Circumflex Humeral Artery, Quadrangular Space, Fractures of Humerus, Angiographic Studies.

Access this article online

Home page:

<http://www.mcmed.us/journal/ijacr>

DOI:

<http://dx.doi.org/10.21276/ijacr.2017.4.3.2>

Quick Response code



Received:25.02.17

Revised:12.03.17

Accepted:25.03.17

INTRODUCTION

The triceps receives part of its blood supply from muscular branches arising directly from the brachial artery and from the superior ulnar collateral artery. The arteria profunda brachii (also known as deep artery of the arm and the deep brachial artery) provides muscular branches to the triceps before beginning its course around the humerus in company with the radial nerve. It continues to give off twigs to the muscle as it runs this spiral course. It may give off a nutrient artery to the humerus.

Deep to the long head of the triceps it regularly gives rise to a deltoid branch that ascends to anastomose

with the posterior humeral circumflex artery. This anastomoses accounts for the fact that the profunda brachii sometimes arises from the posterior humeral circumflex, or more rarely, the circumflex arises from the profunda [1].

The terminal branches of the profunda brachii artery are the radial and middle collateral arteries, both of which help to form the anastomoses around the elbow. The radial collateral artery follows the radial nerve through the lateral intermuscular septum and anastomoses in front of the elbow with the radial recurrent artery. The middle collateral artery descends on the triceps, disappears deep to the anconeus, and anastomoses behind the elbow with the interosseous recurrent artery [2].

The present case report describes rare anatomical variant i.e double profunda brachii arteries traversing the radial groove. The incidence of anatomical variations of

Corresponding Author

Riya B. Vakil

Department of Anatomy, K.J. Somaiya Medical College, Somaiya Ayurvihar, Eastern Express Highway, Sion, Mumbai-400 022, Maharashtra, India.

Email: vakilriya@gmail.com

upper limb arteries varies between 11-24% in normal population [3].

Considering the higher incidence of anatomical variations of arteries of the upper limb, prior anatomical knowledge of such anomalies may be of great clinical significance to vascular surgeons, orthopaedicians and radiologists performing angiographic studies.

Appreciation of variations in the upper limb vessels is important due to increasing number of procedures both diagnostic and therapeutic as in breast cancer surgery, flap harvesting and arteriography.

The arterial pattern of the upper limb is one of the systems that shows a large number of variations in the adult human body. However, embryological explanations for these variations have been subject to much debate. Recent studies have provided a new classification of the arterial variations in the upper limb, as well as a new model of arterial development based on the study of large

anatomical and embryological samples. In the present article, we offer a review of the embryological and morphological data obtained in adults.

Case Report

Exposure of the profunda brachii artery and its branches was achieved following classical incisions and dissection procedures on a donated cadaver in the department of Anatomy, K. J. Somaiya Medical College, Sion, Mumbai and all the branches of the profunda brachii artery was studied. During this case report, a double profunda brachii artery was found in one left upper limb. The profunda brachii artery - 1 was originating from the posteromedial aspect of the brachial artery, distal to teres major muscle & the profunda brachii artery - 2 was originating from the posterior circumflex humeral artery in the quadrangular space around the surgical neck of the humerus.

Figure 1. Showing photographic presentation of the profunda brachii artery - 1 originating from the posteromedial aspect of the brachial artery, distal to teres major muscle.

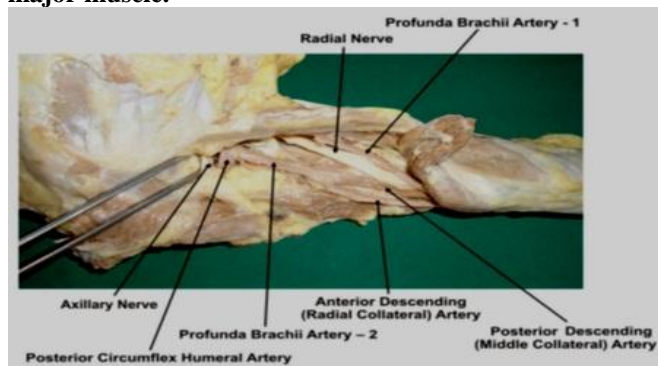
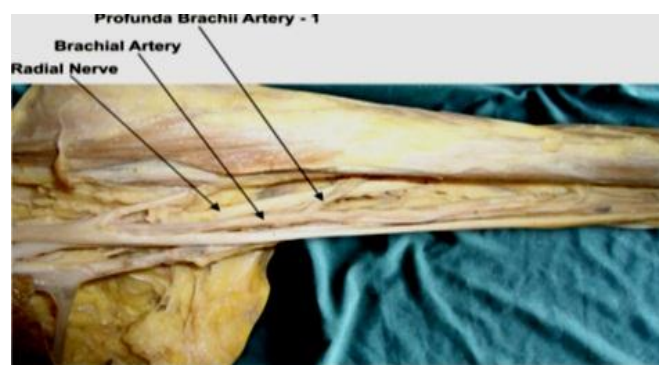

Figure 2. Showing photographic presentation of the profunda brachii artery - 2 originating from the posterior circumflex humeral artery.



DISCUSSION

The upper limb arteries develop in five stages. An axial arterial pattern represented in the adult by axillary artery, brachial artery and interosseus artery of the forearm develops first while other branches develop later from the axial system. In the later stages the median artery branches from the anterior interosseous artery and the ulnar artery branches from the brachial artery respectively. In the further course of development a superficial brachial artery arises from the axillary artery and it continues as radial artery. Regression of the median artery and an anastomosis between the brachial artery and superficial brachial artery with regression of the proximal segment of the latter gives rise to the definitive radial artery [2]

The anomalies can be explained by the persistence of embryological vessels. Genetic influences are deemed to be prevalent causes of such variation, although factors like fetal position in utero, first limb movement or unusual musculature cannot be excluded [7]. The profunda brachii, largest branch of the brachial, shows considerable

variations in its origin. In 55% of cases, it arises as a single trunk at the level of the tendon of teres major muscle. It may arise from the axillary artery (22%), as common trunk with the superior ulnar collateral artery in 22%, or as a branch of the posterior circumflex humeral artery (7%) [9]. The profunda brachii artery can originate from a common origin with the posterior circumflex humeral artery, from the axillary artery proximal to the tendon of latissimus dorsi or from the distal portion of the axillary artery [1].

The present case report describes rare anatomical variant i.e double profunda brachii arteries traversing the radial groove. The profunda brachii artery - 1 was originating from the posteromedial aspect of the brachial artery, distal to teres major muscle. The profunda brachii artery - 2 was originating from the posterior circumflex humeral artery in quadrangular space around the surgical neck of the humerus. The profunda brachii artery - 2 divides into the posterior descending (middle collateral) & the anterior descending (Radial collateral) arteries.

The profunda brachii artery - 1 runs with posterior descending (middle collateral) artery & ends by anastomosing with interosseous recurrent artery behind the lateral epicondyle. The anterior descending (Radial collateral) artery is the continuation of the profunda brachii artery. It accompanies the radial nerve through the lateral inter muscular septum descending between brachialis & brachioradialis anterior to the lateral epicondyle and ends by anastomosing with the radial recurrent artery. It supplies brachialis, brachioradialis, the radial nerve and few fascio cutaneous perforators.

Anatomical Importance:

As the profunda brachii artery arises from the 3rd part of the axillary artery in the quadrangular space, the contents of the space are: Axillary nerve, Posterior circumflex humeral artery and Profunda brachii artery. The contents of radial groove In the present case are the Radial nerve, Profunda brachii artery - 1 and Profunda brachii artery - 2

Surgical Importance:

The present paper describes a rare anomaly of the presence of double profunda brachii artery. In the present case, both arteries traversed the radial groove. In case of fractures involving the radial groove of the humerus both the profunda brachii arteries may be involved resulting in excessive haemorrhage. Middle collateral (posterior descending) artery & its fascio cutaneous perforators provide the anatomical basis to elbow skin flap (the lateral arm flap) which are surgically raised for reconstructing areas of tissue missing elsewhere in the body [5].

Clinical Significance

Knowledge of anomalous origin is important for surgeons who operate on patients of fracture in the mid-shaft region & surgical neck of humerus.

Embryological Basis:

Variations of the arterial pattern of the Upper Limb can be explained on the basis of the embryological development. Developmentally, the Upper Limb bud is initially supplied by a vascular plexus derived from 4 or 5 consecutive intersegmental branches of the dorsal aortae. Very early in the development, the 7th intersegmental artery forms the main artery (axis artery) of the developing Upper Limb bud. The axis artery gives rise to the subclavian, axillary, brachial and interosseous arteries. Other branches are added subsequently to the axis artery. First is the median artery. The ulnar and the radial arteries arise from the axis artery later. Because of this temporal succession of emergence of principle arteries, anomalies of forearm vasculature occur [4,6]. The arterial pattern of the

upper limb develops from an initial capillary plexus by a proximal and distal differentiation, due to maintenance, enlargement and differentiation of certain capillary vessels, and the regression of others.

The number of upper limb arterial variations arises through the persistence, enlargement and differentiation of parts of the initial network which would normally remain as capillaries or even regress [8]

CONCLUSION

The presence of double profunda brachii artery may be clinically important for clinicians, surgeons, orthopaedicians and radiologists performing angiographic studies. Undoubtedly, such variations are important for diagnostic evaluation and surgical management of vascular diseases and injuries. The knowledge of such variations is important; not only for surgeons but also for other medical and nursing staff because intravascular cannulation is commonly performed by them. Palpating for a superficial pulse over the cannulation site before such a procedure will probably minimize the risk of damaging an artery and subsequent bleeding. This also emphasizes the importance of preoperative arterial Doppler or angiography to correctly identify the regional anatomy of the vessels in certain procedures. Otherwise, the presence of the variations may be unexpectedly encountered during cases of vascularized forearm flap transfer or elective vascular surgery especially in the hand.

ACKNOWLEDGEMENT:

Authors are thankful to Dean Dr. Vinayak Sabnis Sir for his support and encouragement. Authors are also thankful to Mr. M. Murugan, Mrs. Pallavi Kadam, Mr. Shivaji Dalvi, Mr. Kishor Rangle, Mr. Shankush Adkhale, Mr. Sanjay Shinde, Mr. Kishor Beradiya and Mr. Panduj for their help. Authors also acknowledge the immense help received from the scholars whose articles are cited and included in references of this manuscript. The authors are also grateful to authors / editors / publishers of all those articles, journals and books from where the literature for this article has been reviewed and discussed.

CONFLICT OF INTEREST

The authors declare that they have no conflict of interest.

STATEMENT OF HUMAN AND ANIMAL RIGHTS

All procedures performed in human participants were in accordance with the ethical standards of the institutional research committee and with the 1964 Helsinki declaration and its later amendments or comparable ethical standards. This article does not contain any studies with animals performed by any of the authors.

REFERENCES

1. Standring S. (2005). *Gray's Anatomy*, 39th Ed, London: Elsevier Churchill Livingstone, pp 844-45, 856-57.
2. Last's Anatomy (2001) Regional and applied. 10th Ed. New York, Churchill Livingston, pp 48-55.
3. Durgun B, Yucel AH, Kizilkanat ED & Dere F. (2002). Multiple arterial variation of the human upper limb. *Surg. Radiol. Anat.*, 24, 125-8.
4. Hamilton WJ & Mossman HW. (1978). *Cardiovascular System. In. Human Embryology*. 4th Ed. Baltimore, Williams & Wilkins, pp 268-72
5. Jurjus A, Sfeir R & Bezirdjian R. (1986). Unusual variation of the arterial pattern the human upper limb. *Anat. Rec*, 215, 82-3.
6. Moore KL & Persand TVN. (2003). The Cardio vascular system.:*In the developing Human, Clinically oriented embryology*, 7th Ed. Elsevier, India, pp 329-80
7. Rodriguez-Niedenfuhr M, Vazquez T, Parkin IG & Sanudo JR. (2003). Arterial patterns of the human upper limb: update of anatomical variations and embryological development. *Eur. J. Anat*, 1, 21-8.
8. Singer E. (1933). Embryological pattern persisting in the arteries of the arm. *Anat Rec*, 55, 403-09.
9. Tountas CP & Bergman RA. (1993). *Anatomic variations of the upper extremities*. New York, Churchill Livingstone, pp 197-210.

Cite this article:

Riya B. Vakil, Sharadkumar P. Sawant, Shaheen Rizvi. A case report - double profunda brachii artery. *International Journal Of Advances In Case Reports*, 4(3), 2017, 100-103. DOI: <http://dx.doi.org/10.21276/ijacr.2017.4.3.2>



Attribution-NonCommercial-NoDerivatives 4.0 International