



A RARE CASE OF SPONTANEOUS ANTERIOR MEDIASTINAL BLEEDING IN PATIENT ON CHRONIC HEMODIALYSIS

Pradeep M. Venkategowda*, Naveen M Nayak, Radha M Guruprasad, Anand Sutar

Department of Critical Care Medicine, Apollo Hospital, Sheshadripuram, Bengaluru – 560020, India.

ABSTRACT

Bleeding tendencies are known to occur in patients with end stage renal disease. Spontaneous mediastinal bleed (SMB) in patient on chronic hemodialysis (DH) is a rare entity. This is a case report of 54 years old female known case of HTN, Hypothyroidism and CKD on maintenance hemodialysis. Patient developed sudden onset of breathlessness during maintenance HD. On further evaluation found to have mediastinal widening on chest X-ray (CXR) and anterior mediastinal fluid collection with evidence of contrast leak within the fluid collection on Contrast enhanced computed tomography (CECT) scan. She was diagnosed to be having spontaneous anterior mediastinal bleed secondary to CKD. Patient was managed conservatively in medical ICU with platelet transfusion, positive pressure ventilation and hemodialysis. Repeat CECT chest showed findings of decrease in mediastinal swelling. Patient was later discharged home successfully. This case report mainly highlights about a rare case of SMB in patient on chronic HD.

Key words: Spontaneous, Mediastinal, Bleeding, Hemodialysis.

Access this article online

Home page:

<http://www.mcmed.us/journal/ijacr>

DOI:

<http://dx.doi.org/10.21276/ijacr.2017.4.2.10>

Quick Response code



Received:07.03.17

Revised:12.03.17

Accepted:20.03.17

INTRODUCTION

Large mediastinal bleeding is a life threatening emergency. Numerous causes have been identified such as trauma to the thorax [1], malignancies (thymic and myelodysplasia) [2], infection (acute mediastinitis, oropharyngeal, cervical and neck infection), dissection or aneurysm of the thoracic vessels, invasive procedures [3], esophageal perforation, oral anticoagulation [4], Boerhaave syndrome and iatrogenic causes. Spontaneous mediastinal bleeding can occur in patients who have bleeding diathesis anywhere in the body. Patients who are known case of chronic kidney disease on maintenance HD with history of breathlessness usually have volume overload and pulmonary edema. Spontaneous mediastinal bleed though

rare can be a rare cause of breathlessness in these patients.

CASE REPORT

A 54 years old female, known case of HTN, CKD on maintenance hemodialysis (thrice weekly) and Hypothyroidism on treatment came to our hospital for maintenance hemodialysis. During HD in dialysis room she developed sudden onset of chest pain and shortness of breath. On auscultation of chest showed bilateral basal crepts and ECG showing nonspecific St-T changes with high blood pressure. Suspected of acute cardiac event patient was immediately shifted to MICU for further management.

On evaluation patient found to be conscious and coherent. Pulse rate 80 beats per minute, blood pressure 200/100 mm of Hg, afebrile, respiratory rate of 22 per minute and spo2 97% on room air. On auscultation bilateral basal crepts were heard. Blood investigation

Corresponding Author

Pradeep M Venkategowda

Department of Critical Care Medicine, Apollo Hospital, Sheshadripuram, Bengaluru – 560020, India.

Email: drpradeepmarur@gmail.com

revealed hemoglobin of 8.2gm/dl, total leucocyte count 8100 cells/cumm, platelet 110000 cells/cumm, LFT and serum electrolytes were normal, s. creatinine was 4.2 mg/dl. 2D echo showed no regional wall motion abnormality, normal LV and RV function with minimal pericardial effusion next to LV and RA. CXR (AP VIEW) revealed mild mediastinal widening (Figure-1). CT scan chest was having anterior mediastinal fluid collection with evidence of contrast leak within the fluid collection and pericardial effusion (figure-2).

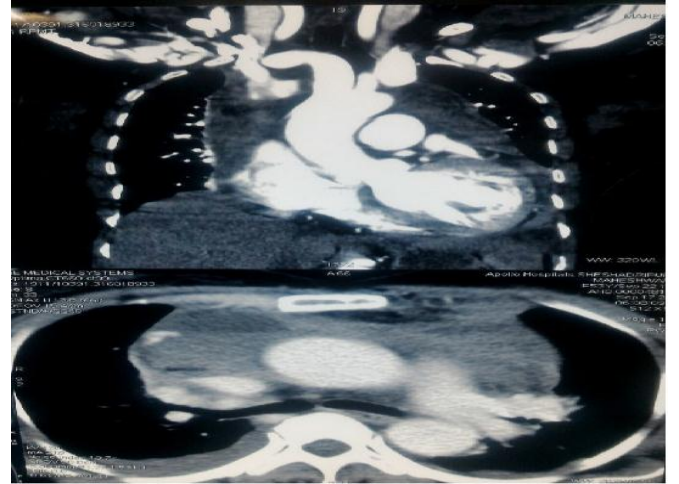
She was diagnosed to be having accelerated hypertension with spontaneous anterior mediastinal bleed secondary to CKD. Initially in MICU patient was managed with BIPAP support and

hemodialysis. Blood pressure was optimized with nitroglycerine infusion along with oral antihypertensive. Patient received one unit of single donor platelet (due to functional platelet dysfunction). The anterior mediastinal fluid collection was managed conservatively. On third day she was intubated in view of severe breathlessness and mechanically ventilated. Repeat CT chest with contrast showed similar findings without any increase in mediastinal swelling. Patient received another 4 sessions of hemodialysis during MICU stay. On 7th day she was extubated over BIPAP. On 10th day patient was shifted to ward in hemodynamically stable condition and later discharged home.

Fig 1. CXR showing mild mediastinal widening.

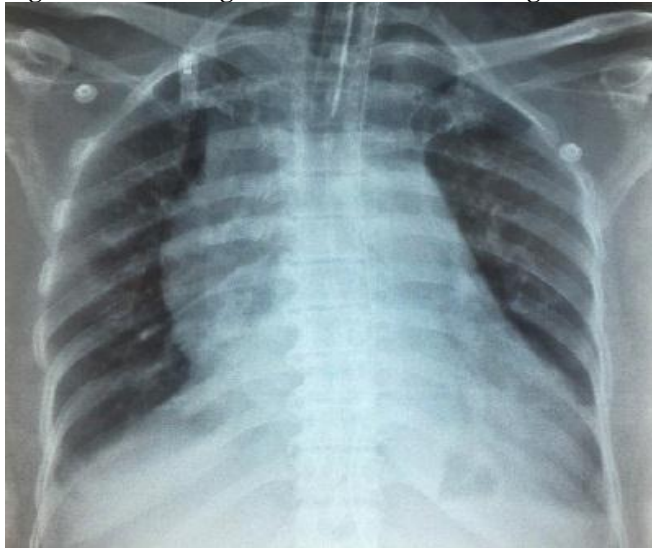

Fig 2. CT scan chest showing anterior mediastinal fluid collection with evidence of contrast leak within the fluid collection and pericardial effusion.



DISCUSSION

Chronic kidney disease (CKD) can lead to a complex haemostatic disorder such as bleeding diathesis or thrombotic complications. The pathogenesis of uremia related bleeding is multifactorial secondary to platelet related issues such as structural and functional defects, decreased production or increased consumption, decrease in mean platelet volume and defect in activation. Bleeding can also be seen secondary to anticoagulants used during dialysis or interaction between dialysis membrane and blood component. Thrombosis in CKD is due to increased platelet aggregation, elevated fibrinogen, factor 8 and vWF levels with decrease protein C and S levels.

The bleeding diathesis rate is around 10-15% and bleeding associated morbidity is about 15% [5]. Bleeding can be seen in the form of petechiae, purpura or massive vital organ bleeding (intra cerebral hemorrhage, subdural hematoma, retroperitoneal hemorrhage, retropharyngeal hemorrhage, hepatic subcapsular hematoma, intra ocular hemorrhage and cardiac tamponade). Arteriovenous fistula

site and dialysis catheter insertion sites are the other sites for bleeding [6,7]. Our patient hadspontaneous anterior

mediastinal bleed.

Differential diagnoses for mediastinal bleed are thoracic vessel rupture, aneurysm or dissection, thoracic trauma, valsalvamanoeuvre, hypertension, bleeding disorder, vertebral fracture, iatrogenic or spontaneous. Clinical suspicion about spontaneous mediastinal bleed should be kept in mind in patient having sudden onset of breathlessness, neck swelling, bruising over neck and chest and mediastinal widening on the chest X-ray. Diagnosis is mainly based on clinical signs and symptoms with supportive radiological tests such as CXR, angiography, contrast enhanced CT chest or MRI showing mediastinal bleed.

Management is usually conservative in majority of the patients. Daily close observation of any worsening in the clinical symptoms or increase in the hematoma size. Sometimes patient may require transfusion of packed RBC's, fresh frozen plasma, platelets, cryoprecipitate,

desmopressin [8], conjugated estrogen and erythropoietin. Other supportive treatment include removal of uremic toxins by daily and long term dialysis [Hedges 2007], heparin free hemodialysis in the form of low dose heparin, regional protamine or citrate heparinisation or intermittent saline flush [9]. Our patient received one unit of single donor platelet in view of suspected functional platelet dysfunction and four sessions of heparin free HD during hospital stay. In case of worsening of hematoma, operational intervention or angiography with embolisation may be required. This case report mainly highlights about a rare cause of spontaneous mediastinal hematoma in patient with CKD on maintenance hemodialysis. Early diagnosis and supportive management can reduce morbidity and mortality.

REFERENCES

1. Josse JM, Ameer A, Alzaid S, Arrowaili A, Decklebaum DL, et al. (2012). Posterior Mediastinal Hematoma after a fall from Standing Height: A Case Report. *Case Rep Surg*, 672370.
2. Handa SP and Colwell B. (1993). Spontaneous retropharyngeal bleeding in a Patient on Chronic Hemodialysis. *Nephron*, 64, 485-6.
3. Hohlrieder M, Oberhammer R, Lorenz IH, Margreiter J, Kuhbacher G, Keller C. (2004). Life-threatening mediastinal hematoma caused by extravascular infusion through a triple-lumen central venous catheter. *AnesthAnalg*, 99, 31-35.
4. Deepak V, Himani L, Gul M, Anupal D, Noor M. (2015). Spontaneous atraumatic posterior mediastinal hemorrhage: A rare case report and review of literature. *Ann OtolaryngolRhinol*, 2, 1048.
5. Davenport A, Will EJ, Davison AM. (1994). Comparison of the use of standard heparin and prostacyclin anticoagulation in spontaneous and pump-driven extracorporeal circuits in patients with combined acute renal and hepatic failure. *Nephron*, 66, 431-7.
6. Galbusera M, Remuzzi G, Boccardo P. (2009). Treatment of bleeding in dialysis patients. *Semin Dial*, 22, 279-86.
7. Remuzzi G. (1989). Bleeding disorders in uremia: pathophysiology and treatment. *AdvNephrol Necker Hosp*, 18, 171-86.
8. Prowse CV, Sas G, Gader AM, Cort JH, Cash JD. (1979). Specificity in the factor VIII response to vasopressin infusion in man. *Br J Haematol*, 41, 3, 437-47.
9. Nagarik AP, Soni SS, Adikey GK, Raman A. (2010) Comparative study of anti-coagulation versus saline flushes in continuous renal replacement therapy. *Saudi J Kidney Dis Transpl*, 21, 3, 478-83.

Cite this article:

Pradeep M. Venkategowda, Naveen M Nayak, Radha M Guruprasad, Anand Sutar. A Rare Case Of Spontaneous Anterior Mediastinal Bleeding In Patient On Chronic Hemodialysis. *International Journal Of Advances In Case Reports*, 4(2), 2017, 90-92. DOI: <http://dx.doi.org/10.21276/ijacr.2017.4.2.10>

ACKNOWLEDGEMENTS

We acknowledge management of the hospital for their valuable support.

CONFLICT OF INTEREST

The authors declare that they have no conflict of interest.

STATEMENT OF HUMAN AND ANIMAL RIGHTS

All procedures performed in human participants were in accordance with the ethical standards of the institutional research committee and with the 1964 Helsinki declaration and its later amendments or comparable ethical standards. This article does not contain any studies with animals performed by any of the authors.



[Attribution-NonCommercial-NoDerivatives 4.0 International](https://creativecommons.org/licenses/by-nc-nd/4.0/)