



TWO DIFFERENT ARRHYTHMOGENIC SYNCOPE IN A FAMILY; SHORT QT SYNDROME IN DAUGHTER AND COMPLETE ATRIO-VENTRICULAR BLOCK IN MOTHER


Ibrahim Etem Dural, Volkan Emren*, Zafer Yalim, Ersel Onrat

Afyon Kocatepe University, Faculty of Medicine Cardiology Department, Afyonkarahisar, Turkey.

ABSTRACT

In this case report we present two different arrhythmogenic syncope in a Family (mother and daughter). Mother admitted to our clinic with syncope associated with complete atrioventricular block treated with permanent cardiac pacemaker. In her family history her daughter also had syncope attacks due to short QT syndrome with polymorphic ventricular tachycardia treated with intracardiac cardio verterde fibrilator and pharmacologically. This is the first case report which describes complete AV block and short QT syndrome in first degree relatives. These arrhythmic disorders might have occurred genetically or co-incidentally.

Key words: Atrioventricular block, Short QT syndrome, Syncope.

Access this article online		
Home page: http://www.mcmed.us/journal/ijacr	Quick Response code 	
DOI: http://dx.doi.org/10.21276/ijacr.2017.4.2.7		
Received: 20.02.17	Revised: 01.03.17	Accepted: 07.03.17

INTRODUCTION

Syncope has many cardiovascular causes which were associated with arrhythmic disorders or structural cardiac diseases. Arrhythmic syncopes can result from both bradyarrhythmia and tachyarrhythmia.

Complete atrioventricular (AV) block causes syncope due to bradyarrhythmia, whereas short QT syndrome causes syncope due to tachyarrhythmia. There are some different issues in both diseases. For example complete AV block is seen more frequently, occurs especially in older age and result from non-genetic reasons. However short QT syndrome is seen in younger age, rarely seen and usually result from

genetic causes. Besides, short QT syndrome can lead to sudden cardiac death, however it is rarely seen in complete AV block [1,2].

In this family, we present an old woman and her daughter with a complaint of syncope which is associated with complete AV block in mother and it is associated with short QT syndrome in daughter. According to our knowledge this is the first case report which describes complete AV block and short QT syndrome in first degree relatives This condition may be co-incident or may be genetic originated.

CASE

Sixty-nine years old woman was admitted to cardiology department with a complaint of syncope. Complete AV block was determined in electrocardiogram (ECG) (Figure 1a). We did not detect any myocardial ischemia, electrolyte imbalance and drug toxicities that can cause complete AV block.

Corresponding Author

Volkan Emren

Afyon Kocatepe University, Faculty of Medicine Cardiology Department, Afyonkarahisar, Turkey.

Email: vemren@hotmail.com

There were no structural cardiac abnormalities in transthoracic echocardiographic examination. not detected any other arrhythmic disease such as Brugada syndrome, long QT syndrome or short QT syndrome. She was planned to implant cardiac pacemaker. In her family history her daughter also had syncope attacks. Her daughter was also evaluated and found short QT interval with 350 msc by correcting QT interval (with Bazzet formula) (Figure 1b). She underwent 24 hours holter electrocardiogram recording which revealed polymorphic ventricular tachycardia (Figure 2). Electrocardiographic recordings didn't revealed any arrhythmic abnormalities such as Brugada syndrome etc. In her background, she had no medication and cardiac diseases that lead to arrhythmia. Acidosis and electrolyte imbalance were not found in laboratory examination. QT interval was measured during sleeping in order to rule out deceleration-dependent shortening QT which decreases QT shortening. QT interval was not changed. In their family history, no

Mother's syncope was due to complete AV block and one had presyncope, syncope attacks and sudden death history. Echocardiography revealed no structural cardiac diseases.

Pacemaker was implanted to the mother and followed without giving any medication. Moreover implantable cardioverter defibrillator (ICD) was implanted to the daughter to prevent her from sudden death due to short QT syndrome and polymorphic ventricular tachycardia. We prescribed sotalol 2 X 80 mg to the daughter to increase QT interval and avoid ventricular arrhythmia. Following six months, daughter's corrected QT interval became 380 ms, in this period she did not have any syncope attacks. There were no ventricular arrhythmias in 24 hours electrocardiographic recordings. Three months later, sotalol increased the QT interval, controlled ventricular arrhythmias and syncope did not occur during this period.

Fig 1. Mother's electrocardiogram showed completatriyoventricular block

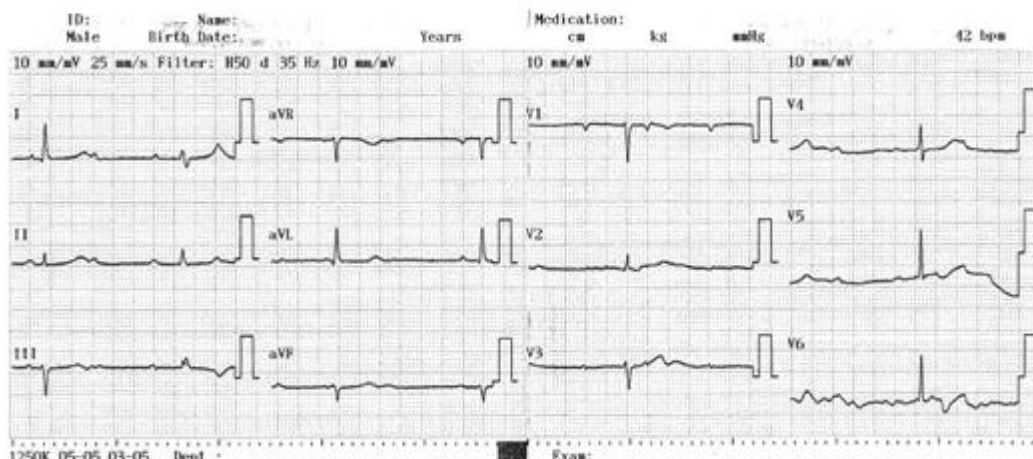


Fig 2. Sister's electrocardiogram revealed short QT interval with 350 msc by correcting QT interval with Bazzet formula.

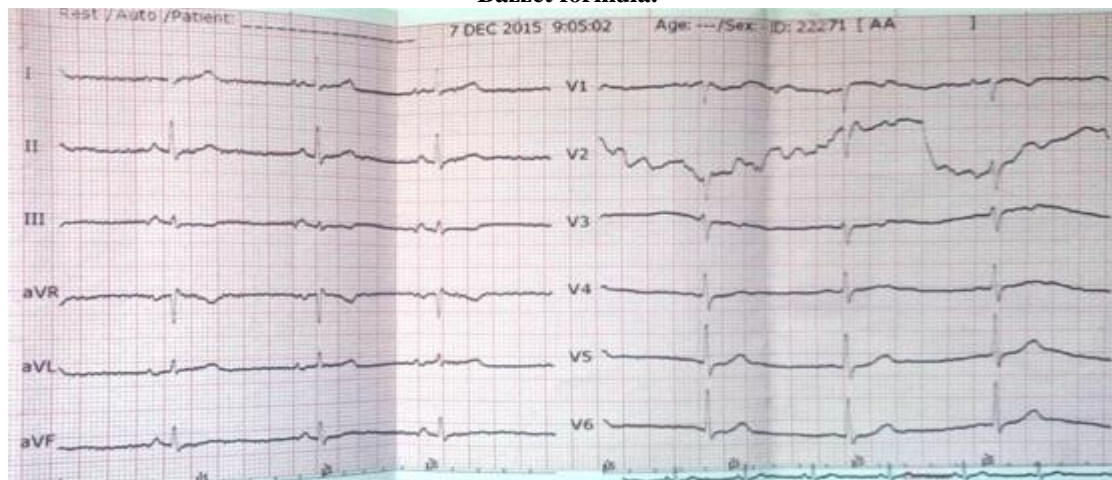
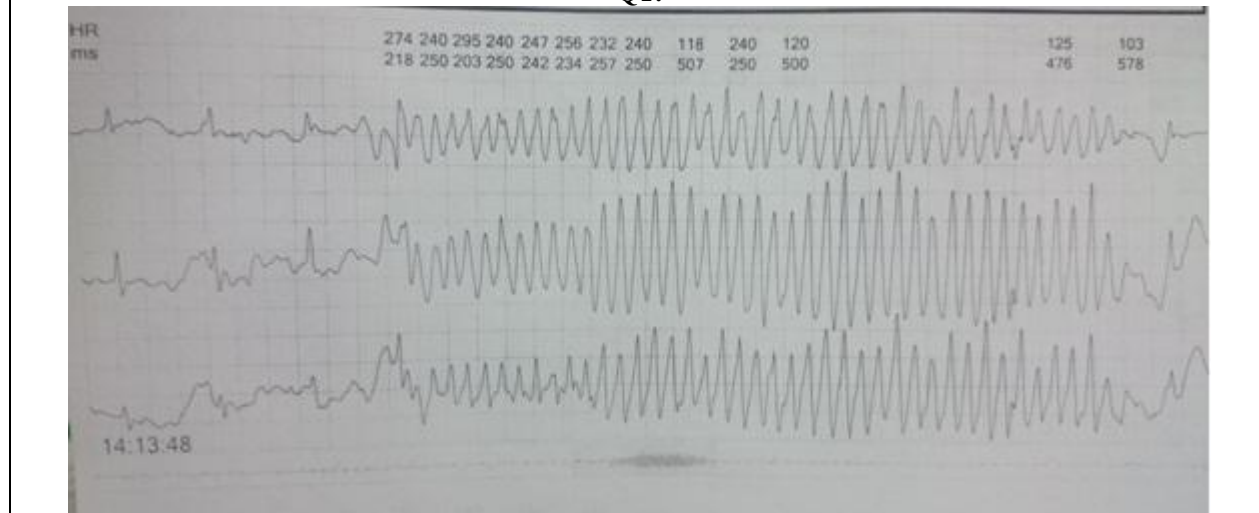


Fig 3. Sister's 24 hour holter electrocardiogram detected polymorphic ventricular tachycardia due to short QT.



DISCUSSION

Syncopes, in which the etiologic factors are not associated with each other (complete AV block and short QT syndrome) in family members, are very rare conditions. In this family, one syncope is due to bradyarrhythmia the other one is due to tachyarrhythmia. Complete AV block in mother and short QT syndrome in daughter may be co-incident or both of them may be associated with some genetic conditions that has not been known yet.

Short QT syndrome is an inherited disease in which QT interval shorter than 350 msc in men and 360 msc in women. Short QT syndrome leads to ventricular arrhythmia such as polymorphic ventricular tachycardia and ventricular fibrillation [2,3]. In this case we detected both polymorphic ventricular tachycardia and syncope episodes from her medical history. The diagnosis of short QT syndrome is based on the evaluation of symptoms (presyncope, syncope and palpitation), family history and short QT in 12 lead electrocardiograms. In this cases the other causes of short QT interval should be excluded. When the QT interval is less than 360 msc (men) or 370 msc (women) without any symptoms and/or family history, short QT interval diagnosis is suspicious. Because QT interval with 370 msc can also be seen in healthy population. The electrophysiologic study can be helpful [4]. In this case, we detected the corrected QT interval less than 360 msc, polymorphic ventricular tachycardia in 24 hour electrocardiography recording and syncope attacks in patients history which were helpful for diagnosing short QT syndrome. For this reason we did not perform electrophysiologic study. Finally, we accepted this patient as a short QT syndrome and implanted ICD, prescribed sotalol to increase QT interval and to

prevent ventricular arrhythmia. We could not prescribe quinidine, because of unavailability of drug in our country.

It is known that, short QT syndrome is associated with mutations in genes, KCNH2, KCNJ2 and KCNQ1, which control potassium channels in myocardium. Genetic and phenotype pattern of short QT syndrome is very heterogeneous. Five different subtypes of short QT syndrome with 7 different mutations in 5 different genes were described. We could not evaluate genetic examinations in our patient [2-5].

It was known that, most of the complete AV blocks are not associated with genetic abnormality. On the other hand in recent years, a genetic polymorphism and a mutation were described in some of complete AV blocks. Nikulina et al shown that AG genotype of H55R polymorphism of the SCN5A gene was a genetic predictor of atrioventricular conduction disorders. Zhou et al shown that HCN4 mutation is associated with atrioventricular block [6, 7]. It has been known that some of short QT syndrome types are associated with SCN5A mutation. Nikulina also said that some of the complete AV block types are associated with SCN5A mutation. In this family both of these diseases may have genetic origin which can be part of SCN5A mutation or these disease occurred co-incidentally. In the future, our cases may shed light whether or not these arrhythmic disorders in these family members had genetic pattern.

CONCLUSION

This the first case report which describes short QT syndrome in a one member and complete AV block in another member in the first degree

relatives. Based on our current knowledge we don't know whether these arrhythmic disorders were associated with genetically or occurred co-incidentally. However our cases may shed light on future studies

CONFLICT OF INTEREST

The authors declare that they have no conflict of interest.

STATEMENT OF HUMAN AND ANIMAL RIGHTS

All procedures performed in human participants were in accordance with the ethical standards of the institutional research committee and with the 1964 Helsinki declaration and its later amendments or comparable ethical standards. This article does not contain any studies with animals performed by any of the authors.

REFERENCES

1. Moya A, Sutton R, Ammirati F, Blanc JJ, Brignole M, Dahm JB. (2009). Guidelines for the diagnosis and management of syncope. The Task Force for the Diagnosis and Management of Syncope of the European Society of Cardiology (ESC). *Eur Heart J*, 30, 2631–2671.
2. Perez Riera AR, Paixao AA, Barbosa-Barros R, Yanowitz FG, Baranchuk A, Dubner S, Palandri CAC. (2013). Congenital short QT syndrome: landmarks of the newest arrhythmogenic cardiac channelopathy. *Cardiol J.*, 20, 464-71.
3. Patel C, Yan GX, Antzelevitch C. (2010). Short QT syndrome: from bench to bedside. *CircArrhythmElectrophysiol*, 3, 401-8.
4. Gaita F, Giustetto C, Bianchi F, Schimpf R, Haissaguerre M, Calò L, Brugada R, Antzelevitch C, Borggrefe M, Wolpert C. (2004). Short QT syndrome: pharmacological treatment. *Journal of the American College of Cardiology*, 43, 1494–9.
5. Borggrefe M, Wolpert C, Antzelevitch C, Veltmann C, Giustetto C, Gaita F, Schimpf R. (2005). Short QT syndrome. Genotype-phenotype correlations. *J Electrocardiol.*, 38, 75-80.
6. Nikulina SY, Chernova AA, Shulman VA, Maksimov VN, Gavriluk OA, Tretyakova SS, Marilovceva OV. (2015). An investigation of the association of the H558R polymorphism of the SCN5A gene with idiopathic cardiac conduction disorders. *Genet Test Mol Biomarkers*, 19, 288-94.
7. Zhou J, Ding WG, Makiyama T, Miyamoto A, Matsumoto Y, Kimura H, Tarutani Y, Zhao J, Wu J, Zang WJ, Matsuura H, Horie M. (2014). A novel HCN4 mutation, G1097W, is associated with atrioventricular block. *Circ J.*, 78, 938-42.

Cite this article:

Ibrahim Etem Dural, Volkan Emren, Zafer Yalim, Ersel Onrat. Two different arrhythmogenic syncope in a family; short qt syndrome in daughter and complete atrio-ventricular block in mother. *International Journal Of Advances In Case Reports*, 2017;4(2):80-83.DOI: <http://dx.doi.org/10.21276/ijacr.2017.4.2.7>



[Attribution-NonCommercial-NoDerivatives 4.0 International](http://creativecommons.org/licenses/by-nc-nd/4.0/)