



BONE SCAN & BISPHOSPHONATES FOR PAGET'S DISEASE – A CASE REPORT WITH REVIEW OF LITERATURE

Saraswathi Gopal K¹ and Swathi T^{2*}

¹Prof & Head of department of Oral medicine and Radiology, ²PG student,
Meenakshi Ammal Dental College, Chennai, Tamilnadu, India.

Corresponding Author:- **Swathi T**
E-mail: swathi.march91@gmail.com

<p>Article Info Received 18/10/2016 Revised 27/10/2016 Accepted 30/10/2016</p> <p>Key words: Paget's disease, Maxilla, Skull, Bisphosphonates, Calcium, Vitamin D.</p>	<p>ABSTRACT Paget's disease is a disorder of bone resorption with compensatory increment in disorganized (woven bone) bone formation. It manifest as monostotic or polyostotic type. Paget's disease affects mainly the skull, femur, tibia and pelvic bones. Facial skeleton is involved in about 17% of the cases. We present a case of Paget's disease involving maxilla and treated using bisphosphonates and have narrated a detail review on the disease.</p>
--	--

INTRODUCTION

Paget's disease of bone (PDB) (osteitis deformans, leonine osteitis) was 1st described by Sir James Paget [1]. It is a disorder of bone resorption [2-5] with compensatory increment in disorganized (woven bone) bone formation. Manifest as monostotic or polyostotic type. Usually asymptomatic, significant symptoms including bone pain, deformity, secondary arthritis, and neurologic problems. Treatment with calcitonin [6] has been recently replaced by bisphosphonates [7]. We present a case of Paget disease treated with bisphosphonates.

CASE REPORT

A 55-year-old female patient reported to department of oral medicine & radiology with a complaint of increase in size of upper jaw and space between teeth for past 2 yrs. The progression is slow with no associated symptoms. Pt gave history of visiting dentist to replace her teeth following which lesion was identified on OPG and patient was referred to our institute. On review of systems, history of frequent headache with sudden onset, lasting for few hours was elicited.

On extraoral examination, a diffuse swelling was present in maxillary region extending from infraorbital region superiorly to line joining tragus and corner of mouth inferiorly. On palpation, consistency was firm, with local rise in temperature on comparing adjacent regions. Intraorally, entire maxillary alveolus was uniformly enlarged, mucosa covering the swelling appeared normal. On palpating the swelling was bony hard and non tender. No associated pain or bleeding from gums or mobility of teeth was present. (Fig. 1,2,3,4).

Orthopantomograph (Fig. 5) reveals altered trabecular pattern with loss of lamina dura in entire maxillary teeth bearing region with presence of diffuse radiolucency and multiple radiopaque masses resembling a cotton wool appearance. Further investigation with CT scan of head showed radiolucent and radiopaque, diffuse ground glass matrix with expansile lytic lesion involving maxilla, suggestive of pagets disease of maxilla and diffuse thickening of bilateral calvarial bone (Figs 6,7).

Laboratory investigations, as expected showed an increase in serum alkaline phosphatase level 242 U/L and



decreased Vitamin-D levels (19.2ng/ml) (Table: 1). Bone scan showed increased tracer concentration in skull, including mandible and rest of the skeletal system showed mild decreased in tracer concentration, suggestive of generalized osteoporosis and paget's disease involving skull bones (Fig 8). Correlating clinically and radiographically a diagnosis of Paget's disease of Skull was given.

Patient was then put on a course of vitamin D and calcium supplements to enhance her ability to face treatment with bisphosphonates, further NSAID (paracetamol) was prescribed for heachache. her The drug of choice for zoledronic acid (Bisphosphonates), 5mg intravenously single dose, which reduces ALP level by about 80% in 6 months (Reid 2005).

Fig. 1.



Fig. 2.

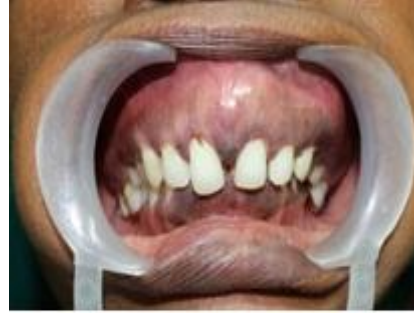

Fig: 3

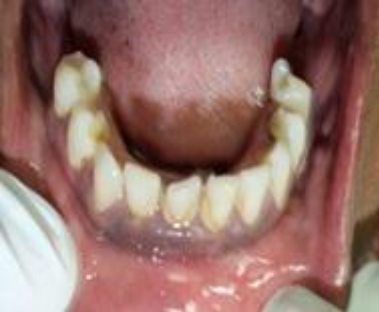

Fig. 4.

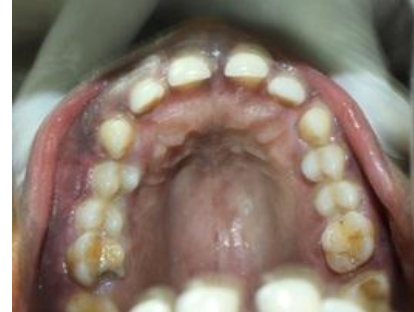

Fig. 5.

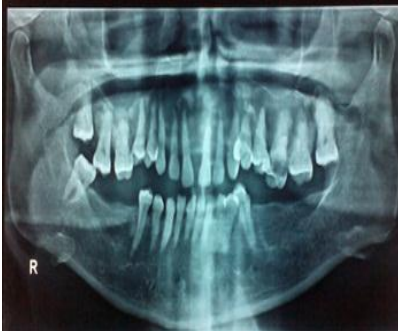

Fig. 6, 7. CT scan of head and neck

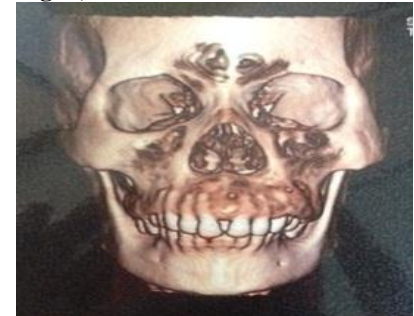

Fig. 7.

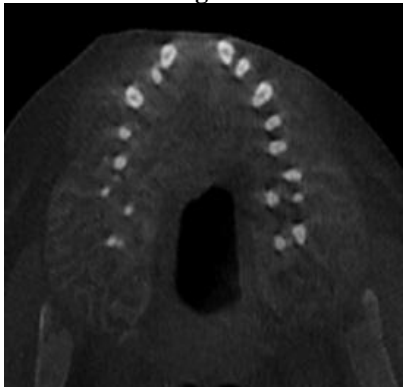
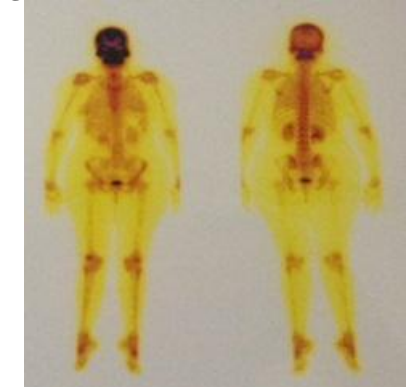
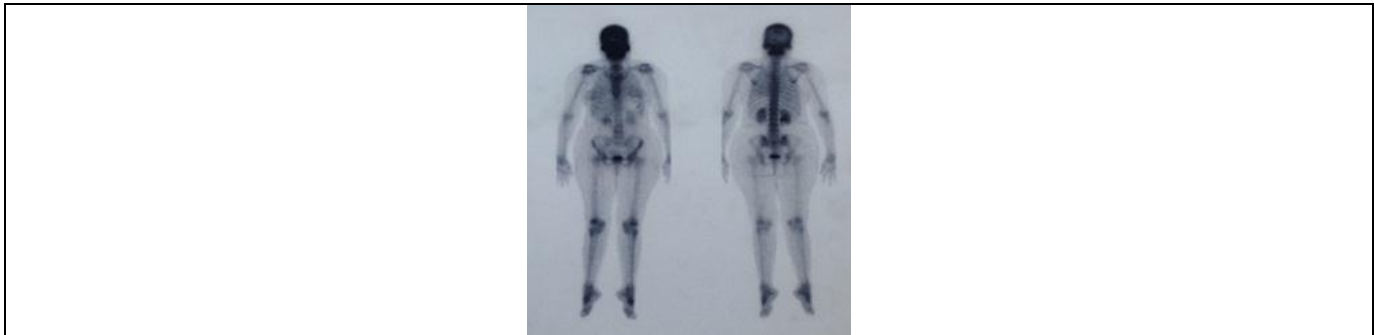
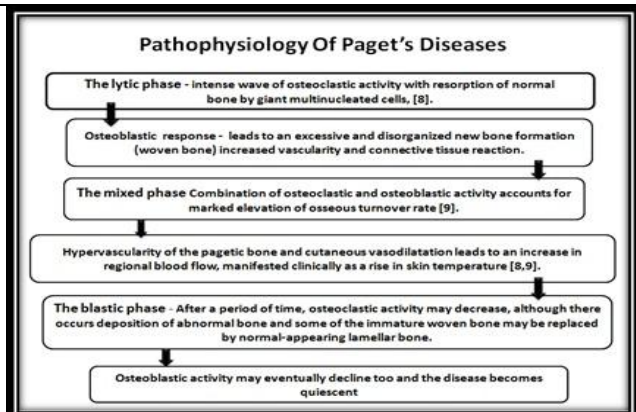


Fig. 8. Tc-99MDP whole body bone scan





Blood investigations	Values
Haemoglobin	11.2gms%
WBC count	7,600cells/mm ³ (4000-11000)
Platelet count	2.23lakhs (1.5-4.4)
Differential count	Normal
Glucose	Fasting (87mg/dl) / PP(134mg/dl)
Urine routine	Normal
Thyroid function test	Normal
Liver function test	Normal
GFR	120 mL/min
S calcium	9.6mgs/dl (8.7-11.0 mgs/dl)
S. phosphorous	4.0 mgs/dl (2.5-4.8 mgs/dl)
S. Alkaline phosphorous	242 IU/L (15 – 112 IU/L)
Vitamin D (25-OH)	19.2 ng/ml (30-100 ng/ml)



Major Clinical Features		
Skeletal	Neurological	Others
▪Pain	▪Cranial nerve palsies	▪Congestive heart failure
▪Deformity	▪deafness	▪Vascular steal syndrome
▪Fracture	▪Spinal stenosis	▪hypercalcemia
▪Secondary osteoarthritis	▪hydrocephalus	▪Valvular calcification
▪Dental complication		
▪Primary bone tumour		

Drug	Dose	Fall in ALP
Aledronate	40mg/day, orally, for 6 months	73-79% in 6 months
Risedronate	30mg/day, orally for 2 months	69% in 6 months
Pamidronate	60mg/day, for 3 days, Intravenously	53% In 6 months
Zoledronic acid	5mg, intravenously, single dose	80% in 6 months

Bisphosphonates - for antiresorptive treatment[2]

DISCUSSION

Precise cause of the disease is not fully defined yet; though genetic and environmental factors (animal contact) are found contributory. Viral infection is considered a strong etiology after identification of nuclear inclusion bodies in osteoclasts.

Pathologically, 3 phases are recognized: the lytic phase (incipient active), osteoclastic resorption predominates; the mixed phase (active), both osteoclastic and osteoblastic hyperplasia predominant; and, the blastic phase (late inactive), where osteoblastic activity declines. These 3 pagetic process—account for variable radiographic appearance. As a result of this anarchic bone behavior, disorganized new bone (mosaic) formation, modified external bone contour and marrow cavity are seen (Fig. 6).

Prevalence is 4.6%, higher in U K and rare in Scandinavia, Asia, Middle East, and Africa ^{9, 10}. Diagnosed incidentally with elevated Serum alkaline phosphatase (ALP) levels or radiographic abnormality, this stands in accordance to our patient. 95% of individuals are usually asymptomatic [10]. However, when skull is involved symptoms include bone enlargement, Frontal bossing, warmth of skin due increased vascularity, dilated scalp veins, headache¹¹, Cranial nerve deficits like Optic atrophy, ophthalmoplegia, trigeminal neuralgia, and facial palsy. Hearing loss occur in temporal bone involvement.

Malignant degeneration is about 0.2%, risk for osteosarcoma is greater [12] than fibrosarcomas, chondrosarcomas, and reticulosarcomas. hypercalcemia occurs due to immobilization for long period, due to



unbalanced bone resorption in absence of mechanical stimuli to bone formation.

The laboratory hallmark is increased serum ALP levels. Specific bone turnover markers, such as S. C-terminal telopeptide (CTX) and urinary N-terminal telopeptide (NTX), reflecting bone resorption, and aminoterminal propeptide of type 1 collagen (PINP), reflecting bone formation, can be used. But it is unfortunately not widely available in our country. Vitamin D and calcium has to be assessed, as both hypocalcemia and hypovitaminosis D have been implicated as associated features and triggers of PDB [13].

Plain film radiography is considered traditional. The lytic phase is exhibited on radiographs as osteolysis [14]. In long bones, osteolysis is seen as wedge-shaped radiolucency mimicking flame or blade of grass. Cortical thickening, enlargement of bone, ground-glass or “washed-out” pattern is seen in later stages of lytic phase. In skull, advancing osteolysis is seen as large areas of radiolucency crossing the suture lines in frontal and occipital bones and is designated as “osteoporosis circumscripta” [15]. The mixed phase bears lytic and blastic phase characteristics. It is notable for all 4 cardinal features; advancing osteolysis, coarsening and thickening of bone trabeculae along the lines of stress, cortical thickening, and osseous widening. In skull, characteristic cotton-wool appearance with globular to fluffy foci of variable density is seen. The blastic phase, osteosclerosis is manifested along with transverse fatigue fractures, which are referred as “banana fractures”. In skull, thickening of inner calvarium and enlargement of diploic space produces “tamo-shanter” skull (a tam-o’-shanter is a Scottish cap that is broad and flattened) [15].

CT scan provides superior cortical and trabecular detail in cross-sectional display, It exhibits all the classical findings in addition, is helpful in workup of suspected complications. In MRI, signals are variable similar to that of fat, reflecting natural course of disease process in different phases [14,16]. The pattern of signal intensity alteration, is referred as “speckled” appearance, and corresponds to presence of granulation tissue, hypervascularity, and edema when disorderly bone mineralization is present [15,17].

Bone scintigraphy is regarded as a sensitive examination for detection of increased blood flow and osteoblastic activity. Bone scans display markedly increased radionuclide uptake in the abnormal bone in all 3 phases [18]. In osteoporosis circumscripta, intense radionuclide uptake is confined to margins of lesion. Nonspecific tracer uptake has rendered scintigraphy a useful in revealing presence and distribution of polyostotic disease [14,18,19].

REFERENCES

1. Paget J. (1877) On a form of chronic inflammation of bone (osteitis deformans). *Medico-Chir Trans*, 60, 29-53.
2. Bruno Ferraz-de-Souza. (2013) Diagnosis and treatment of Paget’s disease of bone: a mini-review. *Arq Bras Endocrinol Metab*, 57(8), 577-82.

Histological landmark is mosaic pattern of irregular cement lines. The new bone is ivory-hard and heavier, because of their incapacity to form haversian systems. Differential diagnosis of fibrous dysplasia of bone and blastic bony metastases can be considered, the latter usually affects individuals under 40 years of age.

Antiresorptive therapy with symptom relief is the mainstay of treatment. Non-steroidal anti-inflammatory drugs (NSAIDS) are the drug of choice for pain relief. Bisphosphonates has been successful in reducing abnormal bone turnover [20,22]. They control disease and reduce pain which is effective for months or years²³. It is administered orally or intravenously, along with calcium and vitamin D supplements.

Bisphosphonates are contraindicated in glomerular filtration rate < 35 mL/min. It is crucial to ascertain calcium and vitamin D status prior to treatment²⁴, Hypocalcemia following bisphosphonate infusion is frequent in Paget’s diseases, contradictory to the above mentioned literature, in our patient hypovitaminosis D was observed. RANKL-inhibitor presently seems promising as an alternative antiresorptive agent [23,24].

CONCLUSION

Paget’s disease of bone is accompanied by accelerated bone resorption and formation in one or more bones resulting in skeletal lesions which can be osteolytic, mixed osteolytic/osteosclerotic, or osteosclerotic. This chronic progressive disorder of bone metabolism may go undetected for many years; until symptoms and complications like bone pain, deformity, fracture, neurological deficits, and, malignant transformation are manifested. It is thus important, that dentist are alerted to its clinical and radiographic signs to promptly recognize and diagnose paget’s disease before it reaches more advanced stages with irreversible complications; As most cases respond very well to treatment with bisphosphonates, thus preventing complications and deterioration in the quality of life.

ACKNOWLEDGEMENT: None

CONFLICT OF INTEREST:

The authors declare that they have no conflict of interest.

STATEMENT OF HUMAN AND ANIMAL RIGHTS

All procedures performed in human participants were in accordance with the ethical standards of the institutional research committee and with the 1964 Helsinki declaration and its later amendments or comparable ethical standards. This article does not contain any studies with animals performed by any of the authors.



3. Delmas PD, Meunier PJ. (1997) The management of Paget's disease of bone. *N Engl J Med*, 336(8), 558-66.
4. Ralston SH, Langston AL, Reid IR. (2008) Pathogenesis and management of Paget's disease of bone. *Lancet*, 372(9633), 155-63.
5. Ralston SH. (2013) Clinical practice. Paget's disease of bone. *N Engl J Med*, 368(7), 644-50.
6. Singer, F.R. (1977) Human calcitonin treatment of Paget's disease of bone. *Clin Orthop Rel Res*. 127, 86_93.
7. Silverman SL. (2008) Paget disease of bone: therapeutic options. *J Clin Rheumatol*. 14, 299_305.
8. Whyte MP. (2006) Clinical practice. Paget's disease of bone. *N Engl J Med*, 355, 593-596.
9. Rousiere M, Michou L, Cornelis F, Orcel P. (2003) Paget's disease of bone. *Best Pract Res Clin Rheumatol*. 17, 1019-1041.
10. Bone HG. (2006) Nonmalignant complications of Paget's disease. *J Bone Miner Res*, 21 Suppl 2, P64-8.
11. Rubin DJ, Levin RM. (2009) Neurologic complications of Paget disease of bone. *Endocr Pract*. 15(2), 158-66.
12. Joseph L. Shaker. (2009) Paget's disease of bone: a review of epidemiology, pathophysiology and management. *Therapeutic Advances in Musculoskeletal Disease*, 1(2), 107-125.
13. CG Ooi. (1997) Classic diseases revisited Paget's disease of bone. *Postgrad MedJ*, 73, 69-74
14. Daphne J. (2011) Imaging of Paget Disease of Bone and Its Musculoskeletal Complications: *Review*, AJR, 196.
15. Mirra JM, Brien EW, Tehranzadeh J. (1995) Paget's disease of bone: review with emphasis on radiologic features—part I. *Skeletal Radiol*, 24, 163-171.
16. Mirra JM, Brien EW, Tehranzadeh J. (1995) Paget's disease of bone: review with emphasis on radiologic features—part II. *Skeletal Radiol*, 24, 173-184.
17. Kelly JK, Denier JE, Wilner HI, Lazo A, Metes JJ. (1989) MR imaging of lytic changes in Paget disease of the calvarium. *J Comput Assist Tomogr*, 13, 27-29.
18. Love C, Din AS, Tomas MB, Kalapparambath TP, Palestro CJ. (2003) Radionuclide bone imaging: an illustrative review. *RadioGraphics*, 23, 341-358.
19. Assi Z, Bohnen N, Shulkin B. (1999) Paget disease of the thumb. *Clin Nucl Med*, 24, 613-614.
20. Siris E, Weinstein RS, Altman R, Conte JM, Favus M, Lombardi A, et al. (1996) Comparative study of alendronate versus etidronate for the treatment of Paget's disease of bone. *J Clin Endocrinol Metab*, 81(3), 961-7.
21. Reid IR, Nicholson GC, Weinstein RS, Hosking DJ, Cundy T, Kotowicz MA, et al. (1996) Biochemical and radiologic improvement in Paget's disease of bone treated with alendronate: a randomized, placebo-controlled trial. *Am J Med*. 101(4), 341-8.
22. Miller PD, Brown JP, Siris ES, Hoseyni MS, Axelrod DW, Bekker PJ. (1999) A randomized, double-blind comparison of risedronate and etidronate in the treatment of Paget's disease of bone. Paget's Risedronate/ Etidronate Study Group. *Am J Med*, 106(5), 513-20.
23. Walsh JP, Ward LC, Stewart GO, Will RK, Criddle RA, Prince RL, et al. (2004) A randomized clinical trial comparing oral alendronate and intravenous pamidronate for the treatment of Paget's disease of bone. *Bone*, 34(4), 747-54.
24. Reid IR, Miller P, Lyles K, Fraser W, Brown JP, Saidi Y, et al. (2005) Comparison of a single infusion of zoledronic acid with risedronate for Paget's disease. *N Engl J Med*, 353(9), 898-908.

