

A RARE CAUSE OF OBSTRUCTIVE JAUNDICE

Soumen Das¹, Sarbesh Gupta², S. Ganguly¹, Prakash Bhagat³, Makhan Lal Saha⁴

¹Assistant Professor, Department of Surgery, IPGME&R, SSKMH, Kolkata, India.

²Senior Resident, CNCI, Kolkata, India.

³RMO cum CT, Department of Surgery, IPGME &R, SSKMH, Kolkata, India.

⁴Professor, Department of Surgery, IPGME&R, SSKMH, Kolkata, India.

Corresponding Author: - **Soumen Das**

E-mail: soumendoc.das@gmail.com

Article Info

Received 26/06/2016

Revised 27/07/2016

Accepted 11/08/2016

Key words: Hydatid cyst liver, cystobiliary communication.

ABSTRACT

Hydatid cyst with cystobiliary communication causing obstructive jaundice is a rare but serious event. Here we present a patient 38 year old female who presented with pain in right upper abdomen, jaundice and fever with palpable liver. Ultrasound of abdomen showed hydatid cyst of left lobe of liver. CT scan of abdomen showed hydatid cyst in the left lobe of liver communicating with left hepatic duct. On ERCP hydatid membrane was seen protruding from papilla. Cholangiogram revealed large round cystic cavity in left lobe of liver communicating with left hepatic duct. Endoscopic stenting was done. Subsequent surgery was done with resection of segment II & III of liver containing the cyst cavity. Communication with left hepatic duct was overrun and T tube was placed. Postoperative course was uneventful.

INTRODUCTION

Obstructive jaundice results from intrinsic or extrinsic obstruction of biliary duct system that prevents the flow of bile into duodenum. There is a wide spectrum of pathologies that may present with obstructive jaundice. Common causes of obstruction of biliary tract being: stone disease, benign and malignant biliary strictures, cholangiocarcinoma, cholangitis, pancreatitis, pseudocyst, malignancies. Hydatid cyst with cystobiliary communication being a rare cause of obstructive jaundice. This complication should be included in the differential diagnosis of obstructive jaundice, especially in endemic areas. Here we present a patient 38 year old female who presented with pain in right upper abdomen, jaundice and fever with palpable liver. On investigation found to have hydatid cyst – left lobe of liver with cystobiliary communication.

CASE REPORT

A 38 year old female presented with pain in right upper abdomen, jaundice and fever. Patient was icteric with

palpable liver. Blood investigations: Hb-8.6gm%, TLC-14100/mm³, DLC- N85, L13, M1, E1, B0 Bilirubin - 4.2mg/dl (Direct - 2.4mg/dl), Albumin- 2.2gm/dl, ALP- 252U/l, ALT-14U/l, AST-32U/l, Echinococcus IgG was positive (13.36u/ml). Ultrasonography showed one irregular SOL (69x35mm) in left lobe of liver with multiple echogenic cysts inside SOL? Hydatid cyst (Fig 1). IHBR not dilated. CBD was 6.7mm in diameter with sludge (Fig 1). CT scan of upper abdomen showed a cyst (64x47x72mm), with thick enhancing walls and hyperdense areas within the left lobe of liver, communicating with the left hepatic duct at its inferolateral aspect (Fig 2). Left hepatic duct was 8mm in diameter. CBD was dilated 10 mm in diameter with thickened and enhancing walls. ERCP revealed membrane like material protruding from papilla (Fig 3). Endoscopic sphincterotomy was done, gush of pus with white membrane like material extruded through ampulla. Cholangiogram revealed large round cystic cavity in left lobe of liver and cyst communicating with left hepatic duct. Endoscopic stenting was done. The patient



underwent exploratory laparotomy with resection of segment II & III of liver containing the cyst cavity (Fig 4). Communication with left hepatic duct identified & overrun with mersilk. Choledochotomy, irrigation of CBD with T

tube drainage and cholecystectomy was done. Post operative T tube cholangiogram was normal. During follow up period recovery was uneventful and patient was kept on Tab. Albendazole.

Fig 1. Ultrasonographic view of the cyst

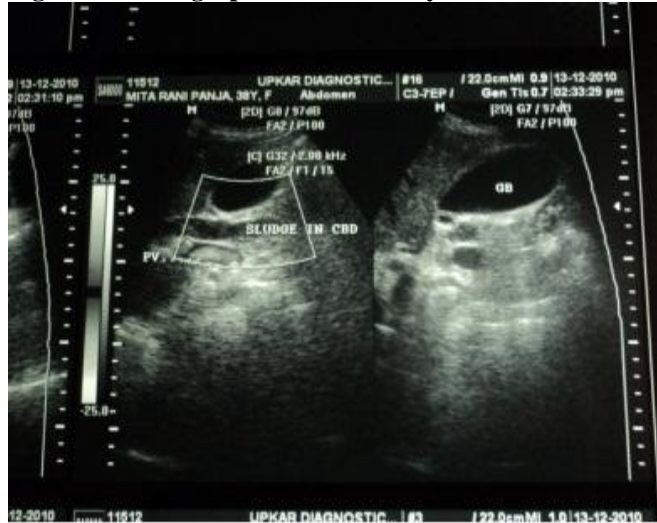

Fig 2. CT scan of upper abdomen showed a cyst (64x47x72mm), with thick enhancing walls and hyperdense areas within the left lobe of liver, communicating with the left hepatic duct at its inferolateral aspect

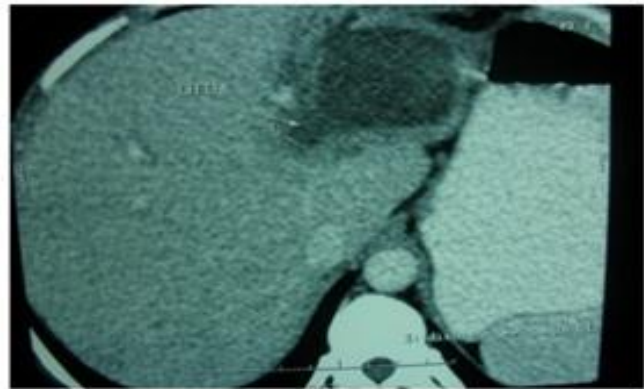


Fig 3. ERCP revealed membrane like material protruding from papilla

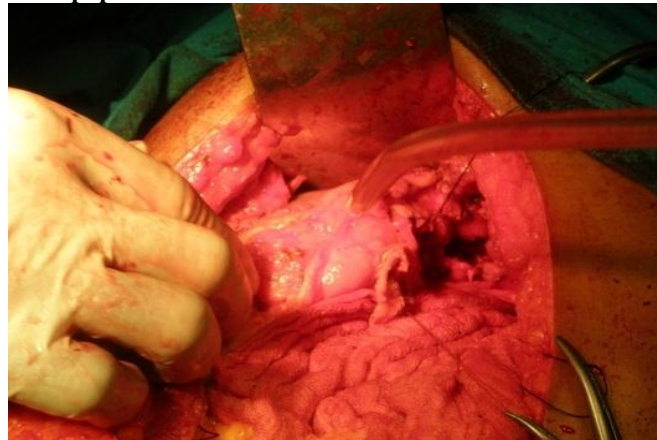
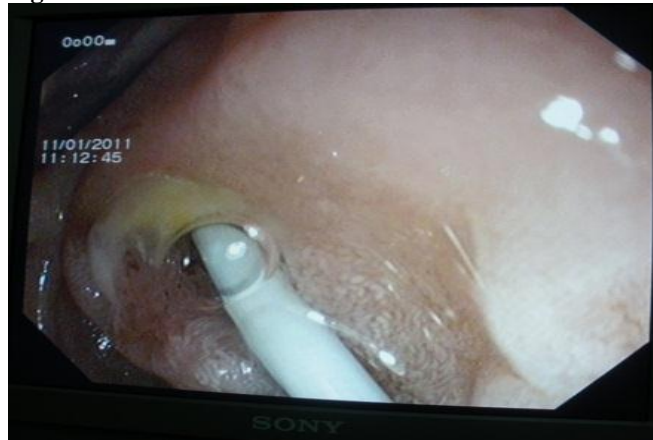
Fig 4. Intra-operative view showing cyst cavity in segment II & III of liver.



DISCUSSION

Hydatid disease is a parasitic zoonosis with humans being the intermediate host. *Echinococcus granulosus*, causing cystic hydatid disease, and *Echinococcus multilocularis*, causing alveolar hydatid disease infect humans by entering the gastrointestinal tract. Most commonly affected organs being liver (50% to 70%) and the lungs (10% to 15%). Hydatid cyst of liver may present with a number of complications. The complications may include compression, rupture, infection, or anaphylaxis. The most common complication of liver hydatid being rupture which can occur in any part of biliary system but the communication with the hepatic bile ducts is most common. Rupture in right hepatic duct occurs in 55-60% of cases while in the left duct in 25-30% of the cases

[1]. After rupture of hepatic hydatid biliary obstruction is reported to occur in 5-17% of the cases [2]. When the cystobiliary opening is larger than 5 mm, cystic content transfer into the biliary tract would occur in 65% of the cases [3]. Intrabiliary rupture leading to obstructive jaundice occurs in 57% to 100% of cases, especially when the rupture occurs into the large bile ducts thus emptying the contents into the biliary tract [4]. When hydatid cyst ruptures into the biliary tract, the cystic fluid escapes with daughter cysts and ruptured membranes into the common bile duct, causing biliary colic, obstructive jaundice, and possibly liver abscess. Delay in diagnosis and treatment of intrabiliary rupture apart from obstructive jaundice patient may also present with right upper abdominal pain (82%), fever (70-90%), acute cholangitis (20-37%), abdominal



lump (22-39%), and rarely with acute cholecystitis, acute pancreatitis, liver abscess or septicaemia; or in 5% to 6% it may be asymptomatic of liver hydatid may be associated with serious morbidity (19.44- 43.03%) and mortality (1.8-4.5%) [5, 6]. Hence early diagnosis and treatment is essential in such cases. Sepsis and hepatic failure are the major causes of mortality. Most commonly employed initial investigation is the ultrasound abdomen . Ultrasound defines internal structure, number and location of cyst. Frank cystobiliary communication is associated with the decrease in the size of the cyst and undulating membranes seen within it. Sludge and daughter cysts are suggested by echogenic or non-echogenic material without posterior acoustic shadowing in the biliary tree. CT abdomen can reveal detached undulating membranes and calcification of the cyst wall. Presence of hydatid sand and cysts in the CBD is suggested by dilated CBD with low attenuation intraluminal material inside. The site of communication may be identified as an interrupted area of the cyst wall proximal to a dilated duct. CT is useful in demonstrating high attenuation material passing through the defect of the cystic wall and filling up the intrahepatic biliaryradicles or CBD [7]. MRCP finding in ruptured hydatid cyst is considered useful in cases of intrabiliary rupture [8]. ERCP is considered to be the gold standard investigation to confirm the biliary tract involvement. ERCP may show a swollen ampulla of vater with hydatid material protruding out. Duct dilation with sludge and daughter cysts may appear as radiolucent filling defects. This condition can be differentiated from other causes of obstructive jaundice by demonstration of irregular leaf-like material that changes shape with changes in pressure. ERCP cannot always

exclude a small cystobiliary communication which can be actively sought during surgery. Preoperative use of albendazole or mebendazole helps in hydatid cyst surgery by reducing intracystic pressure and by reducing the risk of recurrence after surgery or endoscopic evacuation of a ruptured cyst into biliary tree. In liver hydatid surgery pericystectomy, evacuation and drainage or resection is required. Surgical procedures for large cystobiliary communication includes Roux-n-y cystojejunostomy, sutured fistula + tube drainage, sutured fistula + Omentoplasty, tube drainage + Omentoplasty, CBD drainage by a T-tube intubation. Morbidity and mortality can be reduced by accurate pre and intraoperative diagnosis and permanent drainage of the biliary tree by a wide choledochoduodenostomy [9] Transduodenal sphincterotomy or choledochoduodenostomy may be considered in cases with Oddi Stenosis [10].

CONCLUSION

Though liver hydatid with cystobiliary communication is a rare cause of obstructive jaundice, it can be a serious complication. Accurate pre- and intraoperative diagnosis is important to reduce morbidity and mortality. The mainstay of management is essentially surgical.

ACKNOWLEDGEMENT

Nil

CONFLICT OF INTEREST

No conflict of interest.

REFERENCES

1. Kumar A, Upadhyaya DN, Singh S, Kumar M, Ansari MA. (2004). Cholecysto-hydatid cyst fistula. *Indian J Gastroenterol*, 23(2), 76-77.
2. Akkiz H, Akinoglu A, Colakoglu S, Demiryurek H, Yagmur O. (1996). Endoscopic management of biliary hydatid disease. *Can J Surg*, 39(4), 287-292.
3. Zaouche A, Haouet K, Jouini M, El Hachaichi A, Dziri C. (2001). Management of liver hydatid cysts with a large biliocystic fistula: multicenter retrospective study. Tunisian Surgical Association. *World J Surg*, 25(1), 28-39.
4. Kumar R, Reddy SN, Thulkar S. (2002). Intrabiliary rupture of hydatid cyst: diagnosis with MRI and hepatobiliary isotope study. *Br J Radiol*, 75(891), 271-274.
5. Lewall DB and Nyak P. (1998). Hydatid cysts of the liver: two cautionary signs. *Br J Radiol*, 71(841), 37-41.
6. Erzurumlu K, Dervisoglu A, Polat C, Senyurek G, Yetim I, Hokelek M. (2005). Intrabiliary rupture: an algorithm in the treatment of controversial complication of hepatic hydatidosis. *World J Gastroenterol*, 11(16), 2472-2476.
7. Pedrosa I, Saiz A, Arrazola J, Ferreiros J, Pedrosa CS. (2000). Hydatid disease: radiologic and pathologic features and complications. *Radiographics*, 20(3), 795-817.
8. Mendez Montero JV, et al. (1996). Fat-fluid level in hepatic hydatid cysts: a new sign of rupture into the biliary tree? *AJR*, 2, 44.
9. Alper A, Ariogul O, Emre A, Uras A, Okten A. (1987). Choledochoduodenostomy for intrabiliary rupture of hydatid cysts of liver. *Br J Surg*, 74(4), 243-245.
10. Bedirli A, Sakrak O, Sozuer EM, Kerek M, Ince O. (2002). Surgical management of spontaneous intrabiliary rupture of hydatid liver cysts. *Surg Today*, 32(7), 594-597.

