

ISOLATED COMPARTMENT SYNDROME OF HAND IN CHILDREN BEWARE, ANTICIPATE AND TREAT EARLY:- A REVIEW

Harish Pai¹ and Harminder Singh^{2*}

¹Associate Professor, Orthopaedics, Subbaiah Institute of Medical Sciences, Shimoga, Karnataka, India.

²Postgraduate Physiology, Pt.BDS, PGIMS, Rohtak, Rohtak, India.

Article Info

Received 29/09/2015

Revised 16/10/2015

Accepted 19/11/2015

Keywords :-

Compartment syndrome,
Increase in anxiety,
Agitation, Dose of
analgesics.

ABSTRACT

Compartment syndrome of hand in children is usually associated with compartment syndrome of fore arm and arm due to many etiological factors like supra condylar fracture of the humerus, floating elbow, crush injury, vascular injury and iatrogenic factors. Isolated compartment syndrome of hand without fore arm involvement is rare but serious condition and is still rarer in children. Diagnosis can be missed in children as 5P's of compartment syndrome seen in adults is seen much later in children and is preceded by 3A's [increase in anxiety, increase in agitation and need of increased dose of analgesics]. We reviewed isolated compartment syndrome of hand in children regarding aetiology, diagnosis, anatomy of compartments and surgical decompression and outcome.

INTRODUCTION

Isolated acute compartment syndrome of hand in children is very rare but leaves permanent functional impairment of hand, if not diagnosed and managed at earliest. Compartment syndrome of forearm and arm are usually associated with hand, which is also rare but more frequent than isolated compartment syndrome of hand. The nature of injury leading to compartment syndrome in forearm and arm usually high energy injury and displaced fractures around the elbow joint. Sometimes isolated compartment syndrome of hand in children are not related to the fracture and are related to iatrogenic factors; which can be missed in early stage leading to complications. In children it is more difficult to diagnose because anxiety or apprehension related pain may be overlooked as behaviour of child to hospital or unknown environment. But anxiety or increase in anxiety is the first sign of compartment syndrome in the child i.e 3A's (increase in anxiety, increase in agitation, and increased need of analgesic dose) usually precedes classical 5p's signs of compartment

Email: - harminder697@gmail.com

syndrome in adults. There is no review of literature on isolated compartment syndrome of hand in paediatric population.

MATERIAL AND METHODS

Computerized search of literature was done with key words 1) compartment syndrome, hand, children, and 2) compartment syndrome, hand, paediatrics separately; then isolated acute compartment syndrome of hand in children included by excluding studies related to combination of forearm and arm, upper extremities, study with combination of compartment syndrome of hand in adults and children, and studies related to chronic compartment syndrome(VIC) and management of VIC. Literature was reviewed under the following headings. A)Aetiology B)Diagnosis C)Surgical anatomy D) Surgical management and outcome.

Aetiology: Isolated compartment syndrome of hand in children is very rare. Most of the literature is in case reports. Two case series have been reported but they are 1) compartment syndrome of upper extremity in children, 2) compartment syndrome of hand including adult population.

Corresponding Author

Harminder Singh

Review Article



Trauma, burns, tight fibercast/POP application, improper iv canulation, suction injuries, intra-arterial injection, compression bandages/wrap around wrist, and bony procedure around the wrist are the causes of isolated compartment syndrome of the hand [1,2,3]. Sawyer [4] reported insect bite on dorsum of hand leading to compartment syndrome after 18 hours of bite in a 5 year male child. Patratos [5] reported a similar case with wasp bite on volar aspect of left hand in 6 year female child after 24 hours of bite. In both cases, initially there was no acute swelling but started later due to enzymatic reaction to the peptides and amines of the insect bite or due to the initial heat application or application of local analgesic to relieve pain. Danish literature reported compartment of hand following adder bite to thumb [6]. Seitz reported the only case of isolated bilateral compartment syndrome of hand in 18 month old child [7]. Suwansrinon [8] did a study to know the local side-effects of Rabies immunoglobulin injection in finger and bite site of hand and showed that proper techniques with trained staff does not cause major

complication including compartment syndrome of the hand. Prasarn [9] reported 14 cases of compartment syndrome of hand including upper extremities without any fractures of which 8 were iatrogenic. He opined that in iatrogenic cases, diagnosis is often late leading to poor outcome. Collagen vascular disorders, coagulopathy can also lead to compartment syndrome where management is critical. Shin reported a case of compartment syndrome due to Henoch-Schönlein purpura [10].

Two cases of suction injuries in swimming pool where hand was sucked to suction mechanism of water in pool leading to compartment syndrome of hand in children have been reported [11]. Tight plaster application leading to hand compartment syndrome has not been reported in literature but hand swelling after plaster application is one of the common complaints and studies have shown that simple bi-valving the cast can decrease the pressure by 60% [12]. So it is advisable to bivalve the plaster in the immediate post operative period or after manipulation.

Figure 1. palmar and dorsal incision

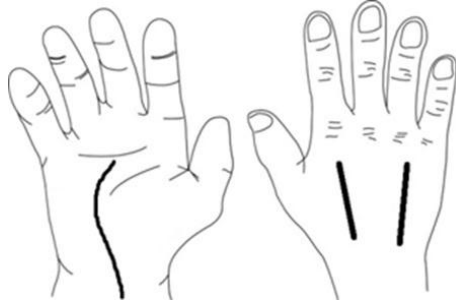
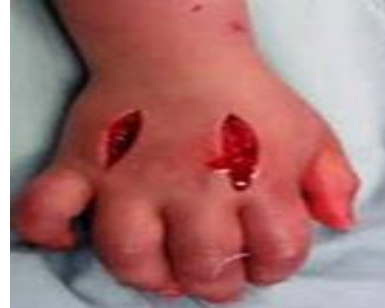

Figure 2. dorsal longitudinal incision



Diagnosis

High index of suspicion is required for early diagnosis, especially in children who cannot communicate and are apprehensive to strangers such as health care professionals. Iatrogenic hand compartment syndrome are common in children admitted in Intensive Care Units with altered sensorium. Delay in diagnosis and in surgical decompression may lead to poor functional results. Child complains of pain and swelling which are not relieved by normal dose of analgesics. Typically, a child is anxious and becomes agitated. Increase in anxiousness, increase in agitation and increased need of analgesic dose are important clues (3A's) or early signs of compartment syndrome of hand and should not be neglected as child tantrums [13]. 5P's like increase in stretch pain, paraesthesia, paresis or paralysis, pallor, and pulselessness are usually late signs of compartment syndrome. A study from Boston showed increase in analgesic need precedes early changes in vascularity by 7 hours in paediatric patients [14]. Hand will be swollen with typical intrinsic minus hand posture, normal softness of hand will be lost and will become firm to turgid. Tissue hardness is also an

indicator of severity or time of onset of compartment syndrome but it is variable from child to child and more of subjective value as it cannot be reproduced and is unreliable [15]. There will be passive stretch pain, loss of active movement of finger due to paresis in late stage. Older children can complain about paraesthesia indicating severity and need to decompress carpal tunnel completely. Initially there will be redness which will become pale as time progresses. As pulse can not be assessed in isolated hand swellings, delayed capillary circulation in fingers is recorded. Pulse oxymeter should record wave forms with saturation. 100% saturation without wave form is also an indicator of progress of compartment syndrome. Needle manometry measures the compartment pressure in each compartment of hand. Normal compartment pressure of hand and forearm is 3 to 22mmHg in children. More than 30mmHg compartment pressure is indicative of compartment syndrome. More than 45mmHg compartment pressure is considered as absolute compartment syndrome [16].

Surgical anatomy and decompression

There are ten separate osteofacial compartments in the hand. Each dorsal interossei and palmar interossei acts as a compartment. Thenar group and hypothenar group of muscles are two different compartments and adductor pollices acts as a separate compartment. So 4 dorsal interossei, 3 palmar interossei, one thenar, one hypothenar, and adductor pollices makes ten different compartments [17]. All ten compartment needs to be released. Two dorsal longitudinal incisions over second and fourth metacarpals gives access to all four interosseous space and releases seven compartments of interossei and adductor polices [fig-1 and 2]. Single palmar incision releases thenar, hypothenar compartment and, also the transverse carpal ligament which decompresses the median nerve in the carpal tunnel [fig-1]. Bulky compressive bandage is applied and anti oedema measures are taken. Care should be taken to prevent secondary infection. Once swelling reduces, wound is closed either by secondary suturing or by skin grafting. If there is any doubt of infection, skin grafting or secondary closure should be delayed. Usually dorsal incision is closed by secondary suturing and the palmar wound needs skin grafting. Occupational therapy has to be commenced immediately after secondary closure. Occupational therapy is concentrated on active and passive movement of finger, metacarpo-phalangeal (MCP) joints and wrist.

OUTCOME AND DISCUSSION

Children with compartment release should be regularly followed up for wound healing. Active and passive movements in the Wrist, MCP, and IP joint are assessed. Sensation of the finger should be checked. Grip strength, hook strength, pinch strength, release, two point discrimination, proprioception should be recorded as against the opposite hand periodically. Outcome depends on time duration between onset of compartment syndrome and decompression. Outcome is better with emergency or immediate decompression. There are no series or reviews

REFERENCES

1. Pai VS. (1997). Compartment syndrome of the hand-a case report. *Injury*, 28(5-6), 411-412.
2. Naidu SH, Heppenstall RB. (1994). Compartment syndrome of the forearm and hand. *Hand Clin*, 10(1), 13-27.
3. Alba RT, Ahn J. (2015). A swollen hand with blisters: a case of compartment syndrome in a child. *Pediatr Emerg Care*, 31(6), 425-426.
4. Sawyer JR, Kellum EL, Creek AT, Wood GW. (2010). Acute compartment syndrome of the hand after a wasp sting: a case report. *J Pediatr Orthop B*, 19(1), 82-85.
5. Petratos DV, Galanakos SP, Stavropoulos NA, Anastasopoulos JN. (2011). Late compartment syndrome of the hand due to wasp sting in a child. *J Surg Orthop Adv*, 20(3), 202-205.
6. Roed C, Bayer L, Lebech AM, Poulsen JB, Katzenstein T. (2009). Compartment syndrome following adder bites. *Ugeskr Laeger*, 171(5), 327-328.
7. Seitz WH, La Porte J, Shall J. (1987). Bilateral intrinsic compartment syndrome of the hands in an 18-month-old child. *Orthop Rev*, 16(11), 837-840.
8. Suwansrinon K, Jaijaroensup W, Wilde H, Sitprija V. (2006). Is injecting a finger with rabies immunoglobulin dangerous?. *Am J Trop Med Hyg*, 75(2), 363-364.
9. Prasarn ML, Ouellette EA, Livingstone A, Giuffrida AY. (2009). Acute pediatric upper extremity compartment syndrome in the absence of fracture. *J Pediatr Orthop*, 29(3), 263-268.

related to isolated hand compartment in children. But review of compartment syndrome in upper extremity has favourable outcome if decompression is done within 6 hours of onset (Prasarn et al) [9]. Kanj et al in his retrospective study of compartment syndrome of upper extremity in children analysed decompression before and after 24 hours [18].

Fair results were seen in delayed decompression though the results were not statistically significant, probably due to small sample size. It was seen that cases with compartment pressure more than 45 mmHg had stiffness and fair results as against those with compartment pressure 30mmHg who had excellent results. Finkelstein et al in his review showed decompression after 35 hours were associated with high rate of morbidity including amputation and even mortality due to septicaemia [19]. Prasarn reported poor prognosis in ICU admitted patients, which were mostly iatrogenic and diagnosis was delayed [20]. Ouelette et al reviewed 19 patients of compartment syndrome in hand in children and adults, showed poor results including amputation in children who were admitted in ICU with obtunded sensorium [21]. All the case reports related to compartment syndrome of the hand in children showed excellent outcome because of early diagnosis and management.

CONCLUSION

Acute compartment syndrome of hand in children is very rare. High index of suspicion especially in agitated children and ICU admitted paediatric patients with obtunded sensorium help in diagnosis. Prompt diagnosis, early decompression of all ten compartments with occupational therapy gives excellent long term outcome.

ACKNOWLEDGEMENT: None

CONFLICT OF INTEREST:

The authors declare that they have no conflict of interest.



10. Shin JI, Lee JS. (2009). Comment on: Left hand compartment syndrome: a rare complication of Henoch-Schönleinpurpura. *J Paediatr Child Health*, 45(5), 242.
11. Shin L A Y, Chambers H, Wilkins K E, Bucknell A. (1996). Suction injuries in children leading to acute compartment syndrome of the interosseous muscle of the hand: case reports. *J Hand Surg*, 21(4), 675-678.
12. Leigh W1, Pai V. (2005). Beware: compartment syndrome of the hand. *N Z Med J*, 11, 118(1209):U1300.
13. Kadiyala RK, Waters PM. (1998). Upper extremity pediatric compartment syndromes. *Hand Clin*, 14(3), 467-475.
14. Bae DS, Kadiyala RK, Waters PM. (2001). Acute compartment syndrome in children: contemporary diagnosis, treatment, and outcome. *J Pediatr Orthop*, 21(5), 680-688.
15. Joseph B, Varghese RA, Mulpuri K, Paravatty S, Kamath S, Nagaraja N. (2006). Measurement of tissue hardness: can this be a method of diagnosing compartment syndrome noninvasively in children?. *J Pediatr Orthop B*, 15(6):443-448.
16. Tharakan SJ(1), Subotic U, Kalisch M, Staubli G, Weber DM. (2015). Compartment Pressures in Children With Normal and Fractured Forearms: A Preliminary Report. *J Pediatr Orthop*, 2.
17. DiFelice A, Seiler III JG, Whitesides TE.(1998). The compartments of the hand: An anatomic study. *J Hand Surg*, 23A, 682-686.
18. Kanj W W, Melissa A. Gunderson M A, Carrigan R B, Wudbhav , Sankar N. (2013). Acute compartment syndrome of the upper extremity in children:diagnosis, management, and outcome.*J Child Orthop*, 7, 225-233.
19. Finkelstein JA, Hunter GA, Hu RW. (2013).Lower limb compartmentsyndrome: course after delayed fasciotomy. *J Child Orthop*, 7, 225-233.
20. Prasarn ML, Ouellette EA. (2011). Acute compartment syndrome of the upper extremity. *J Am Acad Orthop Surg*, 19(1), 49-58.
21. Ouellette E A, Kelly R. (1996). Compartment Syndromes of the Hand. *J Bone Joint Surg Am*, 78 (10), 1515 -1522.

