



PORCELAIN LAMINATE VENEER TECHNIQUE FOR ESTHETIC CORRECTION OF MIDLINE DIASTEMA

Akash Kumar Baranwal*

*Service Senior Resident, Faculty of Dental Sciences, IMS, BHU, Varanasi- 221005, Uttar Pradesh, India.

Corresponding Author:- **Akash Kumar Baranwal**
E-mail: baranwalakash@yahoo.com

Article Info

Received 15/09/2015

Revised 27/09/2015

Accepted 10/10/2015

Key words: Midline diastema, Esthetic, conservative preparation, Porcelain laminate veneers.

ABSTRACT

The rehabilitation of smile esthetics with thin veneers is indicated to correct morphologic anomalies. Porcelain laminate veneers can be applied to reduce or eliminate diastemas and represent a good esthetic non-invasive alternative for such patients. A 17-year-old male patient was presented with chief complaint of space between the upper front teeth. On intra-oral examination, there was midline diastema between the maxillary central incisors. This case report is about highlighting the step by step conservative and esthetic management of a patient with maxillary midline diastema using porcelain laminate veneer technique.

INTRODUCTION

In the recent world of cosmetics, there is increasing demand for naturally appearing and esthetic restorations. However, the esthetic appearances of such restorations are usually may affected by various problems, like diastema in the midline, asymmetrical teeth arrangement and proportion, asymmetry of the gingival level and tooth discoloration. [1-3]

The presence of a midline diastema may generally restrict a pleasing smile. Till date, several treatment options have been provided to close the space between maxillary anterior teeth, [3-5] but a proper diagnosis of the underlying cause is important in deciding the appropriate treatment plan. Several etiological factors have been considered as the causes of diastema that may include trauma from occlusion, oral habits (such as bruxism, mouth breathing, tongue thrusting, sucking habits, pipe smoking, and playing of wind instruments), abnormal labial frenum, gingival overgrowth, and iatrogenic factors. [4-6]

While managing diastema cases through restorative approaches, the direct restoration with composite resin has advantages such as conservation of

tooth tissue, low cost, reversibility, and a relatively simple technique. [7] Whereas, considering the extensive tooth reconstruction, composites may produce high failure rate, at an average rate of 2.9% annually. [8]

In the present era of esthetic restorative materials, ceramic proposes a valid option for indirect esthetic restorations [9,10] especially in the form of veneers. [9,11] Porcelain contain superior properties of compressive strength, surface smoothness, abrasion resistance, gloss, and low plaque accumulation. [12,13]

Therefore, the purpose of this clinical case report is about highlighting the step by step conservative and esthetic management of a patient with maxillary midline diastema using porcelain laminate veneer technique.

Case Report

A 17-year-old male patient was presented to the Department of Conservative Dentistry and Endodontics, Dr. R. Ahmed Dental College & Hospital, Kolkata with chief complaint of space between the upper front teeth. The past medical history was non-contributory. On intra-oral



examination, there was midline diastema between the maxillary central incisors. Also, there was some spacing between the lower central incisors, but the patient was more concerned about the maxillary midline diastema. The etiology was confirmed non-significant. The pre-operative intra-oral photograph has been shown in fig. 1.

The patient was reluctant for the orthodontic treatment because of its long treatment duration. He wanted to have earliest esthetic correction especially for the maxillary midline diastema. Various treatment options were provided to the patient including the composite as well as the ceramic veneering.

Treatment progress

After thorough examination, impressions for diagnostic models were made in irreversible hydrocolloid. The models were studied to decide the shape and size of the restorations with help of a diagnostic wax up. Within diagnostic wax up, little space was kept between 11 & 21 in order to simulate the harmony with the lower central incisors and the patient was satisfied with it. To provide a long term solution, the patient was provided the option of porcelain laminate veneers. The patient agreed and opted for maxillary correction only as the mandibular incisors were less visible. The advantages, disadvantages of material and procedural details were explained to the patient.

Tooth Preparation and Impression

The final treatment plan was consisted of the conservative preparations of maxillary central incisors for the porcelain laminate veneers. Before proceeding for tooth preparation, shade was selected using Vitapan Classical shade guide. The tooth preparation was kept in enamel at a depth of 0.5mm at body of tooth and depth of 0.3 mm at cervical region using a depth cutting diamond and the depth cuts were marked with black marker pen to provide a uniform reduction with a long round ended tapered diamond. 0.3 mm chamfer was maintained in the cervical region. The chamfer finish lines were kept at the level of gingival margin. (Fig. 2).

The incisal chamfer was extended palatally to produce incisor lap design. The centric stops were carefully checked during preparing the palatal finish line. The mesial margins of both 11 & 21 preparation was extended beyond the contact area and the margins were kept at their palato-mesial line angles to mask the visibility of tooth-restoration junction while the distal margins of the preparations were kept just labial to their respective contact points.

After finishing the margins, gingival retraction (fig. 3) was performed to help produce an accurate impression. Impression of the maxillary arch was made with addition silicone (Affinis, Coltene Whaledent) using single step double mix technique. Following proper disinfection protocol for impression, it was transferred to the dental lab for ceramic veneers fabrication. Provisional

restorations were not required as the tooth reduction was minimal and restricted to enamel.

Cementation of Veneers

First, the fabricated veneers (fig. 4) were tried in for shade, fit, marginal adaptation, shape, size, symmetry and contacts at prepared cast (fig. 5) and then tried-in individually using glycerin (as holding medium). After individual confirmation, a collective try-in was done to evaluate the esthetic enhancement. Patient was satisfied and gave approval at the time of try-in.

Laminate Preparation:

The inner portion of laminates was etched carefully with 5% Hydrofluoric (HF) acid (Ivoclar Vivadent) (Fig. 6) for 3 minutes avoiding any facial surface contact. After etching, they were washed thoroughly using copious amount of water. On drying, a coat of silane coupling agent (Ivoclar Vivadent) was applied (Fig. 7) and left it for a minute.

Tooth Preparation:

First, the prepared surfaces of teeth were cleaned with pumice slurry using rubber cup attached to contra-angled handpiece. The prepared teeth were etched using 37% Phosphoric Acid for 15 seconds and then washed out with water. After drying the surface with tissue paper, bonding agent (Tetric N-Bond, Ivoclar Vivadent) was applied on the prepared teeth as well on bonding surfaces of veneers with help of micro-applicator but not cured since curing may hinder the seating of veneers.

Dual cure resin crown and bridge luting agent (Multilink speed, Ivoclar Vivadent) was used for cementation. (Fig. 8) The laminates were spot cured for 5seconds initially. Excess cement was removed with B.P. blade no. 12 and then complete curing was done for 20 seconds from each side. Proximal finishing was done using proximal abrasive strips. On completion of the cementation procedure, the occlusion was checked in centric as well eccentric positions for interferences. The complete armamentarium used for this case and the post-treatment photograph has been shown in fig. 9 and fig. 10 respectively.

DISCUSSION

The presence of a diastema causes esthetic problems especially affecting the young patients and it may restrict their smile profile. Prosthetic and conservative approaches are generally considered to treat diastemas, especially because of their minimally invasive procedures.

The present case report justifies the choice of diastema closure, because the patient felt uncomfortable while speaking or smiling in public due to esthetic insufficiency. Study models and wax-ups become necessary to evaluate the clinical conditions, restoration form, occlusal factors, and esthetic design. [14] The mock-up constructed with dental wax helps the dentist and



patient to make choice about the material, as well as the shape & size of teeth. [15]. Smaller diastema can be managed with hybrid resins, as composite resin are easy to use, but they offer less wear resistance and unavoidable surface staining which usually keep composite inferior to dental porcelain. [16] On contrary, the ceramics have predictable, esthetic, and long lasting outcomes. [17]

Hence, knowing this, the patient showed more interest towards porcelain laminates in the current case.

The procedure was intended to be minimally invasive, having veneers thicknesses of about 0.3 to 0.5 mm. The rehabilitation of smile esthetics with thin veneers can be considered to correct such morphologic anomalies. However, due to the thinness, these veneers may have limited applications for color changes. [18].

Figure 1. Pre-operative photograph

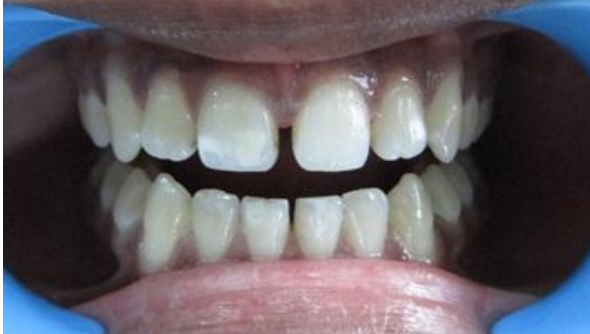

Figure 2. Tooth preparation for ceramic veneer

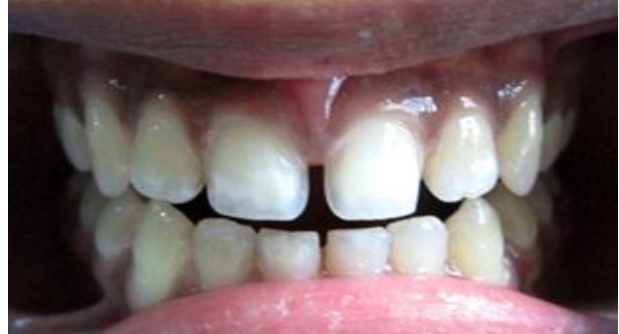

Figure 3. Retraction cord application

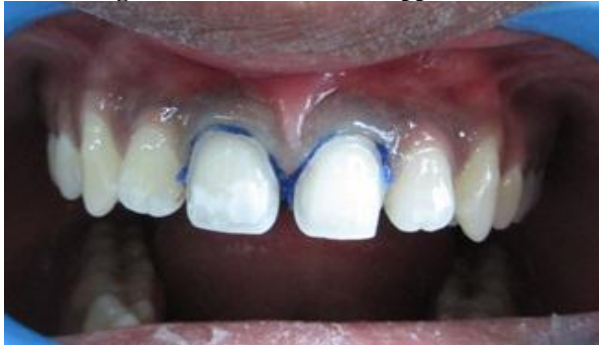

Figure 4. Fabricated veneer before cementation

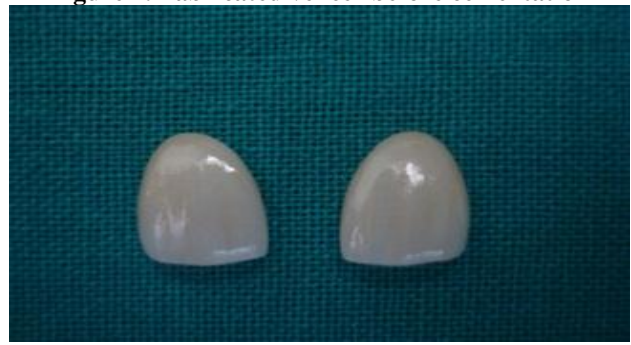


Figure 5. Try-in of veneers over cast

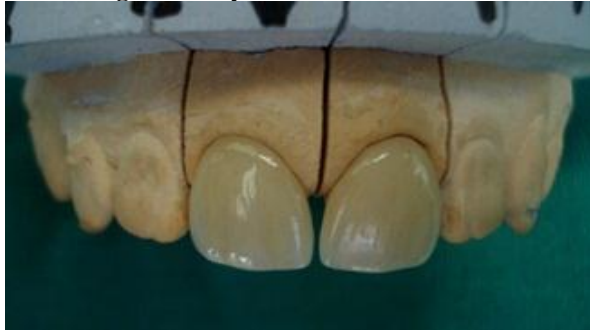

Figure 6. HF acid etching of inner side of laminate



Figure 7. Application of silane coupling agent

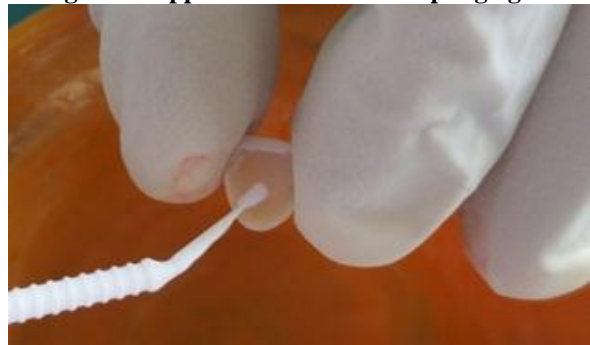

Figure 8. Application of dual cure resin cement

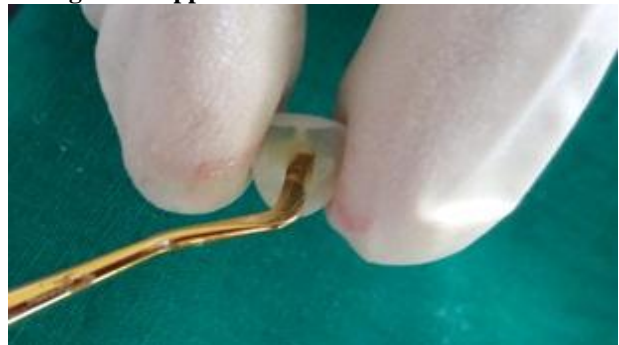
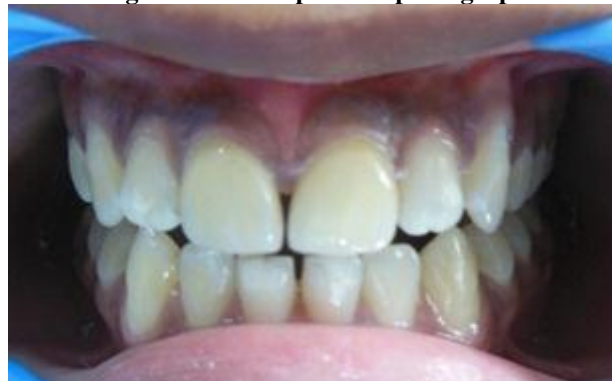
Figure 9. Armamentarium used for cementation



Figure 10. Post-operative photograph



CONCLUSION

The recreation of smile esthetics of a young patient having maxillary midline diastema with porcelain laminate veneers allows conservative preparations. Proper planning, correct selection of veneer material, and well co-ordination with lab technician help to achieve a pleasant smile and good satisfaction for both patient and dental clinicians.

ACKNOWLEDGEMENT: None

REFERENCES

1. Claman L, Alfaro MA, Mercado A. (2003). An interdisciplinary approach for improved esthetic results in the anterior maxilla. *J Prosthet Dent*, 89, 1-5.
2. Spear FM, Kokich VG. (2007). A multidisciplinary approach to esthetic dentistry. *Dent Clin North Am*, 51, 487-505.
3. Kim YI, Kim MJ, Choi JI, Park SB. (2012). A multidisciplinary approach for the management of pathologic tooth migration in a patient with moderately advanced periodontal disease. *Int J Periodon Restor Dent*, 32, 225-30.
4. Brunsvold MA. (2005). Pathologic tooth migration. *J Periodon*, 76, 859-66.
5. Oquendo A, Brea L, David S. (2011). Diastema: correction of excessive spaces in the esthetic zone. *Dent Clin North Am*, 55, 265-81.
6. Rohatgi S, Narula SC, Sharma RK, Tewari S, Bansal P. (2011). Clinical evaluation of correction of pathologic migration with periodontal therapy. *Quintessence Int*, 42, 22-30.
7. Heymann HO, Hershey HG. (1985). Use of composite resin for restorative and orthodontic correction of anterior interdental spacing. *J Prosthet Dent*, 53, 766-771.
8. Tuncer D, Yazici A, Ozgünlaltay G, Dayangac B. (2013). Clinical evaluation of different adhesives used in the restoration of non-carious cervical lesions: 24-month results. *Aus Dent J*, 58, 94-100.
9. Walter RD, Raigrodski AJ. (2008). Critical appraisal: clinical considerations for restoring mandibular incisors with porcelain laminate veneers. *J Esthet Restor Dent*, 20, 276-281.
10. Guess PC, Stappert CF, Strub JR. (2006). Preliminary clinical results of a prospective study of IPS e.max Press- and Cerec Pro CAD- partial coverage crowns [In German]. *Schweiz Monatsschr Zahnmed*, 116, 493-500.
11. Signore A, Kaitsas V, Tonoli A, Angiero F, Silvestrini-Biavati A, Benedicenti S. (2013) Sectional porcelain veneers for a maxillary midline diastema closure: a case report. *Quintess Int*, 44, 201-206.
12. Seghi RR, Sorensen JA. (1995). Relative flexural strength of six new ceramic materials. *Int J Prostho*, 8, 239-246.
13. McLaren EA. (1998). All-ceramic alternatives to conventional metal-ceramic restorations. *Compend Contin Educ Dent*, 19, 307-308.
14. Rudd KD. (1968). Making diagnostic casts is not a waste of time. *J Prosthet Dent*, 20, 98-100.
15. Morley J. (1999). The role of cosmetic dentistry in restoring a youthful appearance. *J Am Dent Assoc*, 130, 1166-1172.
16. Cho GC, Donovan TE, Chee WW. (1998). Clinical experiences with bonded porcelain laminate veneers. *J Califor Dent Assoc*, 26(2), 121-127.
17. de Andrade OS, Ferreira LA, Hirata R, Rodrigues FP, D'Alpino PH, Di Hipolito V. (2012) Esthetic and functional rehabilitation of crowded mandibular anterior teeth using ceramic veneers: a case report. *QuintessInt*, 43, 661-670.
18. Dozic A, Tsagkari M, Khashayar G, Aboushelib M. (2010). Color management of porcelain veneers: influence of dentin and resin cement colors. *Quintess Int*, 41, 567-573.

CONFLICT OF INTEREST

The authors declare that they have no conflict of interest.

STATEMENT OF HUMAN AND ANIMAL RIGHTS

All procedures performed in human participants were in accordance with the ethical standards of the institutional research committee and with the 1964 Helsinki declaration and its later amendments or comparable ethical standards. This article does not contain any studies with animals performed by any of the authors.

