



AMERICAN JOURNAL OF ADVANCES IN NURSING RESEARCH

Journal homepage: www.mcmed.us/journal/ajanr



CARING FOR A PATIENT WITH RUPTURED SINUS OF VALSALVA (RSOV): A CASE REPORT

Gipsi Baby^{1*} and Rohini T²

¹Second Year MSc Nursing Student, Samaritan College of Nursing, Pazhanganad – 683562, Kizhakambalam PO, Ernakulam District, Kerala, India.

²Professor, Samaritan College of Nursing, Pazhanganad – 683562, Kizhakambalam PO, Ernakulam District, Kerala, India.

Article Info

Received 25/05/2016

Revised 30/05/2016

Accepted 05/06/2016

Key word: [RSOV]

Ruptured Sinus Of
Valsalva, [TEE]
Transesophageal Echo
Cardio graphy,
[MRI]cardiac Magnetic
Resonance Imaging,
Sinus of Valsalva
aneurysm[SVA].

ABSTRACT

A Sinus of Valsalva aneurysm [SVA] is a rare cardiac anomaly that may be congenital or acquired. It mostly affects the younger male group and they develop signs and symptom of palpitation and exertional dyspnea. The aneurysm may present as ruptured or unruptured. If the aneurysm ruptures, it causes acute symptoms of dyspnea. Echocardiography, Transesophageal Echocardiography [TEE], cardiac Magnetic Resonance Imaging is useful for diagnosis. The treatment of choice is surgical closure of the anomalies, which is the recommended treatment to avoid future complications [1]. Therefore nurses have a great role to play in the management of patient during pre-operative, post-operative and rehabilitation phase. For a comprehensive understanding of the condition RSOV, here is an article with the details of the disease - epidemiology, etiology, pathophysiology, clinical manifestations, diagnostic measures and the management presented along with a case report focusing on nursing management.

INTRODUCTION

Ruptured Sinus of Valsalva (RSOV) is a rare lesion that usually originates in the right or noncoronary aortic sinus and communicates with a cardiac chamber, frequently right sided, producing an aorto-cardiac fistula. Approximately 65-85% of SVAs originate from the right sinus of Valsalva, while SVAs originating from non coronary (10-30%) and left sinuses (< 5%) are exceedingly rare[2].

Anatomy and physiology

An aortic sinus is one of the anatomic portions of

the ascending aorta, which lies just above the aortic valve. There are three aortic sinuses: the left anterior, the right anterior, and the posterior. Sinus of Valsalva are the small out pouching in the root of aorta that support coronary artery origin which help maintain continuous blood supply to the heart both in systole and diastole.

Sinus of Valsalva (SV) is a dilatation of the aortic wall located between the aortic valve and the sinotubular junction. Its location is related to the coronary arteries designated as the Right Coronary Sinus (RCS), Left Coronary Sinus (LCS) and Noncoronary Sinus (NOCS) [3].

Case report

A 20 year old male suffered palpitations and generalized weakness since one year. Four months back, he suffered fever including exertional dyspnoea and when

Corresponding Author

Gipsi Baby

Email: gipsi1987@gmail.com



evaluated by a physician in his home town, he was identified to suffer some cardiac abnormality, for which he was referred to this hospital. On admission, he underwent Transesophageal Echocardiography [TEE] and 2D Echo which showed Ruptured Sinus of Valsalva Aneurysm to right atrium (Type III A with large left to right shunt] and sever Aortic Regurgitation. On clinical examination, he was thin weighing 48 Kg. Cardiac assessment revealed a continuous cardiac murmur. He was taken for the surgery [RSOV repair and Aortic Valve Replacement]. But after the RSOV repair, as the Transesophageal echocardiography [TEE] in the operation room table showed normal aortic flow and no evidence of Aortic Regurgitation, AVR was not done. RSOV repair was done with Impira patch aorta. Post operatively he was on ventilator in SIMV mode. He had two chest drains: one from the pericardium and the other in the mediastinum. On the same day, as his hemodynamic status was maintained within normal limits, he was extubated. Chest drains were removed on the second post operative day. He was on antibiotics, proton pump inhibitors, antipyretics and Vitamin B supplements. He was advised to follow all bronchial hygiene measures including incentive spirometry. He did not develop any post-operative complications. He was discharged in a healthy state and was advised to come for follow up visits.

Epidemiology

Higher frequency of RSOV is observed in the Asian surgical series. Male-to-female ratio is 4:1, including frequencies of both ruptured and unruptured SVA. Most ruptured SVAs occur from puberty to age 30 years and are often diagnosed or presented clinically at this age. Unruptured SVA is usually asymptomatic and is often detected serendipitously by routine 2-dimensional echocardiography, even in patients older than 60 years.

Associated structural defects in congenital SVAs include supracristal or perimembranous Ventricular Deftal defect (30-60%), bicuspid aortic valve (15-20%) and Aortic regurgitation (44-50%). Approximately 10% of patients with Marfan's syndrome have some form of SVA. Less commonly observed anomalies include pulmonary stenosis, coarctation, and Atrial septal defects. Rupture of SVA (with progressive heart failure and left-to-right shunting or endocarditis) is the main cause of death and rarely occurs before age 20 years in congenital SVA[4].

Etiology and Pathophysiology

SVA is a dilatation caused by the lack of continuity between the middle layer of the aortic wall and the aortic valve. This type of aneurysm is typically congenital and may be associated with heart

defects. It is sometimes associated with Marfan syndrome or Loeys-Dietz syndrome, but may also result from Ehlers-Danlos atherosclerosis, syphilis, cystic medial necrosis, chest injury, or infective endocarditis[3,4].

- Congenital SVA is caused by dilation, usually of a single sinus of Valsalva, from a separation between the aortic media and the annulus fibrosus.
- A deficiency of normal elastic tissue and abnormal development of the bulbus cordis have been associated with the development of SVA.
- Rupture of the dilated sinus may lead to intracardiac shunting when a communication is established with the right atrium (Gerbode defect [10%]) or directly into the right ventricle (60-90%).
- Cardiac tamponade may occur if the rupture involves the pericardial space[3,4].

This patient had intracardiac shunting where the communication was established with the right atrium leading to left to right shunt.

Classification system of ruptured sinus of Valsalva aneurysm by Sakakibara and Konno

Type I: the aneurysm originates in the left portion of the right sinus, protrudes forward and ruptures into the right ventricle near the pulmonary valve. The concurrent presence of Ventricular Septal Defect [VSD] under the pulmonary valve is frequent.

Type II: the aneurysm originates in the mid portion of the right sinus, protrudes and ruptures in the right ventricle. A concurrent VSD is uncommon.

Type III: the aneurysm originates in the mid portion of the right coronary leaflet and protrudes towards the tricuspid valve. It often ruptures into the right atrium and sometimes into the right ventricle, just below the septal leaflet of the tricuspid valve. VSD is rarely encountered.

Type IV: the aneurysm originates in the right portion of the noncoronary leaflet and ruptures into the right atrium. A combined VSD is uncommon [5, 6].

Clinical manifestations

If unruptured, this type of aneurysm may be asymptomatic and therefore go undetected until symptoms appear or medical imaging is performed for other reasons. A ruptured aneurysm typically leads to an aortocardiac shunt and progressively worsening heart failure[4,6].

The manifestations appear depending on the site where the sinus has ruptured. If the sinus ruptures in a low pressure area like the right atrium or right ventricle then a continuous type of murmur is heard. The murmur is located in the left parasternal region mainly confined to the lower sternum. It is also accompanied by a superficial thrill. A ruptured Sinus of Valsalva Aneurysm represents a surgical emergency [5].



Diagnostic measures

History and physical examination

In history, assess for congenital abnormalities and associated abnormalities like Marfan syndrome, atherosclerosis, syphilis etc.

In Physical examination, assess for

- A loud, superficial, "machine-type" continuous murmur
- A palpable thrill
- Bounding pulses

Transesophageal echocardiography [TEE] is the main diagnostic tool for the identification of the ASVs, while transesophageal imaging may further help the diagnosis and the cardiosurgical correction of the lesion, especially when VSD is also present.

Echocardiography can also provide important information necessary for the differential diagnosis from other disorders which cause continuous murmur, such as Patent Ductus Arteriosus, aortopulmonary window, coronary fistula, as well as coexisting VSD and aortic valve regurgitation.

Hemodynamic and angiographic study is used to detect the site of rupture as well as to estimate the patency of the coronary vessels, particularly in elderly patients.

Finally, **Magnetic Resonance Imaging** may be used to confirm the diagnosis.

Chest X ray helps to detect cardiomegaly and pulmonary edema [7]

Management

Medical management usually involves stabilization and perioperative assessment and management.

Transcatheter closure of Ruptured Sinus of Valsalva Aneurysm (SVA) has been successfully performed using Amplatzer devices. Ruptured SVA have been treated with transcatheter closure to avoid sternotomy and cardiopulmonary bypass in critically ill patients[8].

Open-heart surgery with or without aortic valve replacement remains the treatment of choice. Urgent surgical repair may be necessitated in patients with a ruptured SVA by means of primary suture closure (pledget) or patch closure. Repair can be performed percutaneously by means of transcatheter closure. Open heart surgery with aortic root repair or replacement and aortic valve repair or replacement may be required depending on the condition of the patient. Atrial or ventricular septal defect repairs may be performed in patients with septal defects. Patients with defects of the aorta may be treated with a Bentall procedure[9,10].

Nursing diagnosis

1. Decreased cardiac output related to blood loss during surgery and compromised myocardial function as evidenced by low blood pressure, decreased apical pulse and increased respiratory rate.

Goal: Normal cardiac output is restored as evidenced by normal BP, respiration and Apical pulse

Interventions

- Assessed cardiovascular status every 2 hourly to identify any change, indicative of worsening or improving condition
- Assessed arterial pressure every 15 minutes until it became stable
- Planned nursing care activities to improve cardiac output
- Administered inj. Dopamine infusion as per blood pressure level

Evaluation

- His blood pressure was 110/70 after the surgery with inotropic support and later increased to 120/80 with low inotropic support. On the second post operative day the blood pressure, apical pulse and respiration improved to normal without any support.
- Acute pain related to trauma of extensive chest surgery and pleural irritation caused by chest tubes as evidenced by pain score is 8/10 and facial grimaces.
- Goal: patient remains free from pain

Intervention

- Assessed pain level every 2 hourly to identify change indicative of worsening or improving of the pain
- Provided comfortable position [low fowlers, supine] for reducing the pain level
- Administered inj. Morphine (first post operative day 2 mg SOS, second post operative day 1 mg once) as per doctor order
- Controlled the environment to encourage rest; provided calm and quiet environment, restricted visitors and avoided bright lights in the ICU and room.

Evaluation

He had mild intermittent pain in the surgical site which could be noticed through his facial grimace and pain score level. His pain decreased by the above nursing interventions and from the third post operative day his pain score decreased to 3/10 and was free of pain during discharge.

1. Risk for infection related to trauma of extensive chest surgery and invasive lines

Goal: patient remains free from infection



Interventions

- Assessed surgical wound and invasive lines every second hourly for bleeding, redness and signs Provided aseptic technique during procedures- surgical site dressing, CVP dressing, Chest tube dressing, Catheter care etc
- Followed proper hand washing technique before and after caring the patient to prevent infection
- Administered antibiotic Inj.Tazobact 4.5 gm [Piperacilline and Tazobactam] IV BD

Evaluation

- There was no evidence of infection during his postoperative period.
- Risk for ineffective breathing pattern related to trauma of extensive chest surgery and pain.
- Goal: patient maintains effective respiratory pattern.

Interventions

- Assessed respiratory status every 2 hourly to identify the improvement in respiratory pattern
- Assessed Arterial Blood Gases, tidal volumes, peak inspiratory pressures and extubation parameters
- Suctioned tracheobronchial secretions as needed, using aseptic technique
- Auscultated the chest for breath sounds and provided chest physiotherapy as prescribed.
- Encouraged deep breathing, coughing, turning and use of incentive spirometer.
- Taught incisional splinting with a cough pillow to decrease the discomfort during deep breathing and coughing
- Administered Nebulization every sixth hourly with Duolin and Budecort

Evaluation

He maintained normal breathing pattern with help of all the above bronchial hygiene measures 5. Knowledge deficit regarding condition, postoperative care, self-care and discharge needs related to lack of exposure and information misinterpretation as evidenced by frequent questioning and inaccurate follow through of instruction.

Goal: patient verbalized understanding of condition, postoperative care, self-care and discharge needs

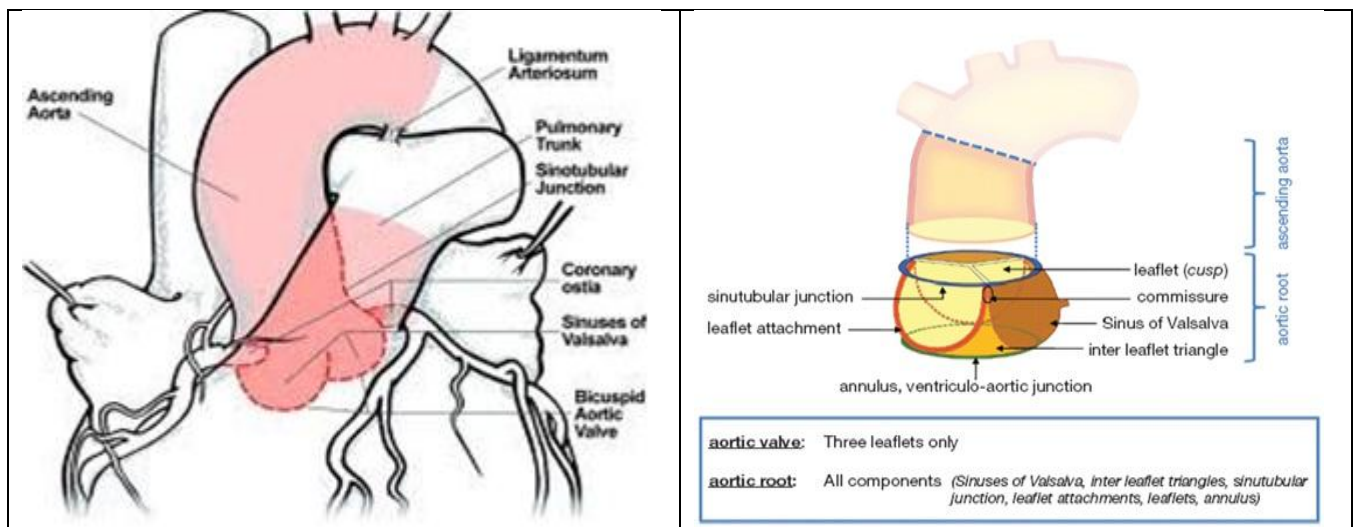
Intervention

- Assessed the level of knowledge regarding his condition, postoperative care, self-care and discharge needs.
- Provided health education regarding the post operative care and discharge needs of the patient [breathing exercises, ROM exercise, Incentive Spirometry, Care of the surgical site, Diet, Medication, signs and symptoms of complication and follow up.
- Encouraged him to express his doubts and clarified the doubts clearly
- Taught and demonstrated the bronchial hygiene methods and rehabilitative phase exercises

Evaluation

Patient verbalized gain in knowledge and performed the return demonstration of all rehabilitative measures and he cooperated well during his hospital days.

At the time of discharge patient verbalized feeling comfortable. He also expressed his confidence for the home care. His surgical wound was clean and there were no signs of infection. He was nursed at home by his Uncle with the help of rigorous training that was given during his hospital stay by nurses. The follow up revealed that he developed no further complication.



CONCLUSION

RSOV left untreated carries a dire prognosis. The prognosis is poor with progressive aneurysmal dilatation or rupture unless early surgical repair is performed. Therefore prompt therapy and nursing care goes hand in hand to achieve the best outcome. Nursing

care rendered need to be comprehensive and complete. The nurse needs to ensure that adequate education is provided to caregivers for ongoing care even at home.

Declaration of interest

There were no conflicts of interest reported.

REFERENCES

1. Sinus of Valsalva aneurysms [Internet]. Available from: https://www.researchgate.net/publication/227816974_Sinus_of_Valsalva_aneurysms
2. Ruptured Sinus of Valsalva Masquerading as Rheumatic Heart Disease [Internet]. Available from: <http://www.indianpediatrics.net/oct2012/oct-829-830.htm>.
3. Anatomy of the aortic root: implications for valve-sparing surgery – Charitos- Annals of Cardiothoracic Surgery [Internet]. Available from: <http://www.annalscts.com/article/view/1400/2025>.
4. Sinus of Valsalva Aneurysm: Background, Pathophysiology, Epidemiology [Internet]. Available from: <http://emedicine.medscape.com/article/158160-overview>.
5. Aneurysm of sinus of Valsalva – Wikipedia, the free encyclopedia [Internet]. Available from: https://en.wikipedia.org/wiki/Aneurysm_of_sinus_of_Valsalva#Causes.
6. Modified Sakakibara classification system for ruptured sinus of Valsalva aneurysm. – PubMed – NCBI [Internet]. [cited 2016 May 14]. Available from: <http://www.ncbi.nlm.nih.gov/pubmed/23312973>.
7. Lakoumentas JA, Bonou MS, Brili S, Theocaharis CS, Benroubis AD, Perpinia AS, et al. Ruptured aneurysm of the right sinus of Valsalva into the right ventricle. *Hellenic J Cardiol*, 43, 2002, 242-5.
8. Transcatheter Closure of Ruptured Sinus of Valsalva Aneurysm Using the Amplatzer Duct Occluder in a Critically Ill Post-CABG Pat | Journal of Invasive Cardiology [Internet]. Available from: <http://www.invasivecardiology.com/article/7328>.
9. Surgical Repair of Ruptured Sinus of Valsalva Dubai | Abu Dhabi | Sharjah [Internet]. Available from: <http://www.nmcheartcare.ae/surgical-repair-of-ruptured-sinus-of-valsalva-rsoy>.
10. Untitled - 2009-77-06-441-445.pdf [Internet]. Available from: <http://circiruj.edilaser.net/en/pdf/7706/2009-77-06-441-445.pdf>

