



FABRICATION OF OCULAR PROSTHESIS : AN ALTERNATIVE TECHNIQUE

A.V.Sreekumar¹, Sahela Hashim^{2*}, Nishna Pradeep³

¹Prof & HOD, ²Post Graduate, ³Professor, Department of Prosthodontics, Kannur Dental College, Kerala, India.

Corresponding Author:- **Sahela Hashim**
E-mail: sahlahashim@gmail.com

<p>Article Info <i>Received 15/01/2016</i> <i>Revised 27/02/2016</i> <i>Accepted 2/03/2016</i></p> <p>Key words: Ocular prosthesis, Stock eyes</p>	<p>ABSTRACT Rehabilitation of facial defects is a complex task and most of the time it requires a customized design for each patient. The disfigurement associated with the loss of an eye may result in both physical and emotional problems. Nowadays various treatment modalities are available and different types of ocular prosthesis are in use that includes stock eyes, stock eyes modified by various methods and custom fitted eyes. This article presents clinical report of a patient rehabilitated with custom made ocular prosthesis.</p>
--------------------------------------------------------------------------------------------------------------------------------------------------------------------------------------	---------------------------------------------------------------------------------------------------------------------------------------------------------------------------------------------------------------------------------------------------------------------------------------------------------------------------------------------------------------------------------------------------------------------------------------------------------------------------------------------------------------------------------------------------------------------

INTRODUCTION

The loss of part of the face can have a physical, social, and psychological impact on those affected and it prevents an individual from leading a normal life. When esthetic and functional demands cannot be surgically fulfilled, a facial prosthesis can be considered as an alternative [1]. Maxillofacial prostheses, which restore and replace stomatognathic and associated facial structures with artificial substitutes, aim to improve the patient's esthetics, restore and maintain health of the remaining structures, and consequently provide physical and mental well-being [2]. The demand for maxillofacial prostheses has been reported to be high and one quarter of that demand is related to ocular defects [3]. Disfigurement associated with loss of eye can cause significant physical and emotional problems to the individual. A prosthesis should be provided as soon as possible to raise the spirits and ease the mind of the afflicted.

Loss of an eye could be due to many reasons that include congenital reasons, trauma and tumor [4]. This condition requires early replacement so that the patient may return to a normal life. The primary objective in every case is to construct a prosthesis that will restore the defect, improve esthetics and thereby improves the confidence of

the patients. A facial prosthesis should be esthetic, durable, light weight, economical, and most importantly retentive.

An ocular prosthesis is a simulation of human anatomy using prosthetic materials to create the illusion of a perfectly normal healthy eye and surrounding tissues. Nowadays different types of ocular prosthesis are used: stock eyes, stock eyes modified by various methods and custom fitted eyes and implant supported prosthesis [5]. This article presents clinical report of a patients rehabilitated with custom made ocular prosthesis.

CASE REPORT:

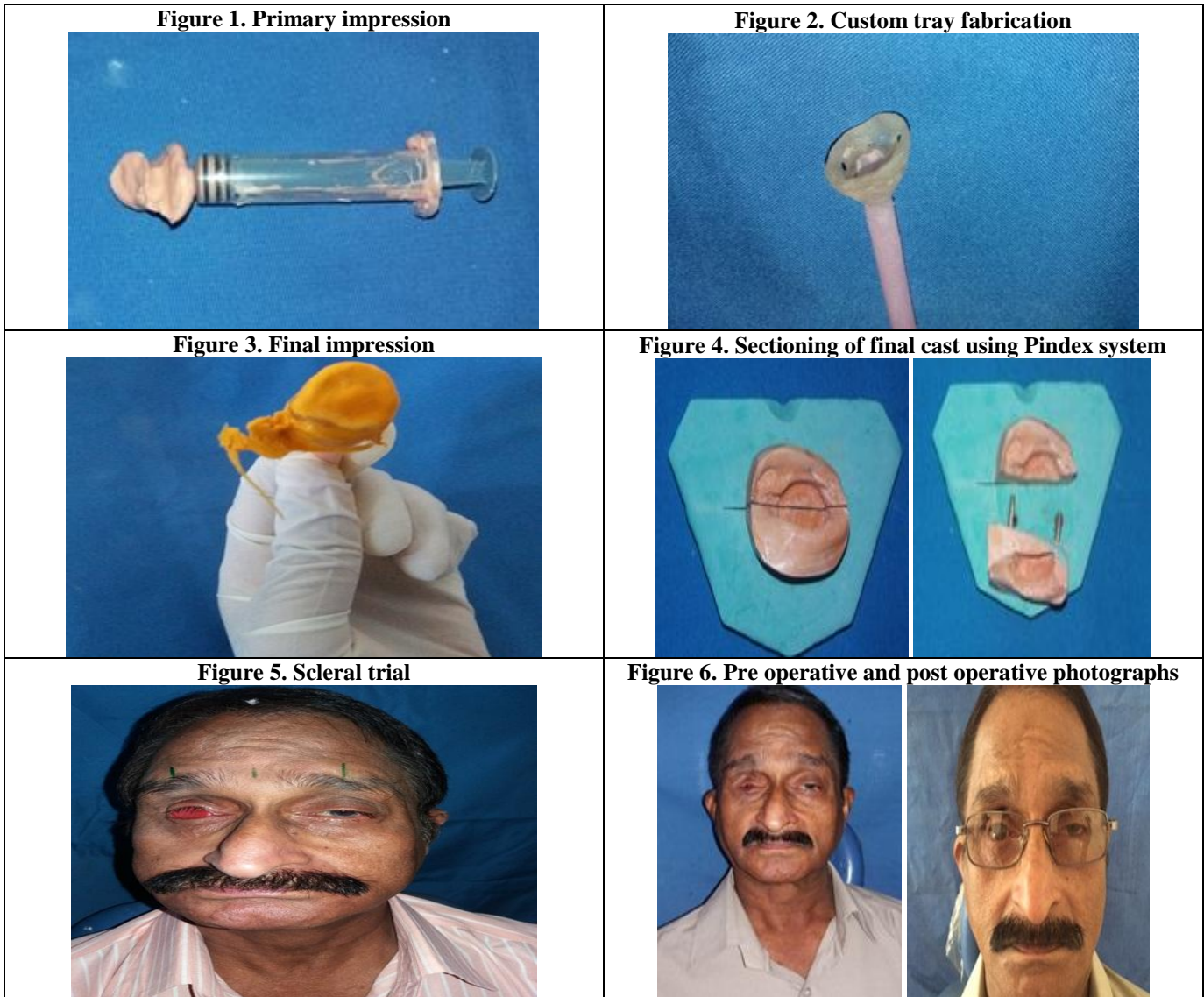
A 58 year old male patient reported to the Department of Prosthodontics, Kannur Dental College, Anjarakandy with a chief complaint of missing right eye, who had sustained severe traumatic injury to the right eye during his childhood. On examination, intraocular tissue bed was healthy. We have followed the below mentioned steps for the fabrication of custom made ocular prosthesis for this patient.

After thoroughly rinsed the socket with saline and anaesthetized with two drops of topical anesthetics and applied petroleum jelly for lubrication. Patient was asked



to sit in an erect position with the head tilted backward at an angle of 45 degree and primary impression was recorded by injecting irreversible hydrocolloid impression material. Impression was supported using the syringe which was used for injecting impression material (figure 1). Beading and boxing of the impression was performed and primary cast is made. A special tray was fabricated using auto-polymerising resin. Holes were made on the tray for retention as well as escape of excess impression material. A small tube was placed in the centre for

injecting impression material (figure 2). The special tray was tried inside the socket and final impression was recorded by injecting light body elastomer (figure3), impression removed and the model was prepared. We have attached 4-6 die pins and divided the model into two halves for easy removal of wax pattern (figure4). Scleral wax pattern was made using modeling wax (figure5). Later wax try in was performed, followed by iris try in. The final assembly was processed in conventional manner and prosthesis was delivered to the patient (figure 6).



DISCUSSION

A correctly placed ocular prosthesis should maintain its orientation when the patient is looking straight ahead and it should restore the normal opening of the eye, Stock artificial eyes are mass-produced and are an attempt to standardize size, shape, iris color, etc., which often not possible. A custom made or made-to-order artificial eye's are recommended for the majority of artificial eye wearers

support the eyelids, restore a degree of movement, and be adequately retained and esthetically pleasing [1]. Stock eye and custom made ocular prosthesis are the two important variants of maxillofacial prosthesis using nowadays [4]. [5]. Because the individual characteristics and physical requirements of the patient are taken into consideration, custom made artificial eyes will provide the patient with more comfort, mobility, and a superior cosmetic result.



Compared to stock eye, custom ocular prosthesis has several advantages, close adaptation to the tissue bed, better motility, distributes pressure more equally and thus reduce the incidence of ulceration, enhances tissue health by reducing the potential stagnation spaces at the prosthetic tissue interface (these voids collect mucous and debris which can irritate mucosa and act as potential source of infection) [7].

Immediate placement of an artificial eye after enucleation may not always be possible [8]. Delayed fitting of an ophthalmic socket with a conformer or prosthesis may result in its settling and sinking into the socket, compromising the esthetic appearance and adequate eyelid support of the defect region [9]. In such situations, delivering a temporary ocular prosthesis before a definitive one may prove time- and cost-effective for the patient [10]. The disadvantage of the method is that, requirement for an additional impression procedure that maybe uncomfortable for the patient. A correctly placed prosthesis should restore the normal opening of the eye, support the eyelids, restore a degree of movement, and be adequately retained and esthetically pleasing and it should maintain its orientation when the patient is looking straight ahead [11].

With stock ocular prosthesis excellent results can be attained for most patients, provided the operator has an adequate selection of prefabricated eyes. However, because of the extreme individual variation and diverse nature of ocular injuries, certain patients would benefit more from

custom made ocular prostheses which is modified according to their individual needs, especially for those who have lost ocular structures through orbital evisceration or orbital enucleation [12].

CONCLUSION

Prosthetic eye placement after enucleation may require multiple remakes of the delivered prosthesis because of the alterations to the size and shape of an ophthalmic socket. The fabrication of custom-made ocular prostheses that have been modified for each patient will provide a better acceptance of the prosthesis. The prosthodontist has to be flexible in their treatment modalities because each patient provides a challenge to develop and improve on old, accepted practices.

ACKNOWLEDGEMENT: None

CONFLICT OF INTEREST

The authors declare that they have no conflict of interest.

STATEMENT OF HUMAN AND ANIMAL RIGHTS

All procedures performed in human participants were in accordance with the ethical standards of the institutional research committee and with the 1964 Helsinki declaration and its later amendments or comparable ethical standards. This article does not contain any studies with animals performed by any of the authors.

REFERENCES

1. Sykes LM. (1996). Custom made ocular prostheses, a clinical report. *J Prosthet Dent*, 75(1), 1–3.
2. Pruthi G, Jain V. (2013). Light weight prosthesis for a patient with bilateral orbital exenteration--a clinical report. *J Prosthodont Res*, 57(2), 135–9.
3. Kale E, Meşe A, Izgi AD. (2008). A technique for fabrication of an interim ocular prosthesis. *J Prosthodont Off J Am Coll Prosthodont*, 17(8), 654–61.
4. Pai UY, Ansari NA, Gandage DS. (2011). A technique to achieve predictable iris positioning and symmetry in ocular and orbital prostheses. *J Prosthodont Off J Am Coll Prosthodont*, 20(3), 244–6.
5. Mathews MF, Smith RM, Sutton AJ, Hudson R. (2000). The ocular impression, a review of the literature and presentation of an alternate technique. *J Prosthodont Off J Am Coll Prosthodont*, 9(4), 210–6.
6. Goiato MC, Dos Santos DM, Moreno A, Filié Haddad M, Turcio KHL. (2013). An alternate impression technique for ocular prostheses. *J Prosthodont Off J Am Coll Prosthodont*, 22(4), 338–40.
7. Goutam M, Chandu GS, Gupta S, Shrivastava A, Singh M. (2015). A technique for changing the shade of a custom-made ocular prosthesis. *J Prosthet Dent*, 114(1), 149–50.
8. Aggarwal H, Singh RD, Kumar P, Gupta SK, Alvi HA. (2014). Prosthetic guidelines for ocular rehabilitation in patients with phthisis bulbi, a treatment-based classification system. *J Prosthet Dent*, 111(6), 525–8.
9. Karakoca-Nemli S, Aydin C, Yilmaz H, Bal BT. (2011). A method for fabricating an implant-retained orbital prosthesis using the existing prosthesis. *J Prosthodont Off J Am Coll Prosthodont*, 20(7), 583–6.
10. Hatamleh MM, Watson J, Srinivasan D. (2015). Closed-eye orbital prosthesis, a clinical report. *J Prosthet Dent*, 113(3), 246–9.
11. Gupta L, Aparna IN, Dhanasekar B, Prabhu N, Malla N, Agarwal P. (2014). Three-dimensional orientation of iris in an ocular prosthesis using a customized scale. *J Prosthodont Off J Am Coll Prosthodont*, 23(3), 252–5.
12. Hafezeqoran A, Koodaryan R. (2010). A technique for fabrication of an orbital prosthesis, a case report. *J Dent Res Dent Clin Dent Prospects*, 4(2), 69–73.

