



## **NEUROMUSCULAR VARIATION IN THE FOREARM – A CASE REPORT**

**Mayuri Hariharan**

Department of Anatomy, K. J. Somaiya Medical College, Somaiya Ayurvihar, Eastern Express Highway, Sion, Mumbai-400 022, Maharashtra, India.

Corresponding Author:- **Mayuri Hariharan**  
E-mail: [mayuri.hariharan@gmail.com](mailto:mayuri.hariharan@gmail.com)

<p><b>Article Info</b> <i>Received 15/01/2016</i> <i>Revised 27/02/2016</i> <i>Accepted 12/03/2016</i></p> <p><b>Key words:</b> Flexor Carpi Ulnaris, Ulnar Nerve, Ulnar Artery, Median Nerve, High Division of Dorsal Branch of Ulnar Nerve, Entrapment, Orthopaedicians, Fractures of Radius or Ulna, Anaesthetist, Pain Management Therapy.</p>	<p><b>ABSTRACT</b> During routine dissection, of the right upper limb of a 70 year old donated embalmed male cadaver in the Department of Anatomy, K.J. Somaiya Medical College, Sion, Mumbai, India, I observed an additional slip of flexor carpi ulnaris associated with anomalous high division of dorsal branch of ulnar nerve. The additional belly originated from the lower part of the flexor carpi ulnaris muscle and after crossing the ulnar nerve &amp; vessels and median nerve, it merged with the flexor retinaculum. The ulnar nerve divided into its terminal branches in the upper part of the forearm. However, the distribution of the terminal branches of ulnar nerve was normal in palm. The arterial pattern in the forearm was normal. The variations were unilateral and the left upper limb was normal. The photographs of the additional muscle slip of flexor carpi ulnaris associated with anomalous high division of dorsal branch of ulnar nerve were taken for proper documentation. Conclusion: The awareness of additional muscle slip of flexor carpi ulnaris associated with anomalous high division of dorsal branch of ulnar nerve is clinically important for surgeons dealing with entrapment or compressive neuropathies, orthopaedicians operating on the fractures of radius or ulna or both and anaesthetist performing pain management therapies on the upper limb. A lack of knowledge of such type of variations with different patterns might complicate surgical repair and may cause ineffective nerve blockade.</p>
--	--

### **INTRODUCTION**

Flexor carpi ulnaris muscle is the most medial superficial flexor muscle of forearm. It arises by two heads, humeral and ulnar, connected by a tendinous arch. The small humeral head arises from the medial epicondyle via the common superficial flexor origin. The ulnar head has an extensive origin from the medial margin of the olecranon process and proximal two-thirds of the posterior border of the ulna, an aponeurosis (which it shares with the extensor carpi ulnaris and flexor digitorum profundus), and from the intermuscular septum between it and flexor digitorum superficialis. A thick tendon forms along its anterolateral border in its distal half. The tendon is attached to the pisiform, and thence prolonged to the hamate and fifth metacarpal bone by pisohamate and pisometacarpal

ligaments. Acting with the flexor carpi radialis, it flexes the wrist and acting with the extensor carpi ulnaris it adducts the wrist. Flexor carpi ulnaris muscle is innervated by the ulnar nerve having root value C7, C8, T1. The line between the medial humeral epicondyle and the pisiform, along the anterior palmar margin of the muscle, is used as a reference point for locating the ulnar neurovascular bundle. The ulnar artery reaches the muscle in its middle third, whereas the ulnar nerve is covered by the muscle throughout its entire course running under the tendon in the wrist region [1]. The ulnar nerve has no branches in the arm, but it supplies articular branches to the elbow joint. It enters the forearm between two heads of flexor carpi ulnaris superficial to the ulnar collateral ligament. It



descends in the forearm between the flexor digitorum profundus and flexor carpi ulnaris muscles, pierces the deep fascia and enters the wrist through the Guyon's canal. In the distal canal, the ulnar nerve bifurcates into a superficial sensory branch and a deep motor branch, which supplies the hypothenar muscles and then passes across the palm, distributing to other intrinsic hand muscles [2].

**CASE REPORT**

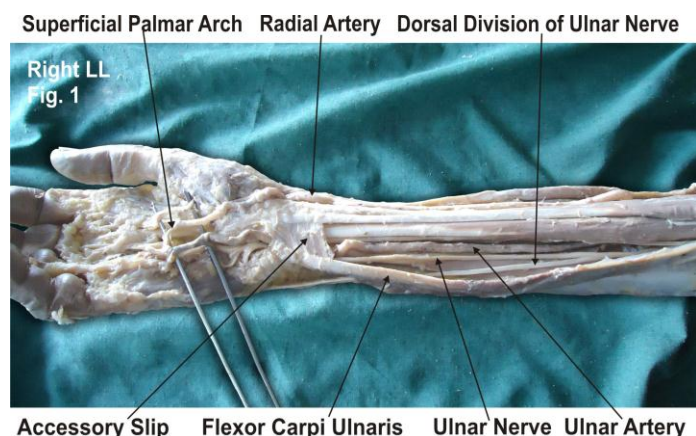
During routine dissection, of the right upper limb of a 70 year old donated embalmed male cadaver in the Department of Anatomy, K.J. Somaiya Medical College, Sion, Mumbai, India, I observed an additional muscle slip of flexor carpi ulnaris muscle associated with anomalous

high division of dorsal branch of the ulnar nerve. The additional belly originated from the lower part of the flexor carpi ulnaris muscle and crossed ulnar nerve, ulnar vessels and median nerve. The additional belly merged with the flexor retinaculum. The ulnar nerve divided into the terminal branches in the upper part of the forearm.

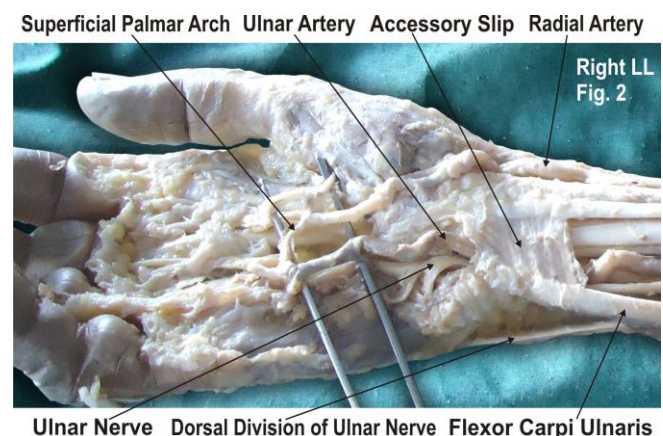
However, the distribution of the terminal branches of ulnar nerve was normal in palm. The arterial pattern in the forearm was normal. The variations were unilateral and the left upper limb was normal.

The photographs of the additional muscle slip of flexor carpi ulnaris associated with anomalous high division of dorsal branch of ulnar nerve were taken for proper documentation.

**Figure 1. The photographic presentation of an additional muscle slip from flexor carpi ulnaris muscle in the lower part of anterior compartment of the forearm associated with anomalous high division of dorsal branch of ulnar nerve.**



**Figure 2. The photographic presentation of additional belly originating from lower part of flexor carpi ulnaris muscle and crossing ulnar nerve, ulnar vessels and median nerve and merging with flexor retinaculum.**



**DISCUSSION:**

Anatomical variations of the flexor carpi ulnaris that have been reported previously are (a) variations in musculotendinous junction of the flexor carpi ulnaris muscle [3], (b) variant flexor carpi ulnaris causing ulnar nerve compression [4], (c) an additional slip of flexor carpi ulnaris [5] as in the present case. The FCU acts as an anatomical guideline for finding the neurovascular bundle (ulnar nerve, ulnar artery and accompanying venae comitantes), it can be easily palpated in its distal course if the wrist is flexed and adducted [6]. The present variation need to be taken into account when interpreting ultrasound and MR images, as well as during dissection of the ulnar neurovascular bundle when using FCU as a guideline. The flexor carpi ulnaris is a useful local muscle flap in the forearm and elbow. It is, however, an important palmar flexor and ulnar deviator of the wrist and functional loss may arise from the use of this muscle in its entirety. The flexor carpi ulnaris is made up of two distinct neuromuscular compartments. This arrangement allows for splitting of the muscle and the potential use of the larger ulnar compartment as a local muscle flap while

maintaining the humeral compartment as an ulnar deviator and palmar flexor of the wrist [7]. After multiple efforts to heal an infected nonunion of the proximal ulna, Meals [8] has used a flexor carpi ulnaris muscle pedicle flap to improve blood supply and soft tissue coverage at the non-union site and observed promoted bone healing and restoration of useful elbow function. Entrapment or compressive neuropathies are important and wide spread debilitating clinical problems. They are caused frequently as the nerve passes through a fibrous tunnel, or an opening in fibrous or muscular tissue. The most common is the median nerve entrapment in the wrist leading to carpal tunnel syndrome [9].

As in the present case, the crossing of accessory belly of the flexor carpi ulnaris muscle over the ulnar nerve and median nerve and compressing them might lead to numbness and tingling in the hand. This variation may be clinically important because symptoms of median nerve compression arising from similar variations are often confused with more common causes, such as, radiculopathy and carpal tunnel syndrome.



The knowledge of course and distribution of ulnar nerve can assist the surgeon in the diagnosis and treatment of conditions associated with the ulnar aspect of the hand. Recognition and diagnosis of this problem will help ensure timely and effective management of the more common pain syndromes.

#### **Clinical significance**

The anatomical variation described here has practical implications, since injury to the ulnar nerve in the upper part of forearm would, in this case, have caused unexpected loss of cutaneous sensation on the dorsum of the hand. The crossing of accessory belly of the flexor carpi ulnaris muscle over the ulnar nerve and the median nerve might compress them leading to numbness and tingling in the hand. The knowledge of this variation may be clinically important because the symptoms are similar to those of the carpal tunnel syndrome. The variation in the flexor carpi ulnaris muscle should be kept in mind by the plastic surgeons that are using the flexor carpi ulnaris muscle pedicle flap to improve blood supply and soft tissue coverage at the nonunion site of the proximal ulna for restoration of elbow function [10].

#### **CONCLUSION**

The awareness of additional muscle slip of flexor carpi ulnaris associated with anomalous high division of dorsal branch of ulnar nerve is clinically important for

surgeons dealing with entrapment or compressive neuropathies, orthopaedicians operating on the fractures of radius or ulna and anaesthetist performing pain management therapies on the upper limb. These variations are compared with the earlier data & it is concluded that variations in branching pattern of nerves are a rule rather than exception. A lack of knowledge of such type of variations with different patterns might complicate surgical repair and may cause ineffective nerve blockade.

#### **ACKNOWLEDGEMENT**

The author is thankful to Dean Dr. Geeta Niyogi Madam for her support and also thankful to the Head of Department Dr. Sawant and all the staff members of the Department of Anatomy. The author also acknowledges the immense help received from scholars whose articles are included as references in this paper.

#### **CONFLICT OF INTEREST**

The authors declare that they have no conflict of interest.

#### **STATEMENT OF HUMAN AND ANIMAL RIGHTS**

All procedures performed in human participants were in accordance with the ethical standards of the institutional research committee and with the 1964 Helsinki declaration and its later amendments or comparable ethical standards. This article does not contain any studies with animals performed by any of the authors.

#### **REFERENCES**

1. Williams PL, Dyson M, Standring S, Ellis H, Healy JC, Johnson D. (2005). Gray's Anatomy. 39th ed. London ELBS with Churchill Livingstone, 877.
2. Hollinshead WH. (1976). Functional anatomy of the limbs and back. 4th ed. Philadelphia, W.B. Saunders, 184-185.
3. Grechenig W, Clement H, Egner S, Tesch NP, Weiglein A & Peicha G. (2000). Musculo-tendinous junction of the flexor carpi ulnaris muscle. An anatomical study. *Surg. Radiol. Anat.*, 22, 255-60.
4. Al-Qattan MM & Duerksen F. (1992). A variant of flexor carpi ulnaris causing ulnar nerve compression. *J Anat*, 180, 189-190,.
5. Bergman, R. A., Thomson, S. A., Afifi, A. K. & Saadesh, F. A. (1988), Compendium of human anatomic variations. Urban & Schwarzenberg, Baltimore – Munich, 13.
6. Romanes GJ. (2003). Cunningham's Manual of Practical Anatomy. 15<sup>th</sup> edn. Upper and lower limbs. Oxford University Press, Vol 1, 74-5.
7. Lingaraj K, Lim AY, Puhaindran ME & Kumar PV. (2007). The split flexor carpi ulnaris as a local muscle flap. *Clin Orthop. Relat. Res*, 455, 262-6.
8. Meals RA. (1989). The use of a flexor carpi ulnaris muscle flap in the treatment of an infected nonunion of the proximal ulna. A case report. *Clin. Orthop. Relat. Res*, 240, 168- 72.
9. Moore KL, Dalley AF. (2006). Clinically oriented anatomy. 5 Ed., Baltimore, Lippincott Williams and Wilkins, 794, 819–822.
10. Kleinert H and Hayes J. (1971). The ulnar tunnel syndrome. *Plastic Reconstructive Surgery*, 47, 21-24.

