



A CASE REPORT ON VARIANT HEAD OF CORACOBRACHIALIS MUSCLE

Shaikh Mohammed Shaad Faisal

Department of Anatomy, K.J. Somaiya Medical College, Somaiya Ayurvihar, Eastern Express Highway, Sion,
Mumbai-400 022, Maharashtra, India.

Corresponding Author:- **Shaikh Mohammed Shaad Faisal**
E-mail: shaadshaikh7@gmail.com

Article Info <i>Received 15/01/2016</i> <i>Revised 27/02/2016</i> <i>Accepted 12/03/2016</i> Key words: Variant head, Coracobrachialis muscle, Brachial artery, Median Nerve, medial epicondyle of humerus, Surgeons, radiologists, pain management therapies.	ABSTRACT During routine dissection for First MBBS students on 65 years donated embalmed male cadaver in the Department of Anatomy, K.J. Somaiya Medical College, a variant head of the coracobrachialis muscle was observed in the left arm. It extended from the superficial fibres of coracobrachialis downwards and medially in front of the median nerve and brachial artery and finally was inserted on the anteromedial aspect of the medial epicondyle of the humerus. The length of the ligament was 15 cm and the diameter was 0.2 cm. The photographs were taken for proper documentation. The existence of accessory head of the coracobrachialis muscle should be kept in mind by surgeons operating on patients with high median nerve palsy and brachial artery compression and radiologists while doing scans of the arm and also anaesthetist performing pain management therapies on the upper limb.
---	---

INTRODUCTION

The coracobrachialis muscle shows several interesting morphological and anatomical characteristics. It is the counterpart in the arm of the adductors (longus, brevis, magnus) of the thigh. It arises from the apex of the coracoid process, where it is fused with the medial side of the short head of biceps.

The tendon is continued into a muscular belly of varying development which is inserted into the medial border of the humerus. The lower extent of the insertion is marked by the nutrient foramen of the humerus, for the nutrient branch of the brachial artery runs along the lower border of the muscle. The upward extent of the insertion cannot be seen on most bones, the muscle usually leaving no impression. The musculocutaneous nerve passes

through the muscle and supplies it. Compared to the morphological interest of this muscle its action is negligible. It is a weak adductor of the shoulder joint, the main adductors of which are pectoralis major and latissimus dorsi [1,2].

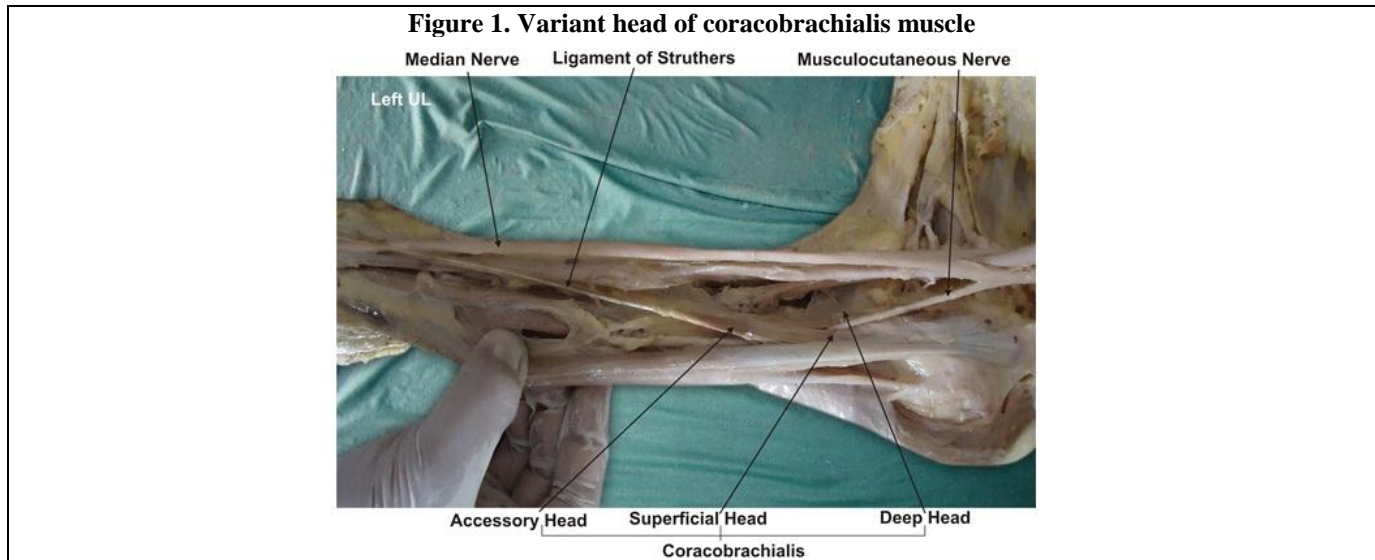
In some animals the coracobrachialis muscle has three heads in man two have fused, trapping the nerve between them, and the third part has become suppressed [3]. The occasional supratrochlear spur (on the anteromedial aspect of the lower humerus) may be continuous with a ligament (of Struthers) which passes to the medial epicondyle and represents the remains of the third head [4]. The median nerve or brachial artery or both may run beneath it and be subjected to compression.



CASE REPORT

During routine dissection for First MBBS students on a 65 years donated embalmed male cadaver in the Department of Anatomy, K.J. Somaiya Medical College, I observed an accessory head of the coracobrachialis muscle on the left side. It extended from the superficial fibres of

coracobrachialis downwards and medially in front of the median nerve and brachial artery and finally was inserted on the anteromedial aspect of the medial epicondyle of the humerus. The length of the ligament was 15 cm and the diameter was 0.2 cm. The photographs were taken for proper documentation.



DISCUSSION

The accessory head of coracobrachialis muscle may be attached to the lesser tubercle, medial epicondyle or medial intermuscular septum. The clinical implication of the accessory head of coracobrachialis is that it has the potential to cause median nerve entrapment and brachial artery compression. Various studies have described the compression of median nerve and brachial artery with anomalous muscles [5,6,7,8].

According to some authors the accessory head of the coracobrachialis continues with the medial head of triceps to be inserted on the olecranon process of ulna. This additional belly extending towards the ulna through the triceps brachii can be called “coracoulnaris”. The “coracoulnaris” muscle can help in the extension of the elbow and pronation of the forearm [9]. In the present case the accessory head of coracobrachialis muscle arises from superficial fibres of coracobrachialis muscle having 3cm muscle belly and 15cm tendinous band. It extended downwards and medially in front of the median nerve and brachial artery and finally got inserted on the anteromedial aspect of the medial epicondyle of the humerus. An important finding in our case is a passage for the brachial artery and median nerve formed by the tendinous band of the accessory head of the coracobrachialis muscle. This tendinous band forming the tunnel is called as Ligament of Struthers. Other openings, however, have been described for the passage of the median nerve and brachial artery, the most common being the tunnel formed beneath the ligament of Struthers [4].

Embryological Basis

The accessory head of the coracobrachialis muscle reported in this case may be explained on the basis of the embryogenesis of the muscles of the arm. During development, the limb bud mesenchyme of the lateral plate differentiates into intrinsic muscles of the upper limb. A single muscle mass is formed by fusion of the muscle primordia within the different layers of the arm at certain stages of development; thereafter, some muscle primordia disappears through cell death. The morphological variations of the coracobrachialis muscle may be due to failure of muscle primordia to disappear during embryological development [9].

Clinical Significance

The neurovascular bundle of the arm may undergo active or passive compression by ligament of Struthers leading to neurovascular disorders. It may lead to wasting or ischaemic contraction of flexors of the forearm. This variation is important during the active use of coracobrachialis as a transposition flap in deformities of infraclavicular and axillary areas and in postmastectomy reconstruction [10]; during surgical intervention of the anterior compartment of the arm, such as trauma, tumour, neurovascular disease; while using conjoint tendon for stabilisation treatment for recurrent dislocation and subluxation of the shoulder joint; while using coracobrachialis as a vascularised muscle for transfer in the treatment of longstanding facial paralysis during evaluation of computed tomography (CT) and magnetic resonance (MR) imaging [11].



CONCLUSION

As the coracobrachialis is also a guide to the axillary artery during surgery and anaesthesia, knowledge of this abnormal insertion may prove significant. Accessory muscles in the arm and forearm may lead to confusion during surgical procedures or cause compression of neurovascular structures. To avoid clinical complications, during radiodiagnostic procedures (e.g. CT, MR imaging) or surgical approach of these regions, awareness of such variations must be borne in mind. These types of variations are interesting not only to anatomists, but also to orthopaedic surgeons, physiotherapists and radiologists.

ACKNOWLEDGEMENT

The author wishes to convey sincere thanks to Dean Dr. Geeta Niyogi Madam for her valuable help, support and inspiration. The author is also thankful to the

Head of Department Dr. Sawant and all staff members of Department of Anatomy. The author also acknowledges the immense help received from the scholars whose articles are cited and included in references of this manuscript. The authors are also grateful to authors / editors / publishers of all those articles, journals and books from where the literature for this article has been reviewed and discussed.

CONFLICT OF INTEREST

The authors declare that they have no conflict of interest.

STATEMENT OF HUMAN AND ANIMAL RIGHTS

All procedures performed in human participants were in accordance with the ethical standards of the institutional research committee and with the 1964 Helsinki declaration and its later amendments or comparable ethical standards. This article does not contain any studies with animals performed by any of the authors.

REFERENCES

1. McMinn RMH. (1990). Editor *Last's anatomy, regional and applied*. Edinburgh, Churchill Livingstone, 79.
2. Williams PL, Warwick R, Dyson M, Bannister LH. (2005). Editors *Gray's anatomy*. 39. Edinburgh-London, Churchill Livingstone, 852.
3. Parsons FG. (1898). The muscles of mammals with special relation to human myology. *J Anat*, 32, 721-52.
4. Struthers J. (1854). On some points in the abnormal anatomy of the arm. *Br Foreign Med Chir Rev*, 14, 224-36.
5. Dharap AS. (1994). An anomalous muscle in the distal half of the arm. *Surg Radiol Anat*, 16, 97-99.
6. El-Naggar M. (2001). A study on the morphology of the coracobrachialis muscle and its relationship with the musculocutaneous nerve. *Folia Morphol (Warsz)*, 60, 217-224.
7. Sharadkumar Pralhad Sawant. (2012). Variant Coracobrachialis Muscle - A Case Report. *International Journal of Health Sciences & Research*, 107, 2(8).
8. Wood J. (1867). On human muscular variations and their relation to comparative anatomy. *J Anat Physiol*, 1, 44-59.
9. Lewis WH. (1910). The development of the muscular system. In, Keibel F, Mall FP, ed. *Manual of Embryology*, Vol 2. Philadelphia, JB Lippincott, 455-522.
10. Kopuz C, Icten N, Yildirim M. (2003). A rare accessory coracobrachialis muscle, a review of the literature. *Surg Radiol Anat*, 24, 406-10.
11. Jiang LS, Cui YM, Zhou ZD, Dai LY. (2007). Stabilizing effect of the transferred conjoined tendon on shoulder stability. *Knee Surg Sports Traumatol Arthrosc*, 15, 800-5.

