



A CASE REPORT ON VARIANT EXTENSORS OF FOREARM.

Manisha Nair Mahendran

Department of Anatomy, K.J. Somaiya Medical College, Somaiya Ayurvihar, Eastern Express Highway, Sion,
Mumbai-400 022, Maharashtra, India.

Corresponding Author:- **Manisha Nair Mahendran**
E-mail: manisha0608@gmail.com

<p>Article Info</p> <p><i>Received 15/01/2016</i> <i>Revised 27/02/2016</i> <i>Accepted 12/03/2016</i></p> <p>Key words: Anatomical variations; Development; Extensor carpi radialis longus and brevis muscles; Forearm; Radial nerve.</p>	<p>ABSTRACT</p> <p>During routine dissection in the Department of Anatomy, multiple variations of forearm muscles in relation to the radial nerve and its branches were observed on the right side of a 34 year old male cadaver. Brachioradialis close to its origin was receiving muscle fibers from the brachialis and the radial nerve was passing in between them. Extensor carpi radialis brevis was absent and the extensor carpi radialis longus was giving two tendons in the second compartment of extensor retinaculum before its insertion while passing deep to the abductor pollicis longus. Absence of extensor carpi radialis brevis can be explained with the arrangement in lower mammals, where the two extensor carpi radialis are represented by one muscle. Ontogeny repeats phylogeny and anatomical variations have developmental basis. Hence, the pattern of muscular arrangement in this case can be said to be less evolved than the usual arrangement. The course of radial nerve between the two heads of brachioradialis makes it highly vulnerable to compression and injury, which may manifest as wrist drop (radial nerve palsy) or radial tunnel syndrome (compression of posterior interosseous nerve).</p>
--	---

INTRODUCTION

Marked variations from the normal are rarely seen in superficial group of extensors [1]. The radial nerve in the lower part of arm lies between the brachialis and the brachioradialis and extensor carpi radialis longus muscles and this position gives off the nerves to the superficial group of extensors [2]. The radial tunnel is described as a 5-cm long furrow bounded by brachialis and the biceps tendon medially and the mobile extensor muscles anterolaterally, beginning just proximal to the radiocarpal joint and ending at the distal edge of supinator. After the point of bifurcation of the radial nerve, the posterior interosseous nerve (PIN) travels through the radial tunnel, an area that varies but begins in the furrow between the Brachioradialis and brachialis in the distal arm and ends at the distal edge of the supinator muscle in the proximal forearm [3]. The most common MRI (magnetic resonance

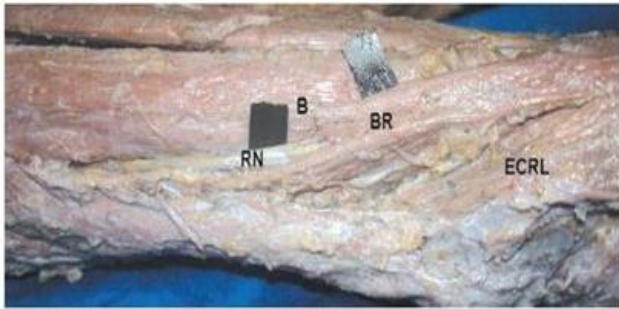
imaging) finding in radial tunnel syndrome are muscle denervation edema or atrophy along the distribution of the PIN [4,5].

CASE REPORT

The following variations were observed on the right side during routine dissection in an adult 34 year old male cadaver. Brachialis was giving additional head of origin for Brachioradialis close to its bony origin from humerus; thus making the radial nerve more vulnerable to compression proximal to and through its course in the radial tunnel (Fig. 1). Extensor carpi Radialis Brevis (ECRB) was absent, whereas extensor carpi radialis longus (ECRL) was giving two tendons in the second compartment of extensor retinaculum before its insertion while passing deep to the abductor pollicis longus (Fig. 2).

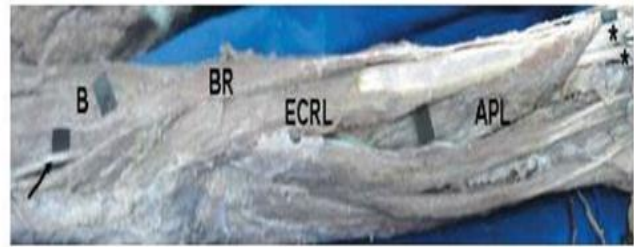


Figure 1. Brachialis was giving additional head of origin for Brachioradialis close to its bony origin from humerus



RN: Radial Nerve, B: Brachialis Muscle, BR: Brachioradialis Muscle, ECRL: Extensor Carpi Radialis Longus Muscle

Figure 2. Extensor carpi Radialis Brevis (ECRB) was absent, whereas extensor carpi radialis longus (ECRL) was giving two tendons in the second compartment of extensor retinaculum before its insertion while passing deep to the abductor pollicis longus



B: Brachialis Muscle, BR: Brachioradialis Muscle, ECRL: Extensor Carpi Radialis Longus Muscle, APL: Abductor Pollicis Longus Muscle

DISCUSSION

While dissecting the body of an 80-year-old female Claassen & Wree described variation of ECRL, which gave origin to an accessory head. The tendon of this accessory head passed through a separate tunnel in the extensor retinaculum and inserted in the middle of the first metacarpal bone [6]. On the contrary in the present case ECRL was passing as two tendons in the second compartment of extensor retinaculum before its insertion. Caetano et al. analysed the anatomical variations of the ECRL and ECRB in sixty male adults cadaver upper limbs and reported that the supernumerary tendons were found in 3 hands (all in relation to the ECRL tendon), whereas the presence of an accessory tendon making the union between the tendons of ECRL and ECRB was registered in 4 dissected hands [7]. Whereas in the present case, the ECRL received an additional head of origin from brachialis and divided into two tendons before insertion.

Sixty upper limbs from 30 Turkish subjects (18 males and 12 females) were dissected by Kirici & Irmak in 2004 to reveal the course of the PIN and to examine possible compression sites at the proximal and distal edges of the supinator muscle, and the exit of the nerve from the ECRB [8]. An anatomical study of 45 upper limbs, from 40 cadavers, was performed to analyse the relations between the medial edge of the ECRB and the PIN and it was suggested that the ECRB is a possible cause of PIN entrapment [9]. Here, the absence of ECRB in our case further increased the chances of PIN entrapment.

REFERENCES

- Hollinshead, W. H. Anatomy for Surgeons. (1969). The Back and Limbs. Vol 3. 2nd Ed. Harper and Row Publishers, New York, 428-41.
- Anson BJ & McVay CB. (1971). Surgical Anatomy, 5th ed. W.B. Saunders Company, Philadelphia, 1012-7.
- Prasartritha T, Liupolvanish P & Rojanakit A. (1993). A study of the posterior interosseous nerve (PIN) and the radial tunnel in 30 Thai cadavers. *J. Hand Surg. [Am]*, 18, 107-12.
- Ferdinand BD, Rosenberg ZS, Schweitzer ME, Stuchin SA, Jazrawi LM, Lenzo SR, Meislin RJ & Kiprofski K. (2006). MR imaging features of radial tunnel syndrome, initial experience. *Radiology*, 240, 161-8.
- Loh YC, Lam WL, Stanley JK & Soames RW. (2004). A new clinical test for radial tunnel syndrome-the Rule-of-Nine test, A cadaveric study. *J. Orthop. Surg. (Hong Kong)*, 12(1), S3-6.

Embryological Basis

In lower mammals the two extensor carpi radialis are represented by one muscle [10]. Anatomical variations always have underlying cause as developmental arrest in the different stages of gestation [11]. Ontogeny repeats phylogeny here, the pattern of muscular arrangement in this case can be said to be less evolved than the usual arrangement.

ACKNOWLEDGEMENT

The author is thankful to Dean Dr. Geeta Niyogi Madam for her support and also thankful to the Head of Department Dr. Sawant and all the staff members of the Department of Anatomy. The author also acknowledges the immense help received from scholars whose articles are included as references in this paper.

CONFLICT OF INTEREST

The authors declare that they have no conflict of interest.

STATEMENT OF HUMAN AND ANIMAL RIGHTS

All procedures performed in human participants were in accordance with the ethical standards of the institutional research committee and with the 1964 Helsinki declaration and its later amendments or comparable ethical standards. This article does not contain any studies with animals performed by any of the authors.



6. Claassen H & Wree A. (2002). Multiple variations in the region of Mm. extensores carpi radialis longus and brevis. *Ann. Anal*, 754, 489-91.
7. Caetano FM, Albertoni MW, Caetano BE & Pérez MR. (2004). Anatomical study of insertions of the extensor carpi radialis longus and brevis. *Int. J. Morphol*, 22(4), 245-51.
8. Kirici Y & Irmak MK. (2004). Investigation of two possible compression sites of the deep branch of the radial nerve and nerve supply of the extensor carpi radialis brevis muscle. *Neurol. Med. Chir. (Tokyo)*, 44, 14-9.
9. Laulan J, Daaboul J, Fassio E & Favard L. (1994). The relation of the short radial extensor muscle of the wrist with the deep branch division of the radial nerve. Its significance in the physiopathology of elbow pain. *Ann. Chir. Main Memb. Super*, 13, 366-12.
10. Bergman RA, Thompson SA, Afifi AK & Saddeh FA. (1988). *Copendium of Human Anatomical Variation*. Urban and Schwarzenburg, Baltimore, 138-9.
11. Sharadkumar et al. (2012). A case report on variant extensor carpi radialis longus giving two tendons and absent extensor carpi radialis brevis. *International Journal of Research and Reviews in Pharmacy and Applied Sciences*, 2(6), 1079-1084.

