



Journal homepage: www.mcmed.us/journal/ijacr

MUCOSAL VENOUS MALFORMATIONS OF THE BUCCAL MUCOSA TREATED WITH SODIUM TETRADECYL SULFATE

Sathyanarayanan R¹, Manoharan D², Manoharan K², R.G.Sharada³, Soorya B³,
Jayakar Thomas^{4*}

Assistant Professor ¹, Professors ², Junior Resident ³, Professor and Head 4, Department of Dermatology, Sree Balaji Medical College and Hospital, Bharath University, Chennai 600044, Tamilnadu, India.

Corresponding Author: - **Jayakar Thomas**
E-mail: jayakarthomas@gmail.com

<p>Article Info Received 15/12/2015 Revised 27/12/2015 Accepted 12/02/2016</p> <p>Key words: Venous malformations, 3% Sodium tetradecyl sulphate</p>	<p>ABSTRACT Venous malformations of the head and neck region are difficult to manage. Sclerosing agents like hypertonic saline, polidocanol, ethanol, sodium tetradecylsulfate are used in the management of these lesions. Here we report a case of cutaneous and mucosal venous malformations treated with 3% sodium tetradecylsulfate. Percutaneous 3% sodium tetradecylsulfate is a safe, effective and inexpensive modality of treatment for the treatment of vascular malformations. However proper planning and case selection are requisites for management of these patients to minimise the risks and complications associated with it.</p>
--	--

INTRODUCTION

Vascular anomalies can be congenital and acquired. They are described below congenital vascular anomalies: The most common anomalies are the vascular malformations. Vascular malformations are classified into arterio-venous malformations, venous malformations and lymphatic malformations. Arterial malformations are fast flow lesions whereas venous, lymphatic and capillary malformations are slow flow lesions. Malformations are a result of erroneous vasculogenesis during embryonic life.

Acquired vascular anomalies:

The most significant of these anomalies are hemangiomas. They are composed of proliferating blood vessels with a potentially destructive nature. They undergo a proliferative and involution phase. Other acquired vascular anomalies of minor esthetic significance are pyogenic granuloma, cherry angiomas and spider angiomas.

CASE REPORT: A 19 year old boy presented to our outpatient department with history of multiple raised dark

colour skin lesions and raised red coloured lesions over the tongue and oral cavity since 10 years of age. Patient alleges to have been doing well before the onset of these complaints. He gives history of increase in size of these lesions till 12 years of age after which it had not progressed in size. The lesions are associated with pain. He gives history of occasional bleeding from the lesions over tongue & some of the skin lesions. There is no history of bleeding diathesis or sudden increase in size with a woody feel suggestive of Kasabach-Merritt Phenomenon. There are no symptoms suggestive of congestive cardiac failure. Previously he was treated non-specifically for the above complaints by local general practitioners. He was born out of non-consanguineous marriage. No similar complaints were observed in the family members.

His general condition was normal. Dermatological examination revealed multiple skin-coloured to hyperpigmented papules, plaques and nodules of varying sizes, some with a smooth shiny surface seen over nose, both lips, left pinna, back and right axilla.



Figure 1. Lesions over the back

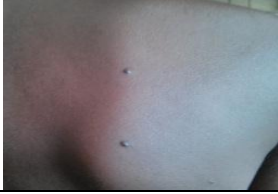

Figure 2. Lesions over the buccal mucosa

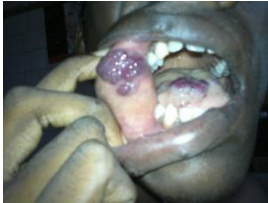
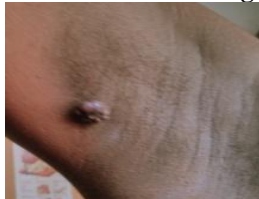

Figure 3. Lesions over the right axilla



Oral mucosal examination revealed lobulated, round to oval mass of size 3 x 2 cm size studded with numerous red coloured papules seen over the dorsal aspect of tongue. Similar smaller lesion seen over the posterior 1/3rd of tongue and inner aspect of right cheek and a similar lesion over the lower lip. Doppler ultrasound revealed heterogeneously hypoechoic lesion with slow-flow. D-dimer levels were elevated suggesting intravascular coagulation which is usually seen with venous malformations. Provisional diagnosis of slow flow venous malformations was made and Intralesional therapy with 3% sodium tetradecyl sulphate was planned.

Figure 4. Doppler ultrasound showing slow flow lesions

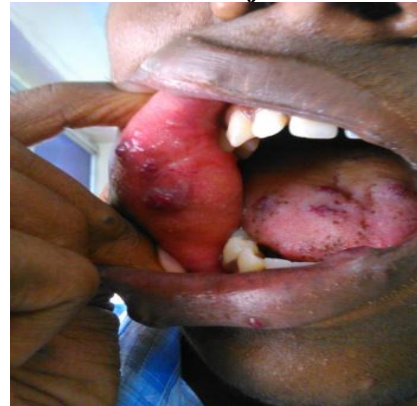

PROCEDURE

The patient was explained about the procedure. A test dose was given and found no signs of hypersensitivity. The area to be injected was cleansed with betadine and normal saline. 3% Sodium Tetradecyl Sulphate was injected directly into the lesion through the mucosa at multiple sites without any radiological guidance. In total, 1 ml of STS was mixed with 1cc of air and to and fro motion of the piston to create air bubbles. After withdrawal of the

needle, manual compression was given for 10 to 15 minutes over the lesion with sterile gauze. The patient was advised to take anti-inflammatory and analgesics and recalled after one month. In the second visit, the patient was reviewed with 50% reduction in the size of the lesion. In our case, the patient experienced transient severe pain postoperatively with minor complications. The patient was reviewed after one month and bimonthly interval, found the complete absence of the lesion and no evidence of recurrence.

Figure 5. Resolution of mucosal lesions following sclerosant injection



DISCUSSION AND CONCLUSION

The diagnosis of vascular malformations is based on the patient's medical history and a physical examination [1]. Vascular low flow lesions may present a progressive increase with age, trauma, and after partial resection. Ectatic blood vessels and the reddish-blue surface are characteristically found in this lesion. Change on pressure is a common finding with return to original color on withdrawal of pressure [2]. We believe that our case corresponds to vascular low flow malformation due to their reddish-purple aspect, consistence, response to diascopy, and the absence of vascular pulsation [3].

The appropriate combination of noninvasive to minimally invasive tests should follow in order to confirm or exclude the clinical impression. Duplex ultrasound scanning is the first choice for noninvasive evaluation of patients with vascular malformations [4], Doppler mode to assess flow characteristics [5]. Minimally invasive tests such as MRI [6] and MRV [7] are useful to confirm the extent and type of venous malformations, delineates feeding and draining vessels, distinguishes between different soft tissues (muscle, fat) and the vascular structures. Sclerotherapy, the mainstay of treatment is the injection of an agent to induce inflammation and obliteration of affected veins. For small cutaneous or mucosal lesions, local injection may be effective. Intralesional sclerotherapy using liquid sclerosing agents, which is a palliative treatment in most types of vascular anomalies, produces good outcomes in smaller lesions [8].

Sclerosing agents can be classified as [9]

Detergents

Which disrupt vein cellular membrane.

- Sodium tetradecyl sulfate
- Polidocanol
- Sodium morrhuate
- Ethanolamine oleate

Osmotic agents

Damage the cell by shifting the water balance through cellular gradient (osmotic) dehydration and cell membrane denaturation

- Hypertonic sodium chloride solution
- Sodium chloride solution with dextrose

Chemical irritants

Damage the cell wall by direct caustic degradation of vascular endothelium

- Chromated glycerin
- Polyiodinated iodine

STS at low concentrations are effective in stripping endothelium over a considerable distance, and is

also able to induce a hypercoagulable state, possibly by selective inhibition of protein C, and can also promote platelet aggregation. We selected 3% STS as a sclerosing agent because of its high effectiveness and minor complications like the presence of small skin ulcers and superficial skin breakdown which responded well to the application of silver sulfadiazine [10]. Intralesional sclerotherapy can be performed without serious complications if the sclerosing agent is selected and injected cautiously.

ACKNOWLEDGEMENT: None

CONFLICT OF INTEREST:

The authors declare that they have no conflict of interest.

STATEMENT OF HUMAN AND ANIMAL RIGHTS

All procedures performed in human participants were in accordance with the ethical standards of the institutional research committee and with the 1964 Helsinki declaration and its later amendments or comparable ethical standards. This article does not contain any studies with animals performed by any of the authors.

REFERENCES

1. Mulliken JB, Glowacki J. (1982). Hemangiomas and vascular malformations in infants and children, A classification based on endothelial characteristics. *Plast Reconstr Surg*, 69, 412-22.
2. Patrice SJ, Wiss K, Mulliken JB. (1991). Pyogenic granuloma (lobular capillary hemangioma), a clinicopathologic study of 178 cases. *Pediatr Dermatol*, 8, 267-76.
3. Redondo P. (2004). Classification of vascular anomalies (tumours and malformations). Clinical characteristics and natural history. *An Sist Sanit Navar*, 27S(1), 9-25.
4. Lee BB, Mattassi R, Choe YH, Vaghi M, Ahn JM, Kim Di *et al.* (2005). Critical role of Duplex ultrasonography for the advanced management of a venous malformation. *Phlebology*, 20, 28-37
5. Timmerman D, Wauters J, Van Calenbergh S, Van Schoubroeck, Maleux G, Van Den Bosch T, *et al.* (2003). Color doppler imaging is a valuable tool for the diagnosis and management of uterine vascular malformations. *Ultrasound Obstet Gynecol*, 21, 570-7.
6. Smith JK, Castillo M, Wilson JD. (1995). MR characteristics of low flow facial vascular malformations in children and young adults. *Clin Imaging*, 19, 109-17.
7. Yonetsu K, Nakayama E, Miwa K, Tanaka T, Araki K, Kanda S, *et al.* (1993). Magnetic resonance imaging of oral and maxillofacial angiomas. *Oral Surg Oral Med Oral Pathol*, 76, 783-9.
8. Goldman MP, Bennet RG. (1987). Treatment of telangiectasia, A review. *J Am Acad Dermatol*, 17(2 Pt 1), 167-82.
9. Parsons ME. (2004). Sclerotherapy basics. *Dermatol Clin*, 22, 501-8.
10. Gomes AS. (1994). Embolization therapy of congenital arteriovenous malformations, Use of alternate approaches. *Radiology*, 190, 191-8.