



## INTRAUTERINE JEJUNO-JEJUNAL INTUSSUSCEPTION LEADING TO JEJUNAL ATRESIA IN A NEONATE: A RARE CAUSE OF INTESTINAL OBSTRUCTION

Sonia Kundu <sup>1\*</sup>, Surekha Bhalekar <sup>2</sup>, Anita Sharan <sup>2</sup>, Prakash Roplekar <sup>3</sup>, Neha Shah <sup>4</sup>,  
Ekta Pramjit <sup>4</sup>

<sup>1,4</sup> Resident - Department of Pathology, D Y Patil University School of Medicine, Navi Mumbai, Maharashtra, India.

<sup>2</sup> Asso.Professor, Department of Pathology : D Y Patil School of Medicine, Navi Mumbai, Maharashtra, India.

<sup>3</sup> Head of the Department, Department of Pathology, D Y Patil School of Medicine, Navi Mumbai, Maharashtra, India.

Corresponding Author:- **Sonia Kundu**

**E-mail:** [sonia.kundu3@gmail.com](mailto:sonia.kundu3@gmail.com)

### Article Info

Received 23/12/2015

Revised 30/12/2015

Accepted 07/01/2016

### Key words:

Intrauterine  
intussusception,  
Jejunal atresia,  
Jejuno-Jejunal  
intussusception,  
Neonatal intestinal  
obstruction.

### ABSTRACT

One of the rarest known causes of Jejunal atresia (JA) is Intra uterine intussusception (IUI). Less than 1.3% of all cases of intussusception occur in term neonates. The commonest site of IUI is Ileum, Jejunum being uncommon. Intussusception in Premature Neonates (IPN) is very rare. Its rarity results in difficulty to differentiate it from more common neonatal diseases like Necrotizing Entero Colitis (NEC) which often delays its diagnosis and sometimes leads to mismanagement also. We report on a three day old neonate presenting with features of intestinal obstruction with Jejunal atresia. Histopathological examination confirmed the Jejuno-jejunal intussusception as the cause of Jejunal atresia. The relevant literature has been reviewed.

### INTRODUCTION

Intra uterine intussusception (IUI) is described as a rare cause of intestinal atresia. An extensive review of world literature revealed less than 100 cases of this association till date. Of about 6000 published cases of intussusceptions in the pediatric population, only 28 occurred in the neonatal period [1]. Intussusception in neonates is very rare [2].

Intestinal obstruction in neonatal period can be due to abnormalities of peristalsis, intrinsic developmental defects, or abnormal intestinal contents. We present a rare case of a three day old male neonate with Jejuno-Jejunal intussusception leading to Jejunal atresia.

### CASE REPORT

A three day old full term male neonate, born to a

twenty year-old primigravida delivered through normal vaginal delivery at hospital presented at second day of life with bilious vomiting and progressive abdominal distension and not having passed meconium since birth. The mother had a consanguineous marriage and did not receive regular antenatal care. One prenatal ultrasound was done at 24 weeks which was normal. His general condition was poor.

A clinical diagnosis of intestinal obstruction was made which was confirmed by plain abdominal radiographs. Ultrasonography showed Jejunal atresia but no intussusception. Patient was operated and intestinal specimen was sent for histopathological examination.

Grossly it showed gangrenous small intestine

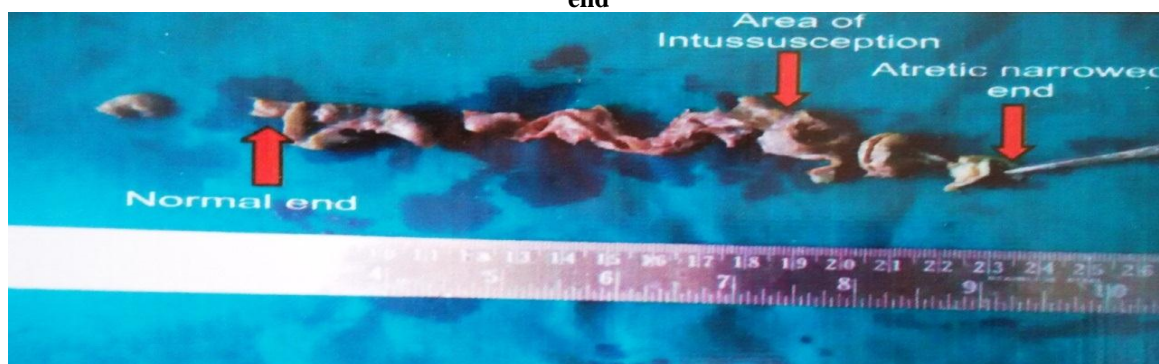


segment measuring 18 cm in length. External surface was unremarkable with attached mesentery and fibro fatty tissue. Distal end was obliterated with narrowing of lumen altogether measuring 3 cm in length and 0.2 cm in diameter. Proximal to the narrowed part, dilatation of lumen was seen measuring 0.8cm in diameter. Cut section showed a small tubular mass of 0.7 centimeter in length (intussusceptum) projecting into the lumen of the dilated portion (intussusciens) just proximal to the narrowing part. Intussusception area was 14 cm from proximal end and 3 cm from narrowed and obliterated distal end (Figure

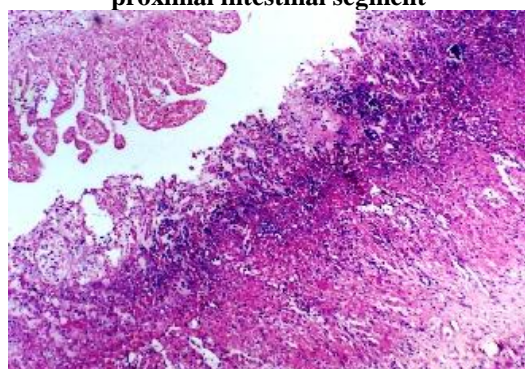
1). So IUI was revealed only on histopathological examination

Microscopically, sections studied from atretic jejunal intestinal segment showed all the four layers with normal histomorphological features. Sections from proximal segment showed ischaemic necrosis of mucosa and submucosa with mixed inflammatory cell infiltrate in all four layers up to serosa (Figure 2, 3). So final diagnosis made was Jejunal atresia secondary to Jejunum-jejunal intussusception along with ischaemic infarction of proximal segment.

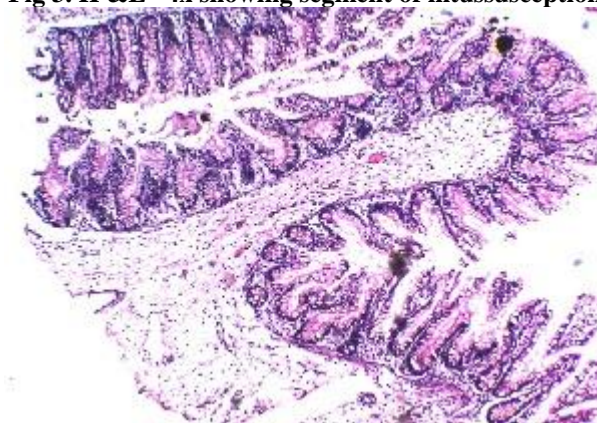
**Fig 1. Gross specimen showing normal proximal end of intestine, area of intussusception and atretic narrowed distal end**



**Fig 2. H& E 10x showing necrosis of mucosa and submucosa and mixed inflammatory cell infiltrate in proximal intestinal segment**



**Fig 3. H & E 4x showing segment of intussusception**



## DISCUSSION

Intussusception is the one of the most common causes of intestinal obstruction between 6–18 months of age but it is rarer in neonates, especially among premature infants. It accounts for only 3% of intestinal obstruction and 0.3% of all cases of intussusceptions [2].

Ileo colic junction is the commonest level of Intussusception in full-term neonates, infancy and childhood. Small bowel intussusception occurs in less than 10% in all age groups but is very common in premature neonates particularly in the ileum. Intrauterine intussusception causing Jejunal atresia is even rarer with only occasional cases reported in the literature [3].

The cause of the intussusception is idiopathic in majority of the cases. Mid and low Jejunal and ileal

intussusception mostly occur as a result of intrauterine vascular disruption(s) in a part of the developed intestine that leads to decreased intestinal perfusion and ischemia of the respective segment of bowel. This ultimately results in narrowing, or in the most severe cases, complete obliteration of the intestinal lumen. This condition usually occurs very late in pregnancy, which is supported by presence of near-normal or normal sized colon due to passage of meconium in majority of these neonates and absence of associated anomalies [1, 3, 7]. These disruptive intrauterine events may include herniation, thrombosis of mesenteric vessels, volvulus, constriction, and rarely intussusception. Local vascular disruptive event, however, is not seen in patients with multiple atresias (MA) or apple-

peel atresia (APA)). Genetic, placental, or other causes have been speculated for APA and MA [4].

By prenatal Ultrasonography, IUI has rarely been detected after 25-30 weeks of pregnancy. Although there is no great role of fetal therapy if an antenatal diagnosis of IUI is made, but an early diagnosis would surely help in referral to a tertiary care hospital and early surgical intervention for better outcome [1, 5].

Pathologically, the lesion is similar to classic, idiopathic intussusceptions as seen in infants and older children. Rarely leading point such as Meckel's diverticulum has been reported [1, 6].

IUI resulting into JJA was not readily evident in our case as prenatal ultrasound done at 24 weeks was normal and so cause-effect relationship could not be established clinically. JJA was revealed only on histopathological examination. The present case reaffirms that IUI may occur at late stage of pregnancy causing blood supply impairment to a segment of intestine leading to its resorption and atresia.

The presenting symptoms for patients with any form of intestinal atresia or stenosis are consistent with bowel obstruction and include bilious vomiting, abdominal distension, and failure to pass meconium in instances of lower obstruction. Most infants with duodenal obstruction do not have significant abdominal distension.

Based on the location of the obstruction, the classification of intestinal atresias varies. Duodenal lesions have been classified with 3 types of lesions. A type I defect represents a mucosal web with normal muscular wall (most common); type II, a short fibrous cord connecting the 2 atretic ends of the duodenum; and type III (least common), one in which there is complete separation of the atretic ends. The classification of jejuno-ileal atresia includes type I defect which shows a mucosal defect with an intact mesentery. Type II defects consist of a fibrous cord

connecting the atretic bowel ends. A type IIIa lesion denotes an atretic segment with a V-shaped mesenteric gap defect, while type IIIb defines the apple peel deformity, in which there is a proximal jejunal atresia and the distal bowel is supplied by a single retrograde blood vessel. Type IV describes instances of multiple atresias ("string of sausage" effect). This classification system has also been applied to colonic atresia, with most of those cases demonstrating a type IIIa defect

Being an extremely rare clinical entity, intussusception in neonates is usually confused with other causes of intestinal obstruction and intestinal distention mostly with NEC (Necrotizing enterocolitis). [2] Other causes of intestinal obstruction are duodenal or small intestinal atresia or stenosis, malrotation, meconium ileus, meconium plug syndrome, anorectal malformations, Hirschsprung's disease, ileus related to sepsis, and other rare causes. So a high degree of suspicion may be needed to avoid the misdiagnosis.

## CONCLUSION

Neonatal intestinal obstruction is an acute emergency with varied etiology. Intrauterine Jejuno-Jejunal intussusception leading to Jejunal atresia in neonates is extremely rare. So it will often be confused with other common causes of intestinal obstruction and intestinal distention leading to the misdiagnosis and mismanagement. From all these conditions, it is very important to dissociate NEC, a condition which can be cured conservatively in most of the cases.

**ACKNOWLEDGEMENTS:** None

## CONFLICT OF INTEREST:

The authors declare that they have no conflict of interest.

## REFERENCES

1. Sarin YK. (2010). Intrauterine Intussusception Causing Ileal Atresia. *APSP Journal of Case Reports*, 1(2), 18.
2. Loukas N, et al. (2009). Intussusception in a Premature Neonate: A Rare Often Misdiagnosed Cause of Intestinal Obstruction. *Case Reports in Medicine*, 3, 200.
3. Parelkar SV, Sanghvi BV, Vageriya NL, Paradkar B, Samala DS, Oak SN. (2009). Neonatal jejunal polyp with jejunojejunal intussusception causing atresia: A novel cause. *Journal of Pediatric Surgery Case Reports*, 2(2), 73-75.
4. Komuro H, Hori T, Amagai T, Hirai M, Yotsumoto K, Urita Y, et al. (2004). The etiologic role of intrauterine volvulus and intussusception in jejunoileal atresia. *J Pediatr Surg*, 39, 1812-4.
5. Yang JI, Kim HS, Chang KH, Hong J, Joo HJ, Ryu HS. (2004). Intrauterine intussusception presenting as fetal ascites at prenatal ultrasonography. *Am J Perinatol*, 21, 241-6.
6. Lin CH, Wu SF, Lin WC, Chen AC. (2007). Meckel's diverticulum induced intrauterine intussusception associated with ileal atresia complicated by meconium peritonitis. *J Formos Med Assoc.*, 106, 495-8.
7. Todani T, Tabuchi K, Tanaka S. (1975). Intestinal atresia due to intrauterine intussusception: analysis of 24 cases in Japan. *J Pediatr Surg.*, 10, 445-51.

