



PLUNGING RANULA: DIFFICULT AIRWAY AND ANAESTHETIC MANAGEMENT

Neha Chandrakar^{1*}, C. P. Bhagat², K.K. Sahare³, Neha Bhagwat⁴

¹Senior Registrar, ²Assistant Professor, ³Professor and Head of Department, ⁴Post Graduate Student,
Department of Anaesthesiology and Critical Care, Dr. B.R.A.M. Hospital, Raipur, Chhattisgarh, India.

Corresponding Author:- **Neha Chandrakar**
E-mail: nehachandrakargmc@gmail.com

<p>Article Info Received 15/11/2015 Revised 27/11/2015 Accepted 15/12/2015</p> <p>Key words: Ranula, Fiberoptic intubation, Difficult airway.</p>	<p>ABSTRACT A ranula is a type of mucus extravasation cyst (mucocele) found on the floor of the mouth and can extend into the submandibular, submental, retropharyngeal spaces, lateral aspect of the neck and upper mediastinum which may pose potential airway obstruction which leads to difficulty in airway management. A 28 year old female weighing 57 kg visited our hospital in the ENT department with a painless huge, tense swelling in the submental region with complains of dysphagia and discomfort due to the mass.. Mouth opening was three fingers and Mallampati grading was IV. Excision of ranula was planned under general anesthesia after awake fiberoptic nasal intubation as the first line of airway management, keeping tracheostomy standby. Mass was resected by cervical and oral approach and intraoperative course was uneventful. Patient was extubated fully awake and postoperatively she was hemodynamically stable. Airway management of patients with neck swelling is always challenging for the anesthetists. A strategy needs to be developed in order to anticipate & manage patients with difficult airway. This includes identifying the potential problems, considering different options selection of an appropriate plan in the particular scenario. The Flexible fiberoptic endoscope is the most valuable single tool available for the anaesthesiologist to manage the difficult airway.</p>
---	---

INTRODUCTION

A ranula is a type of mucus extravasation cyst (mucocele) found on the floor of the mouth. Ranulas have a prevalence of about 0.2 cases per 1000 persons and accounts for 6% of all oral sialocysts. It usually presents as a translucent blue, dome-shaped, fluctuant swelling in the tissues of the floor of the mouth. A cervical ranula presents as a swelling in the neck, with or without a swelling in the mouth. These ranulas can burrow into the submandibular, submental, retropharyngeal spaces, lateral aspect of the neck and upper mediastinum which may pose potential airway obstruction which leads to difficulty in airway management.

CASE REPORT:

A 28 year old female weighing 57 kg visited our hospital in the ENT department with a painless huge, tense swelling in the submental region with complains of

dysphagia and discomfort due to the mass. Swelling was present since 6 years and progressively increased in size. It extended from the floor of the mouth to the submental region and occupied the anterior part of the neck upto the thyroid cartilage.

X-ray showed soft-tissue shadow in upper part of the neck. There was no tracheal compression and deviation. High resolution USG of the neck reported a well-defined dumbbell shaped isoechoic cystic lesion seen in the midline of upper neck just above the thyroid, measuring 66x53x63mm in dimensions. It suggested retention cyst with old internal haemorrhage. Her temperature, pulse, blood pressure & respiratory rate were within normal limits. Her respiratory and cardiovascular systems were also normal.

Air way assessment



Mouth opening was three fingers. Thyromental distance could not be assessed due to the position of the swelling. The intraoral part of the mass was extending more toward the right, deviating the tongue towards left and making the uvula and soft palate invisible thus graded as Mallampati IV. Neck movements were slightly restricted. Both the nostrils were patent as checked by using a cotton wisp.

Routine investigations were within normal limit including complete blood counts, serum investigations, bleeding time, coagulation time and PT/INR. Excision of ranula was planned under general anesthesia after awake fiberoptic nasal intubation as the first line of airway management, keeping tracheostomy standby.

Patient was kept NPO overnight. Intravenous cannulation in the operating room using a 20G canula was done. Inj. Glycopyrrolate 0.2 mg was given im. 30 minutes before induction. Premedication was done with ranitidine-50mg and ondansetron-4mg.

Patient was nebulized with 5 ml of 4% lidocaine solution to anesthetize the airway. Superior laryngeal and intratracheal blocks were not possible due to the swelling. Transmucosal topical application of lignocaine with

adrenaline soaked nasal packs was done. Xylometazoline drops were administered in both the nostrils.

Patient was placed supine in sniffing position and Phillips MP30 multipara monitor was attached. Preoxygenation was done with 100% oxygen. A 6.5 mm well lubricated polyvinyl chloride cuffed endotracheal tube (ETT) was introduced gently through nasal route into the trachea visualized using a fiberoptic bronchoscope and fixed after confirming the position by capnography and chest auscultation. Inj. Dexmedetomidine 50microgm, Inj. Midazolam 1.5mg & Inj fentanyl 50mcg iv was given. Induction was done with Inj Propofol (2mg/kg). Throat pack was inserted.

Anesthesia was maintained with oxygen, nitrous oxide (60:40) and isoflurane MAC 1. Neuromuscular blockade was maintained with Inj. Atracurium. The patient remained haemodynamically stable and well oxygenated throughout the procedure.

Mass was resected by cervical and oral approach and intraoperative course was uneventful.

Patient was extubated fully awake and postoperatively she was hemodynamically stable. Recovery was uneventful and she was discharged after 10 days.

Figure 1. Intra-oral view of ranula

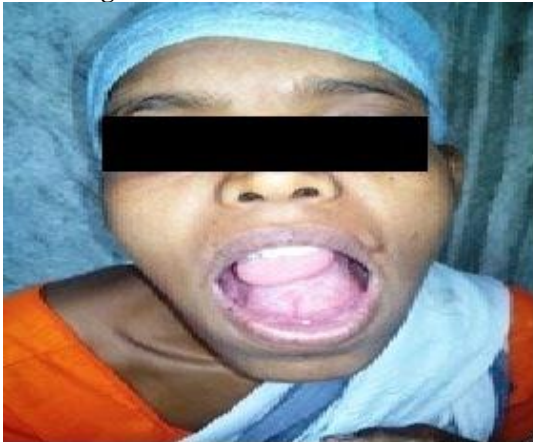

Figure 2. External view of ranula

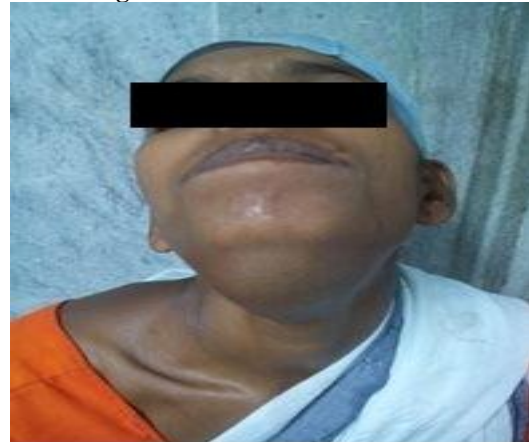

Figure 3. Ranula after excision

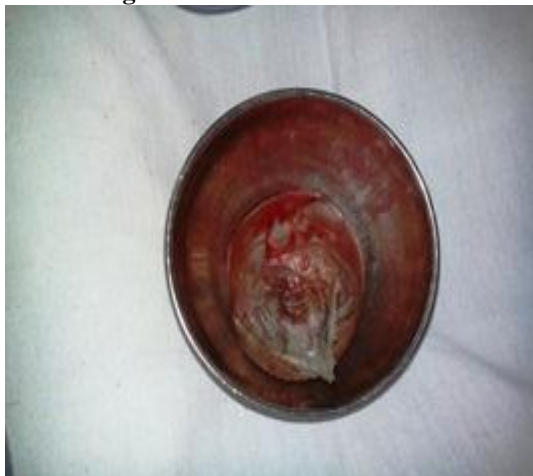
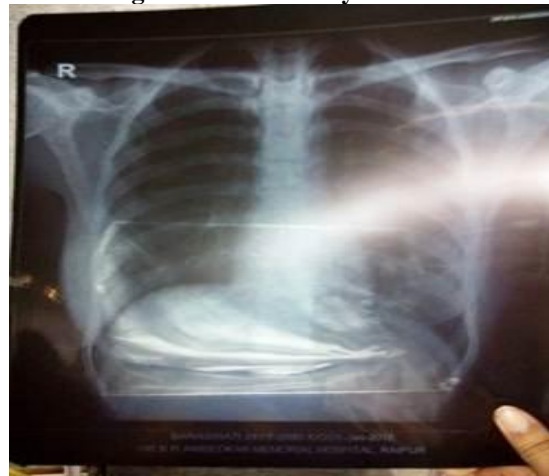
Figure 4. Chest X-ray PA view



DISCUSSION

A ranula by definition is a mucus filled cavity, a mucocele, in the floor of the mouth in relation to the sublingual gland. The name “ranula” has been derived from the Latin word “rana” which means “frog.” The most common site is the lateral floor of the oral cavity. Ranulas usually occur in children and young adults, with the peak frequency in the second decade. The cervical variant tends to occur a little later in the third decade. The diagnosis of a plunging ranula is usually determined by a combination of history, clinical presentation, and imaging studies.

Differential diagnosis of cervical ranula must include thyroglossal cyst, branchial cleft cyst, cystic hygroma, submandibular sialadenitis, intramuscular hemangioma, cystic or neoplastic thyroid disease, hematoma, lipoma, laryngocele, and dermoid cyst [1].

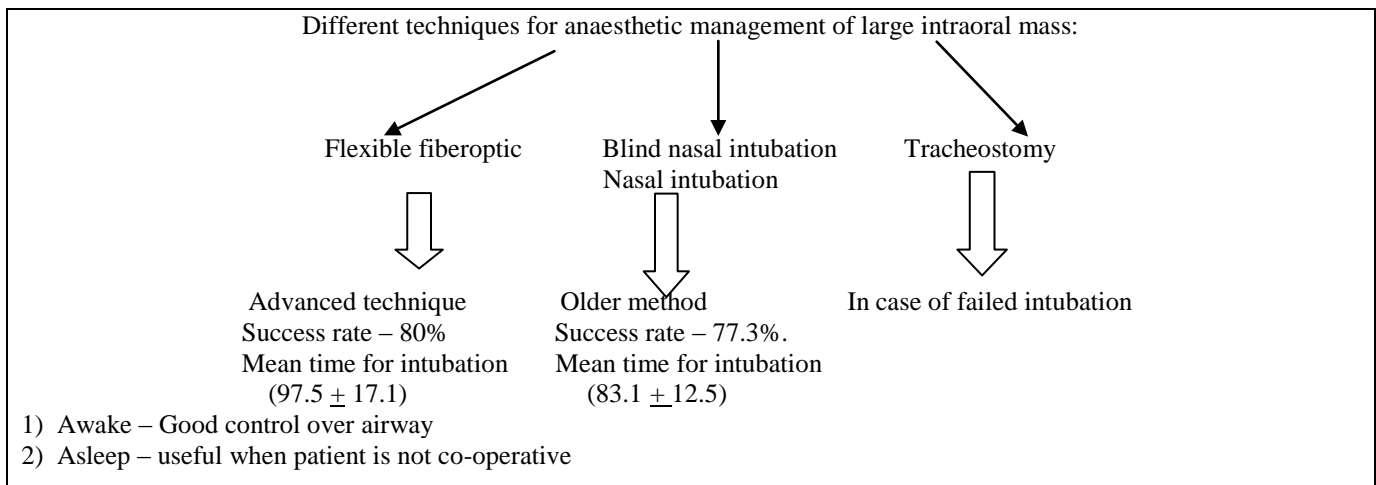
The most common cause of mortality and serious morbidity due to anaesthesia is from airway problems. It is estimated that about one-third of all anaesthetic deaths are due to failure to intubate and ventilate. Airway management of patient with neck swelling is always challenging for the anaesthetist. A strategy needs to be developed in order to anticipate & manage patients with difficult airway. This includes identifying the potential problems, considering different options & selection of an appropriate plan in the particular scenario. This case report describes a case of difficult intubation in which we use

fiberoptic bronchoscope to successfully intubate the patient [2].

Difficulties in cases of intraoral mass are:

- Difficult mask ventilation
- Difficult laryngoscopy and oral intubation
- Risk of trauma to the mass and bleeding
- Difficulty to perform trans-tracheal and superior laryngeal nerve Block
- Difficulty in placement of supraglottic airway device.

The Flexible fiberoptic endoscope is the most valuable single tool available for the anaesthesiologist to manage the difficult airway. Flexible fiberoptic bronchoscopy is very useful for the anaesthesiologist in the management of difficult tracheal intubations, evaluation of the upper airway, confirmation of endotracheal tube placement, repositioning or checking patency of endotracheal tubes, changing endotracheal tubes, placement of double lumen tubes and placement of endobronchial blockers. Dr.P.Murphy was the first to use a fiberoptic instrument for the control of airway when he performed a nasal intubation under general anaesthesia for a patient with advanced still’s disease using choledochoscope. Fiberoptic endotracheal intubation is a useful technique in a number of situations. It can be used when the patient's neck cannot be manipulated, as when the cervical spine is not stable.



It can also be used when it is not possible to visualize the vocal cords because a straight line view cannot be established from the mouth to the larynx. It can be performed in cases of restricted mouth opening as in TM joint ankylosis, facial trauma, or in cases as described above having soft tissue mass occupying the oral cavity making direct laryngoscopy difficult. Fiberoptic intubation can be performed either awake or under general anesthesia and it can be performed either as the initial management of a patient known to have a difficult airway, or as a backup technique after direct laryngoscopy has been unsuccessful.

It can be performed orally as well as by nasal route. As with all other procedures, the keys to the success of this technique involve adequate planning and patient preparation [3].

Fiberoptic intubation via nasal route is usually easier and has a higher success rate compared with an oral approach. This approach is also useful in dental and maxillofacial procedure and in temporomandibular ankylosis. The main advantage of nasal approach is a straight route to larynx and trachea and the endotracheal tube passes more easily. Another benefit of the nasal



approach is the stability of the endotracheal tube once it has been secured in position. The main problem of nasal intubation is bleeding which can make the intubation difficult. We chose the technique of fiberoptic intubation via nasal route as it is available in our hospital as compared to management of a similar case by blind nasal route as described by Sheet, *et al.* Fiberoptic bronchoscopy requires a clear visual pathway. Blood and secretions prevent visualization of the laryngeal structures. Administration of an antisialogogue prior to the start of the procedure is therefore essential. In the average adult patient, 0.2 mg of glycopyrrolate is given in 1 hour prior to bronchoscopy.

Proper airway anesthesia is essential to a successful fiberoptic intubation. In addition, topical anesthesia of the airway increases patient comfort, decreases the response to intubation, and increases the probability of success. The patient's nasal passages should be treated with a topical vasoconstrictor to shrink the nasal mucosa. This makes the endotracheal tube easier to pass and minimizes the risk of bleeding. The nasal mucosa can be anesthetized and vasoconstricted with either a mixture of lidocaine and phenylephrine (1 cc phenylephrine 1% in 3 cc lidocaine 4% provides anesthesia and vasoconstriction with minimal hemodynamic effects). The topical anesthetic / vasoconstrictor solution is applied with pledgets or cotton-tipped applicators. The applicators are gently inserted into each nostril and gently advanced until they reach the posterior wall of the nasopharynx. Alternatively, the solution can be dripped in using a 20 gauge intravenous catheter or sprayed using an atomizer. The mouth can be anesthetized with lidocaine spray or viscous lidocaine.

In this case trans-tracheal and superior laryngeal nerve blocks couldnot be performed because of the distorted anatomical landmarks due to the neck swelling. For nasal intubation, a small endotracheal tube (7 mm for a normal adult) should be used. Prior to insertion, the tube can be softened by soaking in warm saline, and well-lubricated with lidocaine jelly. The bronchoscope is inserted into the nare, care being taken to stay between the nasal turbinates and septum. Trauma to these structures can cause significant bleeding which can obstruct view of the vocal cords. The scope is passed carefully through the

nasal passages and key anatomic structures should be visualized. The nasal cavity eventually leads to the posterior pharynx and the tracheal inlet is visualized. This view is what is seen during oral FOI and once the scope is passed through the vocal cords to the carina the ETT can be passed over the scope and its position confirmed. The endotracheal tube often gets stuck on the arytenoid cartilages. If the endotracheal tube meets resistance, pull the endotracheal tube back slightly, rotate the tube 90-180 degrees, and advance it again. Confirm tube placement with an adequate end-tidal carbon dioxide monitor reading, auscultation of breath sounds, and misting of the tube with ventilation.

CONCLUSION

Airway management of patients with neck swelling and large intraoral mass is always challenging for the anesthetists. A strategy needs to be developed in order to anticipate & manage patient with difficult airway which includes-

IDENTIFYING THE POTENTIAL PROBLEMS

Considering different options

Selection of an appropriate plan

The Flexible fiberoptic intubation is the gold standard for management of airway in such cases. Our case has been reported to highlight the anticipated airway difficulty and how it was successfully overcome and manage.

ACKNOWLEDGEMENT: None

CONFLICT OF INTEREST

The authors declare that they have no conflict of interest.

STATEMENT OF HUMAN AND ANIMAL RIGHTS

All procedures performed in human participants were in accordance with the ethical standards of the institutional research committee and with the 1964 Helsinki declaration and its later amendments or comparable ethical standards. This article does not contain any studies with animals performed by any of the authors.

REFERENCES

1. Sheet J, Mandal A, Sengupta S, Jana D, Mukherji S, Swaika S. (2014). Anaesthetic management in a case of huge plunging ranula. *Anesth Essays Res*, 8(1),
2. Gupta A and Karjodkar FR. (2011). Plunging Ranula: A Case Report. *ISRN Dentistry*, 806928
3. Huda A, Hamid M. (2008). Airway Management in a Patient with Huge Neck Mass, Department of Anaesthesia, Aga Khan University Hospital, Karachi.
4. American Society of Anaesthesiologist. (2013). Inc. Lippincott Williams &Wilkins. *Anaesthesiology*, 118.
5. Moustafa AM, Nassef MA, Azim KA. (2005). Comparison between fibreoptic and blind nasotracheal intubation criteria in awake surgical patients. *Alexandria J Anaesth Intensive Care*, 8, 17-23.

