



## MIGRATION AND COILING OF LEFT INTERNAL JUGULAR CENTRAL VENOUS CATHETER IN LEFT SUBCLAVIAN VEIN, A RARE CASE

**Pradeep M. Venkategowda\*, Trishala Raj, Ashwini Murthy, Himaal Dev G Jayakumar**

Department of Critical Care Medicine, Apollo Hospital, Sheshadripuram, Bengaluru – 560020, Karnataka, India.

Corresponding Author:- **Pradeep M Venkategowda**

**E-mail:** [drpradeepmarur@gmail.com](mailto:drpradeepmarur@gmail.com)

<p><b>Article Info</b>  <i>Received 17/11/2015</i>  <i>Revised 23/11/2015</i>  <i>Accepted 30/11/2015</i></p> <p><b>Key words:</b>  Migration, Coiling,  Central venous  catheter, Jugular  vein, Subclavian  vein, complication.</p>	<p><b>ABSTRACT</b>  Central venous catheters (CVC) are commonly placed in patients requiring administration of vasopressors, antibiotics, blood products and parenteral nutrition. Although ultrasound has reduced complications associated with central venous catheter placement, the incidence of abnormal migration or coiling remains same.</p>
---	--

### INTRODUCTION

Central venous catheter placement using ultrasound guidance has replaced the standard blind technique, but it cannot prevent or rule out abnormal migration or coiling of the catheter. Migration of catheter can occur during insertion or later spontaneously but it is usually identified by absence of aspiration of blood through the catheter ports or on chest x-ray. This case report highlights a rare catheter migration and coiling of left IJV catheter in the left subclavian vein though there was backflow of blood even after coiling.

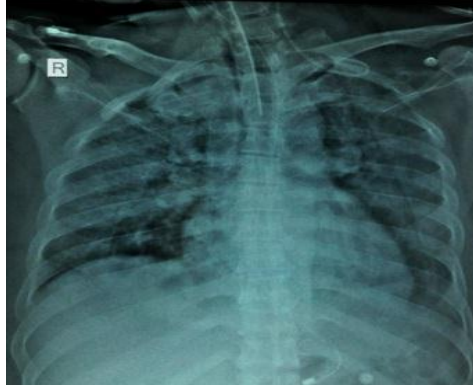
### CASE REPORT

A 54 years old male, without any comorbidities came to our tertiary hospital with history of fever and breathlessness since 3 days. Patient was initially evaluated in emergency room and later shifted to MICU for further management. On evaluation in MICU, patient was found to have severe breathlessness, altered sensorium, thrombocytopenia, acute kidney injury, hyperammonemia

and hypotension. In view of sepsis with septic shock a triple lumen right internal jugular central venous catheter was placed. After 5 days following placement, due to new onset of fever and redness at the site of insertion of the catheter, it was removed and left IJV triple lumen 7.5F (Arrow) catheter was placed using ultrasound guidance. The guide wire movement during insertion and removal was free and following placement of catheter the back flow was confirmed at all ports and fixed at 13 cm. Chest X-ray (AP view) showed that the catheter had migrated to left subclavian vein and coiled back. Later the kink was removed using push pull technique (In this technique, the guide wire will be passed through the distal port until we feel resistance, that is till the kink and later the catheter was slowly pulled out over guide wire with simultaneously pushing the guide wire. Once the guide wire has advanced freely up to 15cms then both catheter and guide wire were pulled out for 5-6cms and pushed slowly inside) and the correct position was confirmed by the repeat chest x ray.



**Fig 1. Showing the left IJV central venous catheter migrated and coiled in left subclavian vein**



## DISCUSSION

Ultrasound guided central venous catheter placement has become a standard practice in recent years. Ultrasound helps in safe and visible venous puncture but not in detecting malposition of the catheter following placement [1]. Malposition of catheter can occur during insertion or later due to spontaneous migration. Trans-esophageal echocardiography can accurately detect a CVP tip in relation to superior vena cava (SVC) and right atrium (RA) [2], but is not commonly used. Figure-1 showing the left IJV central venous catheter migrated and coiled in left subclavian vein.

The ideal position of the catheter tip after placement would be in distal third of superior vena cava (SVC). Right IJV cannulation is preferred as it is wider and longer compared to left IJV (smaller and has short course). The catheters which pass through left IJV have to pass through left brachiocephalic vein and enter SVC perpendicularly with distal tip impinging on the right lateral wall.

The incidences for catheter malposition are higher for internal jugular as compared to subclavian catheter. Left and right IJV access has malposition incidence of 4.12% and 1.1% respectively whereas left and right subclavian vein catheterization has 0.89% and 1.01% respectively. This incidence depends on site of insertion and type of material used, but not on the experience of the physician who does the procedure [3].

One of the reasons for coiling in the IJV is due to presence of valves. Normally valves helps in preventing retrograde flow from right atrium to the brain [4]. The blood aspirated freely from the catheter lumen after the placement of the catheter does not necessarily confirm a proper placement of the catheter tip [5]. Recently Munta et al [6] have suggested saline flush test to detect catheter migration at bedside. The onset of bubbles after 3 seconds

in the right atrium ( 10ml of saline was flushed through distal port of catheter and simultaneously observed the right atrium of heart by 4 chamber view in 2-D echo) following saline flush, can identify the possibility of catheter migration or coiling without any need of chest x-ray. A false CVP value and suboptimal waveform configuration even after checking for blockage in tubing can be suggestive of a malpositioned catheter tip [7].

Accuracy of catheter tip can be confirmed by CXR (less accurate), Fluoroscopy/C arm (98%), electrocardiogram guided CVC placement (95-100%) and trans-esophageal echocardiography (100%). In our patient the left IJV catheter had migrated and coiled in left subclavian vein which was corrected using a push pull improvised technique.

Though the malposition of central venous catheter placed through left IJV may be common as compared to right IJV catheter placement, the migration to left subclavian and coiling back is very rarely seen.

## STATEMENT OF HUMAN AND ANIMAL RIGHTS

All procedures performed in human participants were in accordance with the ethical standards of the institutional research committee and with the 1964 Helsinki declaration and its later amendments or comparable ethical standards. This article does not contain any studies with animals performed by any of the authors.

## ACKNOWLEDGEMENTS

We acknowledge management of the hospital for their valuable support.

## CONFLICT OF INTEREST

None declared.

## REFERENCES

1. Amshel CE, Palesty JA, Dudrick SJ. (1998). Are chest X-rays mandatory following central venous recatheterizations over wire. *Am Surg*, 64, 499-502.
2. Bankier AA, Mallek R, Wiesmayr MN, Fleischmann D, Kranz A, Kontrus M et al. (1997). Azygos arch cannulation by central venous catheters: Radiographic detection of malposition and subsequent complications. *J Thorac Imaging*, 12, 64-9.



3. Muhm M, Sunder-Plassmann G, Apsner R, Pernerstorfer T, Rajek A, Lassnigg A *et al.* (1997). Malposition of central venous catheters. Incidence, management and preventive practices. *Wien Klin Wochenschr*, 109, 400-5.
4. Furukawa S, Wingefeld L, Takaya A, Nakagawa T, Sakaguchi I, Nishi K *et al.* (2012). Morphological variations of the internal jugular venous valve. *Anat Physiol*, 2, 108.
5. Matthias Hohlrieder, Heinrich M. Schubert, Matthias Biebl. (2004). Successful aspiration of blood does not exclude malposition of a large- bore central venous catheter. *Can J Anaesth*, 51, 89-90.
6. Munta K, Venkategowda PM, Chaudhary JR, Rao SM, Amte R. (2015). Accidental placement of central venous tip into internal mammary vein. *Indian Journal of Critical Care Medicine*, 19, 365-366.
7. Agrawal P, Gupta B, D'souza N. (2010). Coiled central venous catheter in superior vena cava. *Indian J Anaesth*, 54, 351-2.

