



EXTENSIVE LUMBOSACRAL LIPOMA AND OCCULT SPINA BIFIDA: MANAGEMENT EXPERIENCE AND LITERATURE REVIEW

Benyachou Malika¹, Echchaoui Abdelmoughit¹, El Mazouz Samir¹, Gharib Nour-eddine¹,
Abbassi Abdellah^{1*}, Fathi Nahed²

¹The Department of Plastic Surgery and Burns, Ibn Sina University Hospital, Rabat, Morocco.

²The Department of Plastic Surgery, Hassan II regional Hospital, Agadir, Morocco.

Corresponding Author: **Abdelmoughit Echchaoui**

E-mail: e.moughit@hotmail.fr

Article Info	ABSTRACT
<p>Received 15/10/2015 Revised 27/10/2015 Accepted 19/11/2015</p> <p>Key words: Lumbosacral lipoma; Occult spina bifida; adult; Surgical management.</p>	<p>Lumbosacral lipoma associated with occult spina bifida is a very rare entity in adults, and many cases might be ignored due to their silent nature. Before any aesthetic intervention, clinical examination supplemented with neuro-imaging studies remains necessary to confirm the diagnosis and treat a possible associated occult spina bifida. We report a case of a 31-years-old girl presented in our department for liposuction of a large lumbosacral mass with occult spina bifida confirmed by Computed tomography (CT). Surgical management was carried out successfully by a multidisciplinary team involving neurosurgeons and plastic surgeons.</p>

INTRODUCTION

Lipomas are the most common neoplasm of mesenchymal origin and can arise anywhere in the body [1]. Lumbosacral lipomas are frequently associated with spinal dysraphisms (lumbar spina bifida occulta or aperta, meningo(myelo)coele); however; this combination is exceptional in adults [2]. They can cause significant aesthetic deformity of the lower body. Through this report we emphasize the importance of appropriate neuroimaging studies to rule out spinal dysraphisms particularly occult spina bifida before surgical management.

Case report

A 31-years-old girl presented in our department for liposuction of a large mass present since birth in the lumbosacral region with extension to the buttocks. Physical examination showed an extensive voluminous mass in the lumbosacral region that altered the physiological silhouette. The skin overlying the lesion appeared

normochromic and normotrophic, Palpation revealed a subcutaneous bulk, which was painless to the touch but fixed on the underlying planes (figure 1). Neurological examination was normal. Ultrasonography showed a large mass compatible with a subcutaneous lipoma Computed tomography demonstrated a large soft tissue mass with spina bifida (figure 2). Surgical management was performed by a combined team of plastic surgeons and neurosurgeons. Complete excision was performed successfully with closure of posterior arch of the neural tube the excess skin against the mass was resected. Histopathology was conclusive of spindle cell type of lipoma with occult spina bifida combined to spinal dermal sinus. The postoperative course was uneventful, the aesthetic result was very satisfactory (figure 3) and the patient left the hospital on the 8th postoperative day. There was no recurrence at ten months of follow-up.



Figure 1. Extensive lumbosacral lipoma with a preoperative schema

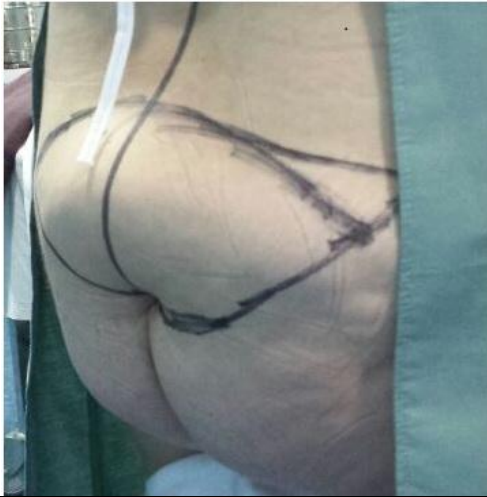

Figure 2. CT scan of the lumbosacral spine with spina bifida occulta

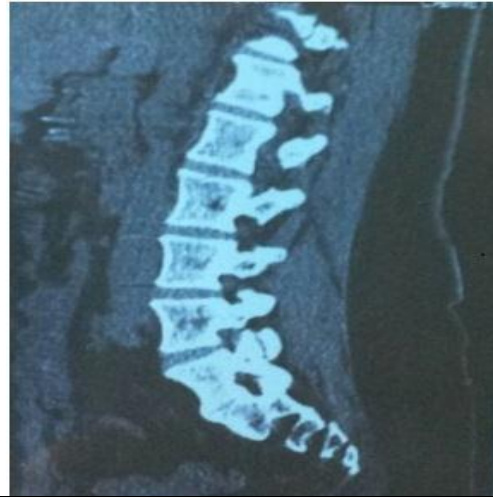
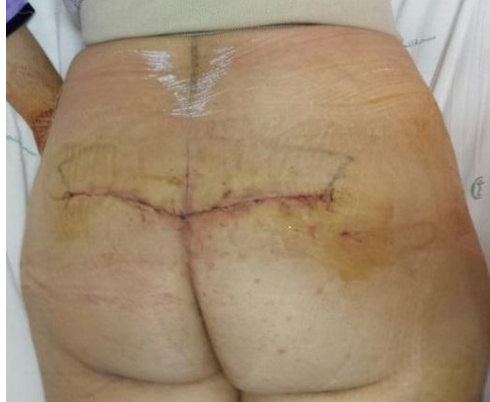

Figure 3. Postoperative appearance at 8th day. Good aesthetic result



DISCUSSION

Lipomas are the most common of benign soft tissue neoplasms occurring throughout the entire body [3]. The exact prevalence of lipomas is unknown and Most arise between 40 and 60 years of age [1]. They have a predilection for the trunk and are the most uncommon tumors of the abdominal wall Lipomas can be detected clinically when superficial or radiologically when deep [4]. lipomas with spinal dysraphism are exceptional and occurs mostly in a pediatric population [5]; these swelling fatty mass are commonly have continuation passing deeply to connect with the spinal cord [6]. Adults with spina bifida are at risk for secondary conditions such as pain, fatigue, injury, depression and obesity [7]. Our patient was obese and complained about an extensive lumbosacral fatty mass and wished an aesthetic Intervention. Given the topography of this kind of lipomas Computed Tomography myelography is warranted, it is superior to ultrasonography, provides an exact localization and an excellent resolution of the anomaly [8]. Surgical management of lumbosacral spinal lipomas consists of untethering the cord in symptomatic cases, and debulking of the lipomatous component to improve the spinal contour. However, management remains controversial [9].

Early surgery must be contemplated to prevent further deterioration and neurological deficits; aesthetic concern remains an important issue and should be considered [10]. Liposuction continues to expand to different areas of plastic surgery; Berenguer et al present their experience with liposuction in the treatment of nine cases termed "atypical," for not being purely aesthetic; included are four congenital lipodystrophies-occult spinal dysraphism, with good results [11]. El-Ali et al underlined through a series of 11cases the importance of managing spinal lipomas in a multidisciplinary team involving neurosurgeons and plastic surgeons; this series demonstrates that aesthetic results were satisfactory despite some complication [12]. In our patient Surgical management was performed successfully by a combined team of plastic surgeons and neurosurgeons, with excellent result.

CONCLUSION

Management of lumbosacral spinal lipomas associated with occult spina bifida is challenging. Each swelling para-vertebral fatty mass should be neuro-radiologically explored to detect a possible associated spina bifida which should be treated in childhood. Esthetic



intervention should be performed after neurosurgery cure to rule out an eventual neurological complication.

ACKNOWLEDGEMENT: None

CONFLICT OF INTEREST:

The authors declare that they have no conflict of interest.

STATEMENT OF HUMAN AND ANIMAL RIGHTS

All procedures performed in human participants were in accordance with the ethical standards of the institutional research committee and with the 1964 Helsinki declaration and its later amendments or comparable ethical standards. This article does not contain any studies with animals performed by any of the authors.

REFERENCES

1. Barut OR, Tarhan, C, Cerci, M, Ciris, E, Tasliyar. (2006). Lipoma of the parietal peritoneum, an unusual cause of abdominal pain. *Annals of Saudi Medicine*, 26, 388-390.
2. Crols R, Appel B, Klaes R. (1993). Extensive cervical intradural and intramedullary lipoma and spina bifida occulta of C1, a case report. *Clinical Neurology and Neurosurgery*, 95, 39-43.
3. WM Thompson, AI Kende, AD Levy. (2003). Imaging characteristics of gastric lipomas in 16 adult and pediatric patients. *American Journal of Roentgenology*, 181, 981-985.
4. Gokhale S. (2007). High resolution ultrasonography of the anterior abdominal wall. *Indian Journal of Radiology and Imaging*, 17 (4), 290-298.
5. Pierre-Kahn A, Lacombe J, Pichon J et al. (1986). Intraspinal lipomas with spina bifida. Prognosis and treatment in 73 cases. *J Neurosurg*, 65, 756-761.
6. Lassman LP, James CC. (1967). Lumbosacral lipomas, critical survey of 26 cases submitted to laminectomy. *J Neurol Neurosurg Psychiatry*, 30(2), 174-181.
7. Liptak GS, Garver K, Dosa NP. (2013). Spina bifida grown up. *J Dev Behav Pediatr*, 34(3), 206-215.
8. McLone D, Thompson D. (2001). Lipomas of the spine. In, McLone D, editor. *Pediatric Neurosurgery*. Philadelphia, WB Saunders, 289-301.
9. Jiang SN, Jiang GF, Cheng PJ. (1994). Lumbosacral lipomas with spinal bifida. *Zhonghua Wai Ke Za Zhi*, 32(11), 673-5.
10. Amandeep Kumar, Ashok K Mahapatra, Guru D Satyarthee. (2012). Congenital spinal lipomas, Role of prophylactic surgery. *J Pediatr Neurosci*, 7(2), 85-89.
11. Berenguer B, de la Cruz L, de la Plaza R. (2000). Liposuction in atypical cases. *Aesthetic Plast Surg*, 24(1), 13-21.
12. El-Ali K, Slator R, Solanki G, Hockley A, Nishikawa H. (2009). Multidisciplinary management of spinal lipoma. *J Plast Reconstr Aesthet Surg*, 62(7), 964-8.

