



**SYNOVIAL SARCOMAIN SUPRACLAVICULAR REGION WITH
BRACHIAL PLEXUS COMPRESSION; A RARE TUMOR IN THIS
AREA WITH RARE PRESENTATION**

Niaz H.Soomro*, Aneeqa A.Zafar, Syed Imtiaz A Rizvi, Abdul Hayee and Ali Shan Shariff

Department of Thoracic Surgery, Ojha Institute of Chest Diseases, Dow University of Health Sciences,
Karachi, Pakistan - 75300.

Corresponding Author:- **Niaz Hussain Soomro**
E-mail: soomroniaz@yahoo.com

| | |
|---|---|
| <p>Article Info <i>Received 06/10/2015</i> <i>Revised 27/10/2015</i> <i>Accepted 02/11/2015</i></p> <p>Key words: Synovial sarcoma, brachial plexus compression, Head and neck synovial sarcomas.</p> | <p>ABSTRACT We report the case of an 18 year old female who presented with a growing mass in the left supraclavicular region along with left arm weakness and was diagnosed with synovial sarcoma arising in the neck, along the cervical spine, with associated compression of the brachial plexus.</p> |
|---|---|

INTRODUCTION

Soft tissue sarcomas account for less than 1% of all tumors of the head and neck region [1]. It is rare for synovial sarcoma to occur in the neck and constitutes only 0.01% of all malignancies in that area [2]. Synovial sarcoma is a malignant tumor of pluripotent mesenchymal cells [2,3], which contrary to its name, does not arise from the synovial membrane. It usually arises in close proximity to the large joints of the extremities. In the head and neck, the hypopharynx is the commonest site [3]. The first case of synovial sarcoma of the head and neck was described in 1954; it was located in the pharynx [3]. Synovial sarcomas can be found in the prevertebral space from the base of the skull to the hypopharynx, retropharyngeal and parapharyngeal spaces, and anterior neck along the edges of the sternocleidomastoid muscle, as well as sites in the oropharynx and larynx. Only 12 cases of synovial sarcoma involving peripheral nerves have been reported till now and only three of them involved the brachial plexus [2].

CASE REPORT

An 18 year old girl presented with a mass in the left supraclavicular region, for the last 2 years. According to her, the mass had been progressively increasing in size. Initially, the girl had presented to her local physician where FNAC of the mass was performed. On high index of suspicion of tuberculosis on FNAC report, she was started on Anti-tuberculosis therapy which she received for 9 months. The patient demonstrated no response to ATT and the mass continued to increase in size. She then started complaining of numbness and weakness in her entire left arm which became progressively worse to a point where she was no longer able to use her left arm for daily activities. She was referred to our institute for further management. On physical examination, a swelling was noted in the left supraclavicular region with a scar mark over its surface. It was non tender, firm and immobile. There was weakness of the intrinsic muscles of the left hand and the patient was unable to grasp a pen between her



thumb and index finger. Left arm movements were reduced and patient was unable to abduct her arm fully. CT scan neck demonstrated a heterogeneously enhancing mass about 5.8x4.9x5.4cm in the left supraclavicular region, causing erosion of the transverse processes of C7 and T1 vertebral bodies and the proximal portion of the 1st rib. Inferiorly, it was extending up to the upper border of T1 and superiorly up to the lower border of C6. Initially, incisional biopsy of the mass was performed and histopathology revealed synovial sarcoma. Definitive surgery was planned. After pre-operative work-up, the patient underwent excision of the tumor. On table, the

swelling was noted to extend under the clavicle, medially, it was along the sternocleidomastoid and carotid sheath and posterolaterally to the trapezius muscle. Posteromedially, vertebral bodies C6 and C7 were eroded. The branches of brachial plexus were seen along the capsule of the tumor but there was no sign of invasion. All branches were separated and spared.

Her post-operative recovery was smooth. Post operative physical exam demonstrated complete revival of left arm movements. The patient was discharged after 10 days and referred to radiation oncology for further management.

Fig 1. CT scan neck with contrast demonstrating a heterogeneously enhancing mass in the neck region with erosion of the transverse process of vertebral body

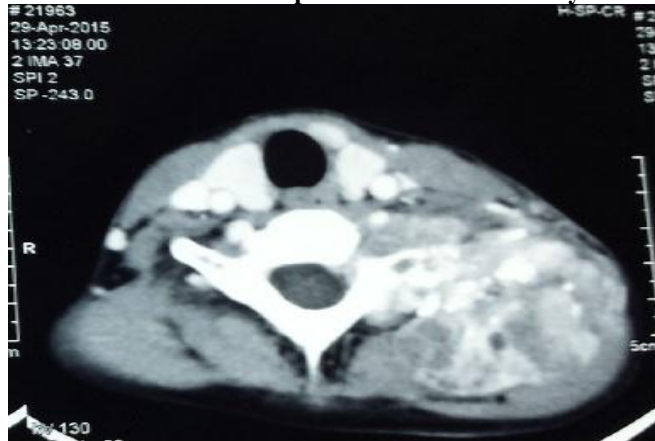


Fig 2. CT scan neck showing heterogeneously enhancing mass

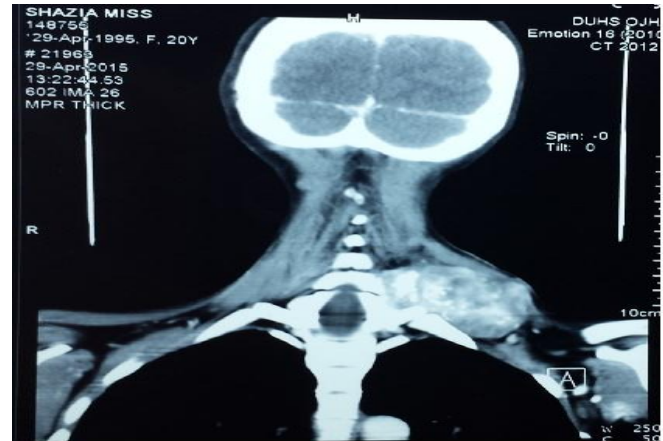

Fig 3. Per operative picture showing tumor in the neck region

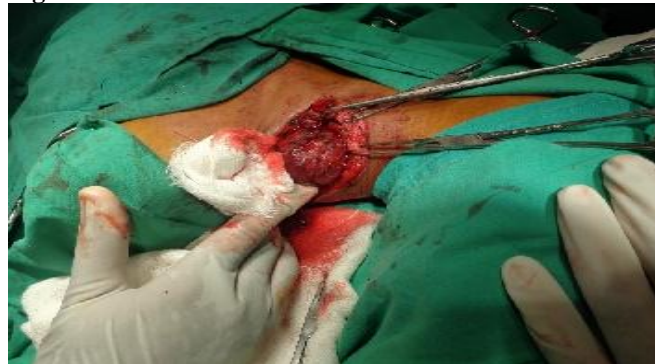
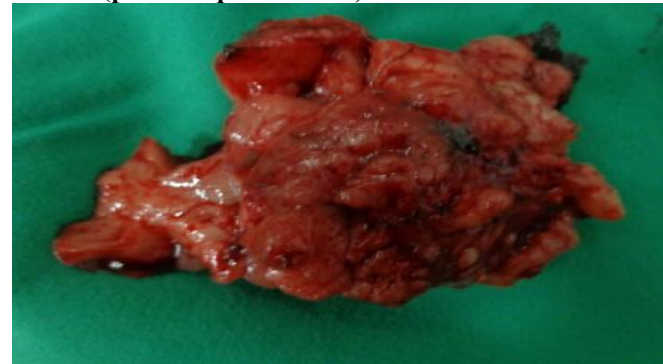
Fig 4. Per operative picture showing tumor after excision (pseudocapsule visible)



DISCUSSION

Synovial sarcomas are rare soft tissue tumors that usually arise in the pararticular areas of the tendon sheaths and joints of the lower and upper-extremities. Other locations include the mediastinum, heart, abdominal wall, mesentery, retroperitoneum, peritoneal cavity and the head and neck region [2]. These tumors show a male predominance (3:2) and predilection for patients between 25 and 36 years of age [4,5]. In our case the patient was a 20 year old female which is different from the common pattern usually observed. Synovial sarcoma of the neck usually appears as an asymptomatic mass until it acquires

sufficient volume to cause compressive effects on neighboring structures [5,6]. It can be a painless mass or associated with symptoms such as pain, dysphagia, dyspnea, earache, sore throat, and bleeding [7]. Brachial plexus involvement is extremely rare with only 3 published cases in literature. Depending of which nerve root is involved, patients may present with weakness of the deltoid, biceps, brachioradialis and intrinsic muscles of the hand [2]. Wrist drop maybe a prominent feature with radial nerve involvement. Our patient had weakness of deltoid and intrinsic muscles of the hand. She had limited ability to abduct her arm and fine movements of the hand were



reduced. Post-operatively, she regained full control of her left arm movements.

Diagnosis is based on imaging, histopathology, immunohistochemistry and cytogenetic tests. Radiology helps to delineate the characteristics and extent of tumor, involvement of surrounding structures and gives a guideline for future surgical planning. On imaging, these tumors can be spherical, well-circumscribed, lobulated or multinodular, covered with a pseudocapsule, sometimes with cystic or haemorrhagic foci [8]. There are 2 main histologic subtypes of synovial sarcomas namely biphasic and monophasic. The biphasic type contains both epithelial and spindle cell components while the monophasic forms shows a uniform spindle pattern. A third variant, the poorly differentiated type is not commonly found [9].

Most synovial sarcomas are positive for epithelial markers such as Cytokeratin and epithelial membrane antigen (EMA). Many of them will also show reactivity to CD99, vimentin, desmin and BCL2 [9]. Our patient was EMA, CD99, TLE, and cytokeratin AE1/AE3 positive. Thus our patient had the biphasic variant of synovial sarcoma. Despite its high sensitivity, cytogenetic evaluation for reciprocal chromosomal translocation (X;18 p11.2;q11.2), is often not performed if the diagnosis is certain on the basis on histopathology and immunochemistry [10].

Due to its rarity, there are very few publications on the treatment approach for these tumors. However, it is uniformly accepted that all head and neck synovial sarcomas should undergo complete surgical resection followed by postoperative radiation therapy in those at high risk for regional recurrence [1]. Limited excision is associated with a high incidence of local recurrence (60 to

90%) within two years of the original surgery, so wide local excision to ensure negative margins is the most important aspect of the treatment [3]. Role of post operative chemotherapy is controversial. Lindberg et al. demonstrated that there was no improvement when comparing patients treated with post operative radiotherapy alone than those receiving postoperative chemoradiotherapy [1]. Localized synovial sarcoma treated with conservative surgery and radiotherapy has a 5 and 10 year survival rate of 76% and 57%, respectively [6].

CONCLUSION

Synovial sarcoma of the neck is an extremely rare tumor which usually presents with compressive symptoms on the neighbouring structures. When the brachial plexus is involved, the patient may present with restricted movements of the affected side. Surgical resection followed by radiotherapy remains the mainstay of treatment.

ACKNOWLEDGEMENT: None

CONFLICT OF INTEREST:

The authors declare that they have no conflict of interest.

STATEMENT OF HUMAN AND ANIMAL RIGHTS

All procedures performed in human participants were in accordance with the ethical standards of the institutional research committee and with the 1964 Helsinki declaration and its later amendments or comparable ethical standards. This article does not contain any studies with animals performed by any of the authors.

REFERENCES

1. Nancy Lee and Edward Shin. (2008), Treatment outcomes for patients with synovial sarcoma of the head and neck. *Expert Rev. Anticancer Therapy*, 8(3), 371-373.
2. Anand G, Mrunal K, Shilpa P, Sudhir K. (2011). A rare case of synovial sarcoma involving the brachial plexus. *Indian J Surg Oncology*, 2(1), 24-26.
3. Adriano S, Amanda A, Fabiola M. (2014). Synovial Sarcoma in the head and neck: A case report. *Int Arch Otorhinolaryngol*, 18, 87-89.
4. Zhu M, Jun L, Ke-jing W, Jin-B. (2012). Primary synovial sarcoma of the parapharyngeal space: a clinicopathologic study of five cases. *World Journal of Surgical Oncology*, 10, 158.
5. Lina IC, Rosalind S, Philip R, Patricia Ann. (2011). Parapharyngeal space synovial sarcoma. *Medical Journal of Malaysia*, 66(4), 379-380.
6. Shaariyah M, Mazita A, Masaany M, et al. (2010). Synovial sarcoma: A rare presentation of parapharyngeal mass. *Chinese Journal of cancer*, 29(6), 631-3.
7. Balakrishnan V, Flatman S, Dixon BJ, Lyons B. (2012). Synovial sarcoma of the pharynx causing airway obstruction. *Med J Aust*, 196(1), 72-73.
8. Saydam L, Kizilay A, Kalcioğlu MT, Mizrak B, Bulut F. (2002). Synovial sarcoma of the pharynx: a case report. *Ear Nose Throat J*, 81(1), 36-39.
9. Anne S, Daneil V, Juliette V, Guy S, et al. (2001). Synovial sarcomas of the head and neck: CT and MR imaging findings of 8 patients. *American Journal of Neuroradiology*, 22, 851-857.
10. Charalampos MM, Kopanakis A, Patentalakis G, Patentalakis M. (2008), Primary monophasic synovial sarcoma presenting as a pulmonary mass. *Journal of Medical Case Reports*, 2, 18.

