



## MANAGEMENT OF RADICULAR CYST IN PEDIATRIC PATIENTS

**Meenakshi Bodh, Arun Kumar\*, Ritu Namdev, Monica Gogia, Priyanka Grewal and Samir Dutta**

Department of Pedodontics & Preventive Dentistry, Post Graduate Institute of Dental Sciences, Rohtak, Haryana, India.

Corresponding Author:- **Arun Kumar**  
E-mail: [drarun922@gmail.com](mailto:drarun922@gmail.com)

<p><b>Article Info</b> <i>Received 15/08/2015</i> <i>Revised 27/08/2015</i> <i>Accepted 25/09/2015</i></p> <p><b>Key words:</b> Radicular cyst, Enucleation, Marsupialisation, Pathologic cavity, Mandible.</p>	<p><b>ABSTRACT</b> Children are the victims of a spectrum of pathological lesions affecting the jawbones. These lesions can be neoplastic, developmental or inflammatory in origin. Most common amongst these lesions of inflammatory origin is radicular cyst, which are common sequelae of dental caries. Being asymptomatic, these cysts are left unnoticed until detected during routine periapical radiography. Most radicular cysts seen in the primary dentition are associated with mandibular molars, teeth that are most frequently affected by dental caries.</p>
---	--

### INTRODUCTION

Radicular cysts are odontogenic cysts which are derived from the inflammatory activation of epithelial root sheath residues (cell rests of Malassez) [1]. This cyst is classified as inflammatory, because in majority of cases it is a consequence to pulpal necrosis following caries, with an associated periapical inflammatory response. Radicular cysts are considered to be rare in the primary dentition, comprising only 0.5-3.3% of the total number of radicular cysts in both the primary and permanent dentition [2,3].

Assuming that the developmental mechanisms of radicular cysts are identical in the primary and permanent dentition, the low frequency in the former is yet to be clarified. We hereby report two cases each of radicular cyst associated with infected deciduous tooth. This paper presented the two cases of radicular cyst along with the treatment planned suited for the cases.

### CASE REPORT 1

A 9 year old boy was referred to the Department of Pedodontics and Preventive Dentistry, PGIDS, Rohtak with a complaint of dull pain and swelling in lower left back region of mouth since one and a half months.

On intra-oral examination, grossly carious mandibular left second primary molar and buccal cortical plate expansion with vestibular obliteration was seen (fig 1). The Orthopantomogram showed a large well defined unilocular radiolucency apical to grossly decayed deciduous second molar with displacement of developing second premolar bud below mandibular first molar (fig 2).

From history, clinical and radiographic findings a provisional diagnosis of radicular cyst was made. The case was posted for surgical marsupialization of the lesion. Under local anaesthesia, the primary tooth was extracted and the superficial lesional lining was enucleated (fig 3). The premolar was preserved and post surgical healing was facilitated with iodoform dressing changed biweekly. The histologic examination revealed a cystic cavity lined by non-keratinized stratified squamous epithelium with inflammatory cell infiltration which confirmed the diagnosis of radicular cyst. On successive visits, reduction in cystic cavity size and eruption of premolar was observed (fig 4). The eruption of premolar which was severely displaced occurred in a buccal position and the patient is planned for orthodontic treatment for its alignment.

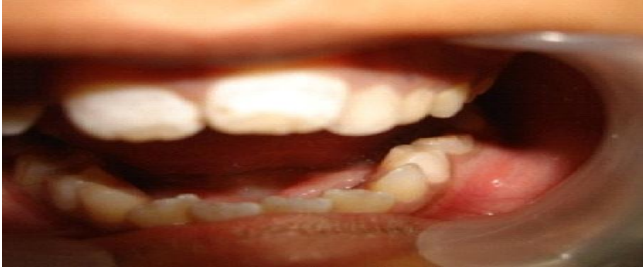

## CASE REPORT 2

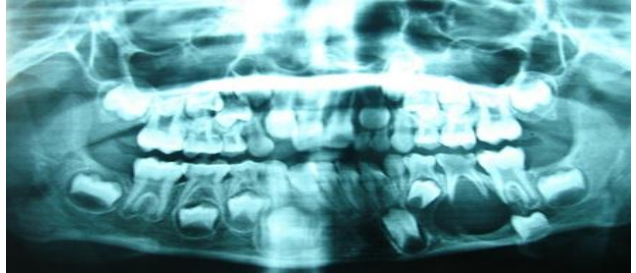
A 10 year old boy was referred to our Dept because of pain and swelling on lower right back region of the mouth since 3 months (fig 5). Intra-oral examination revealed composite resin restoration in mandibular deciduous left second molar which was grade II mobile and expanded buccal cortical plate. Radiography showed a large well defined radiolucency extending from mesial of developing first premolar to permanent second molar and

resorbed roots of deciduous second molar (fig 6). Under local anaesthesia, the second deciduous molar was extracted and the cyst was enucleated with the complete removal of cyst lining (fig 7). The cystic lining was sent for histopathological examination which confirmed the diagnosis of radicular cyst (fig 8). The premolar aligning in the arch was appreciated on successive visits both clinically and radiographically (fig 9,10).

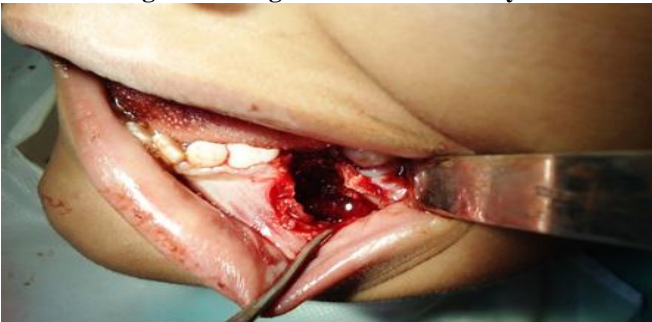**Figure 1. Pre-Operative View**



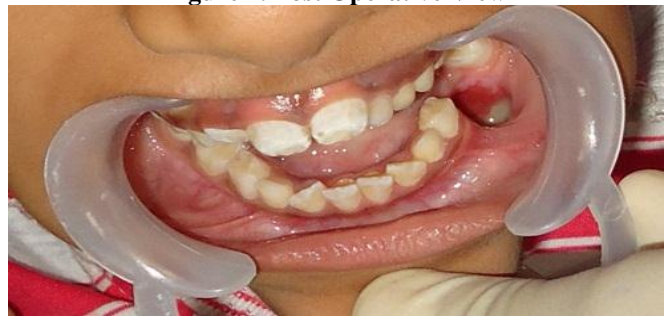**Figure 2. OPG showing extension of large mandibular radicular cyst**



**Figure 3. Surgical enucleation of cyst**



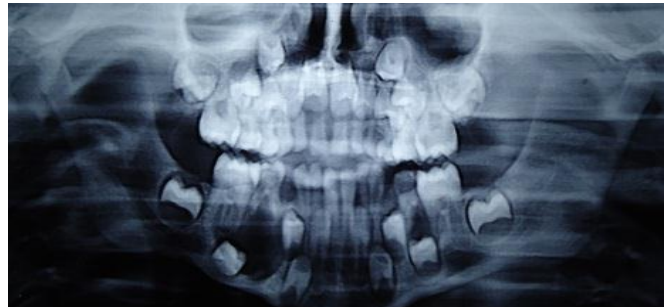
**Figure 4. Post Operative View**



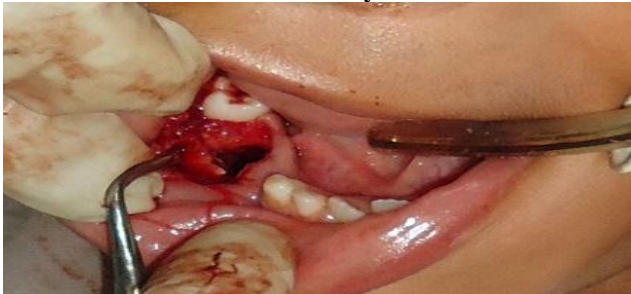**Figure 5. Pre-Operative View**



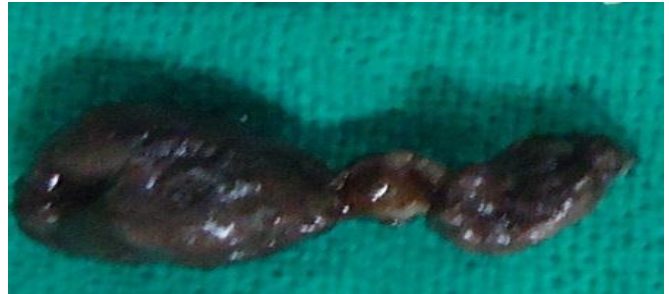**Figure 6. OPG showing radicular cyst in right side of mandible**



**Figure 7. Intra-Operative View showing enucleation of radicular cyst**



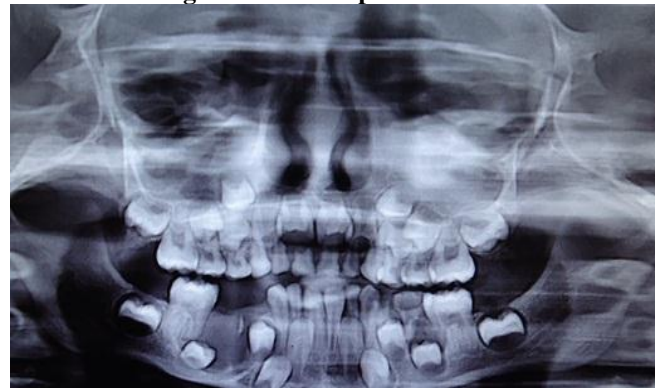
**Figure 8. Specimen of cystic enucleated material fixed under formalin**



**Figure 9. Post Operative View**



**Figure 10. Post Operative OPG**



## DISCUSSION

Radicular cyst and granuloma are the most common among the lesions of inflammatory origin. Radicular cysts associated with deciduous teeth are reported to occur in age range of 3–19 years with a male preponderance [3]. The most commonly involved deciduous teeth are mandibular molars (67%), maxillary molars (17%) followed by anterior teeth [4]. The etiologic factor most commonly implicated is dental caries followed by trauma. These lesions are mixed inflammatory reactions with the chronic granulomatous inflammatory reaction being the predominant type observed. These lesions may contain epithelium suggesting the potential for cystic transformation [5]. In the past, occurrence of radicular cysts in the primary dentition has been considered as rare. Lustmann and Shear in an extensive review from 1898 to 1985, found only 28 cases to which they added 23 cases and prevalence of radicular cysts in primary dentition was reported to be less than 1% [1]. However, Mass et al analysed 49 primary molar teeth with radiolucent lesions ranging from 4-15 mm in diameter and 73.5% of all lesions were diagnosed as radicular cysts and 26.5% as granulomas [6].

Various reasons cited for this relative rarity include presence of deciduous teeth for a short time, easy drainage in deciduous teeth due to the presence of numerous accessory canals and a radicular radiolucency in relation to deciduous teeth are usually neglected. Additionally, the lesions tend to resolve on their own following the extraction/exfoliation of the associated tooth and are generally not submitted for histopathological examination [7-11]. Microscopically a radicular cyst is formed by a mature collagenous connective tissue wall. This connective tissue is the basic framework (stroma) of most cysts found in the maxillofacial regions. Abundant fibroblasts, the basic cell of the connective tissue, can be identified within the cystic wall and characteristically present dark staining nuclei in the center of the cytoplasm. The fibroblasts are seen within the undulating collagen fibers [8-10]. The wall generally presents an inflammatory infiltrate of variable degree. Lymphocytes are generally the most prominent cells in the infiltrate and are characterized

by their darkly stained nucleus, which occupies most of the cytoplasm. Plasma cells are also abundant in cysts' walls and mostly seen in long standing (chronic) cysts. They are characterized by an eccentric nucleus with a cart-wheel arrangement of the nuclear chromatin. Plasma cells are considered factories of immunoglobulins.

Other histological findings within the cystic wall are: erythrocytes and areas of intratissular hemorrhage, occasional spicules of dystrophic bone, multinucleated giant cells and cholesterol crystals. Role of formocresol in initiating cystic reaction has been reported by several authors. Formocresol, along with tissue proteins, is antigenic and elicits a humoral and cell mediated response [10-14]. Since the lesions associated with pulpotomy-treated teeth are essentially the same histologically as the lesions associated with primary molars which had furcation lesions without pulp treatment, the lesions cannot be specifically attributed to the use of formocresol [14].

More recently it has been reported that pulp therapy in the form of calcium hydroxide/iodoform (non-phenol) may also be responsible for the stimulation of radicular cysts in primary molars [15]. This does not imply that prohibition of medicaments for pulp treatment of primary teeth is necessary, but based on these data primary molars after pulp therapy should receive periodic postoperative radiographic examination. In our cases only one deciduous molar associated with radicular granuloma was endodontically treated in the past.

Radicular cysts are thought to increase in size no more than 4 mm per year and usually remain asymptomatic providing there are no acute inflammatory exacerbations [16]. The sequelae of an untreated or undiagnosed radicular cyst could be harmful to the patient's future dental development. A patient with an untreated radicular cyst may present with the following: swelling, tenderness, tooth mobility and a bluish tinge caused by buccal expansion of the cortical plates [15,16]. Furthermore, displacement of the successor tooth or, the loss of its vitality may result [17,18]. Various treatment modalities that are advocated for cystic lesions are enucleation, enucleation with





curettage, marsupialization, and marsupialization with enucleation.

Other treatment modalities include, removable or fixed resin tubes followed by saline irrigation after each meal to prevent fibrous healing and to promote decompression and the use of removable acrylic partial dentures for decompression and space maintenance. The permanent successor erupted in the dental arch despite severe displacement in case 1 which needs orthodontic treatment for alignment. Each case should be monitored clinically and radiographically for premolar alignment and healing of osseous defect. Simultaneous with the eruption of permanent teeth, ossification of the bony defect can take place. The reparatory process is completed in one to two years. In children, healing of post surgical osseous defects is always good as they have high propensity for bone regeneration.

## REFERENCES

1. Lustmann J, Shear M. (1985). Radicular cyst arising from deciduous teeth- review of literature and report of 23 cases. *Int J Oral Surg*, 14, 153–61.
2. Shear M. (1992). Radicular and residual cysts. In , Cysts of the oral region, 3rd ed., *Wright*, 136-62.
3. Bhaskar SN. (1966). Periapical lesion, Types, incidence and clinical features. *Oral Surg Oral Med Oral Pathol*, 21, 65-72.
4. Ten Cate AR. (1972). The epithelial cell rests of Malassez and the genesis of the dental cyst. *Oral Surg Oral Med Oral Pathol*, 34(6).956-64.
5. Hill FJ. (1978). Cystic lesions associated with deciduous teeth. *Proc Br Paedod Soc*, 8, 9-12.
6. Main DM. (1970). Epithelial jaw cysts, a clinicopathological reappraisal. *Brit J Oral Surg*, 8(2), 114-25.
7. Mass E, Kaplan I, Hirshberg A. (1995). A clinical and histopathological study of radicular cysts associated with primary molars. *J Oral Pathol Med*, 24, 458-61.
8. Nagata T, Nomura J, Matsumura Y, Yanase S, Fujii T, Oka T. (2008). Radicular cyst in a deciduous tooth, a case report and review of literature. *J Dent Child*, 75, 80-84.
9. Shetty S, Angadi PV, Rekha K. (2010). Radicular cyst in deciduous maxillary molars, A Rarity. *Head and Neck Pathol* , 4, 27-30.
10. Ramakrishna Y, Verma D. (2006). Radicular cyst associated with a deciduous molar, a case report with unusual clinical presentation. *J Indian Soc Pedod Prev Dent*, 24, 158-60.
11. Gandhi S, Franklin DL. (2008). Presentation of radicular cyst associated with a primary molar. *Eur Arch Paediatr Dent*, 9, 56–59.
12. Savage NW, Adkins KF, Weir AV, Grundy GE. (1986). A histological study of cystic lesions following pulp therapy in deciduous molars. *J Oral Pathol Me*.15, 209–212, 1986.
13. Rodd HD, Boissonade FM. (2006). Immunocytochemical investigation of immune cells within human primary and permanent tooth pulp. *Int J Pediatr Dent*, 16, 2–9.
14. Grundy GE. (1984). Cysts associated with deciduous molars following pulp therapy. *Aust Dent J*, 29, 249–56.
15. Myers DR, Durham LC, Hanes CM, Barenie JT, Mc Kinney RV (1988). Histopathology of radiolucent furcation lesions associated with pulpotomy-treated primary molars. *Pediatr Dent*, 10, 291-94.
16. Takiguchi, M, Fujiwara, T. (2001). Radicular cyst associated with a primary molar following pulp therapy, a case report. *Int J Paediatr Dent*, 11(6), 452-5.
17. Smith AT, Cowpe JG. (1985). Radicular cyst arising from a traumatized primary incisor, a case report of a rare complication that emphasizes the need for regular follow-up. *Dent Update*, 32, 109-110.
18. Lustig, JP, Schwartz-Arad, D. (1999). Odontogenic cysts related to pulpotomized deciduous molars, clinical features and treatment outcome. *Oral Surg Oral Med Oral Pathol Oral Radiol Endod*, 87(4), 499-503.

## CONCLUSION

Given the severity of sequelae of the radicular radiolucent lesion associated with deciduous teeth it is prudent to timely detect and treat these lesions.

**ACKNOWLEDGEMENT:** None

## CONFLICT OF INTEREST:

The authors declare that they have no conflict of interest.

## STATEMENT OF HUMAN AND ANIMAL RIGHTS

All procedures performed in human participants were in accordance with the ethical standards of the institutional research committee and with the 1964 Helsinki declaration and its later amendments or comparable ethical standards. This article does not contain any studies with animals performed by any of the authors.

