




International Journal of Orthopaedics and Physiotherapy



Journal homepage: www.mcmed.us/journal/ijop

SIGNIFICANCE OF HYOID BONE AND ITS POSITION IN ORTHODONTICS- A REVIEW

Vijaylaxmi Mendigeri

Senior Lecturer, Department of Orthodontics, P.M.N.M Dental College and Hospital, Bagalkot, Karnataka, India.

Article Info

Received 28/08/2015

Revised 10/09/2015

Accepted 16/09/2015

Key words:

Hyoid bone, Hyoid bone position, Orthodontic treatment.

ABSTRACT

Hyoid bone is an insertion element for muscles, ligaments, and fasciae attaching to the mandible, clavicle, sternum, cranium and cervical spine. It is also unique structure because it has no bony articulation. The cervical fasciae are closely related to the hyoid system and these bind the anterior cervical spine to the hyoid bone as well as the infra and supra- hyoid muscles, which depends on the hyoid bone and its relationship with the cervical spine for normal function. Significance of the hyoid bone has been emphasized in recent years, after it was appreciated that dysfunctional factors affecting the hyoid system produce not only local, but also general effects so it is important to know anatomy, growth its position and also position changes in various conditions, before and after orthodontic treatment which may help in better outcome of orthodontic treatments.

INTRODUCTION

Based on the complexity of the stomatognathic system, specific knowledge on its anatomy, physiology and craniofacial growth theories are paramount in order to understand its whole functioning in individuals [1].

According to Meredith [2], an important growth increment happens in the first years of life. At birth, the craniofacial bones of a Caucasian American corresponds to 60% of the adult head size, 80% at six months of age, 90% at three years, and 95% at nine years of age. Thus, at 12 years of age, when many orthodontists start treatment, almost all facial growth is completed. As a result, it is important to follow a preventive approach before the final phase of the craniofacial growth. As the lingual functions and mandibular muscles are thought to affect the craniofacial growth and development, the morphological analysis of the hyoid bone would be considered for evaluating how shape is affected by function, since the hyoid bone is supported by muscles only, with no osseous

connection with skull and mandible. Therefore, the hyoid bone position depends on the balance involving the surrounding soft tissues [3].

Significance of the hyoid bone has been emphasized in recent years, after it was appreciated that dysfunctional factors affecting the hyoid system produce not only local, but also general effects [4-5]. So it is important to know anatomy, growth its position and also position changes in various conditions, before and after orthodontic treatment which may help in better outcome of orthodontic treatments.

Anatomy of hyoid bone

The hyoid bone is U shaped. It is situated in the anterior midline of the neck between the chin and thyroid cartilage. At rest, it lies at the level of the third cervical vertebra behind and the base of the Mandible in front. The bone consists of the central part called the body, and of two pairs of cornua, greater and lesser [6]. (Figure 1)

It is kept suspended in position by muscles and ligaments. The hyoid bone provides attachment to the floor of the mouth and to the tongue above, to the larynx below, and to the epiglottis and pharynx behind.

Corresponding Author

VijaylaxmiMendigeri

Email:-vijuortho@gmail.com

Research Article



Through the muscle attachments, the hyoid plays an important role in mastication, in swallowing, and in voice production.

Development

Upper part of the body and lesser cornua develop from second brachial arch, while lower part of body and greater cornua develop from the third arch [6].

Growth

The relationship between the hyoid bone and mandible stays constant from the age of three years. Hyoid position tends to remain at the inferior half of C-3 vertebral body and the superior half of C-4. When all permanent teeth except the third molars are erupted the hyoid bone position is near and above a line connecting the third vertebra and the most inferior portion of the chin [8]. During puberty, the hyoid usually moves slightly anterior but not in cranial or caudal directions [7]. This maturational descent of the hyoid bone is thought to be closely related to speech [9-10] and deglutition [11].

Early descent of the hyoid bone is hypothesized to account for the evolutionary adaptation of speech development, used to resonate the sound spectrum with the frequency of a harmonic [12]. In contrast, late descent, which is readily observed in middle-aged or older men with obstructive sleep apnea [13-14] or in associated with airway patency because airway resistance appears to increase with age or after the surgery. It is not clear whether late descent occurs in normal adults.

Cephalometric analysis of hyoid bone position

The precise measurement of the position of the hyoid bone has been difficult. Although cephalometric analysis has been the preferred research technique, slight variations in head position in the cephalostat, postural position of the spine, and the state of function have significant effect on hyoid bone position [15].

Cephalometric studies of the hyoid bone usually use intracranial reference planes to measure the position of hyoid bone. There for that many workers have commented that the position of the hyoid bone is variable is not unexpected. Cranial reference planes are relatively distinct from the hyoid bone, thus comparatively small variations in the cranial planes are reflected as meaningful changes in the position of hyoid bone [16].

The hyoid triangle

Bibby and Preston [16] advocated that the position of the hyoid bone might be easily determined in three directions by using the relationship between cervical vertebra and mandible instead of using the planes of cranial reference which greatly reduces the effects that changes in cranial posture have on assessment of the position of the hyoid bone. As the level of the mandibular

symphysis is more comparable to the head rotation axis than the skull, the effect of the head movement might be minimized and as a result the position of the hyoid bone could be more correctly determined. Consequently, they developed an analysis of the hyoid bone position known as Hyoid Triangle, which is formed by the following points: Retrognathion – RGn (the most posterior-inferior point of the mandibular symphysis), Hyoid point – H (the most anterior-superior point of the body of the hyoid bone), and C3 (the most anterior-inferior point of the third cervical vertebra).

The antero-posterior position of the hyoid bone was determined by H-RGn and H-C3 both anteriorly and posteriorly. The vertical position of the hyoid bone was determined by the plane C3-RGn in relation to the Hyoid point (H-H') perpendicularly. The angular position of the hyoid bone incorporating the larger horn was determined by the angle formed by the hyoid axis and C3-RGn plane.

Hyoid bone position

During the last two decades considerable attention has been given to the hyoid bone position in relation to the facial skeleton during growth and development [17].

Position of hyoid bone is reflection of the tension in the muscles, ligaments and fascia attached to it and changes in this environment also change in position and function of hyoid bone [18-19]. Hyoid bone position is of great clinical interest because it plays an important role in maintain the upper airway dimensions and an upright natural head posture and also Orthodontic treatment objectives are influenced by the position of the hyoid bone.

Position of the hyoid bone relative to the cranial base and mandible has been of interest specifically as an indicator of tongue posture and function [20].

Hyoid bone position in subjects with different vertical jaw dysplasias

Pae et al in their study concluded that the significant change in the position of hyoid bone was independent of age or obesity but was related to facial type, as classified by the steepness of the lower margin of the mandible. Their study depicted that a brachyfacial person has a hyoid bone position closer to the mandibular plane and more posteriorly located towards the cervical vertebrae. In contrast, dolichofacial and normal subjects have a hyoid bone positioned more inferiorly and anteriorly than their brachyfacial counterparts [21].

Hyoid bone position in obstructive sleep apnea

Hyoid bone plays an important role in keeping the airway patent. Upper airway structures tend to collapse in the supine position. The compensatory reflexes acting on pharyngeal dilators holding the hyoid bone forward help in preventing pharyngeal narrowing



during the life span [22].

The position of the hyoid bone may be important consideration for obstructive sleep apnoea because it anchors the musculature of the tongue [23]. When this bone is low, the tongue positioned further back, reducing airway potency. It has also been shown that, in OSA patients hyoid bone located in a lower position, in relation to different skeletal structures when compared with controls [24].

The hyoid bone position in mouth breathers and tongue-thrusters

The position of the hyoid bone is determined by muscles and ligaments which are attached to structures above and below it. The attachments of these muscles may affect the position of the hyoid bone by way of tongue movements and also through mandibular movements; thus, the hyoid bone position may be influenced by the habits of tongue-thrusting and mouth breathing. After orthodontic treatment is completed, there is danger of relapse due to the persistence of either of these habits. It is feasible that the orthodontist can take some precautions to prevent relapse if he can determine that the habits remain. If orthodontic therapy corrects the habit as well as correcting the malocclusion, then the hyoid bone may shift its position and the orthodontist will be able to rule out the possibility of relapse due to the habit and will not have to take elaborate precautions to retain the corrected occlusion. Many studies have done see whether the malocclusion can be caused by mouth breathing and tongue thrusting habits has a characteristic hyoid position that may guide for diagnosis [26].

A study done by Adamidis IP, Spyropoulos MN showed mouth breathing was found to affect mandibular position, as well as hyoid bone position and orientation, a possibility of a role played by the suprahyoid muscles in the establishment of a growth direction of the mandible [25].

Whereas another study done by Bibby results of this study showed the hyoid bone have a stable position and is not affected permanently by mouth breathing or tongue-thrusting. It is therefore no assistance in the diagnosis of these conditions [26].

Hyoid bone position in Class I, II and Class III malocclusions

Grant studied the position of the hyoid bone in class I, II and III malocclusions. He concluded that the hyoid bone position is constant in all three classes and that the position of the hyoid bone is determined by the musculature and not by the occlusion of the teeth [27].

Hyoid bone position after treatment

Several authors have analyzed the effects of orthodontic and orthognathic surgical procedures on

hyoid position and function. Any alteration or change in position of the hyoid structures due to orthodontic treatment may have wide functional significance

Hyoid bone position changes after surgical mandibular advancement

Studies [28-34]has shown that there are changes in the position of the hyoid bone and in pharyngeal size in connection with mandibular advancement surgeries. A surgical mandibular advancement leads to change in length and tension of the related musculaturei.e. the supra- and infra- hyoid, the neck extensor, and the cervical fasciae [35]. On the other hand, alterations in cranium position may produce changes in regulation of neuromuscular activity, altering muscular tone, which may indirectly affect the position and/or function of cervical spine, hyoid bone, hypolaryngeal system and tongue. When all the above factors are activated after surgical mandibular advancement and act in concert, this may produce mandibular instability, relapse, and certain degree of disturbed head balance may result [36-37]. Limited mandibular advancement could produce some margin of safety because the smaller the sagittal surgical repositioning of the mandible, the smaller would be the variation in neuromuscular activity and subsequently the response at the level of the hyoid system would be minimized, producing more stable results.

Hyoid bone position changes after mandibular setback

Surgical retrusion of the mandible for correction of mandibular prognathism also results in changes in hyoid bone position.

Studies of hyoid bone position following surgical correction of mandibular prognathism, only minimal changes in the anteroposterior relation of the hyoid bone to the cervical vertebra were demonstrated [38]. whereas in another study ithas been reported that the hyoid bone showed a more vertical movement pattern because the patients had raised their heads after surgical correction of the prognathism [39]. It might suggest therefore that the constant distance between the hyoid bone and the cervical column and the significant changes of the hyoid bone position with the maxilla and the mandible were mainly the results of postural alterations.

Hyoid bone position changes after treatment with a functional appliance

As functional appliance bring a gross amount of change in the patients profile, occlusion, speech, masticatory function, this study was conducted to depict the effect of functional appliance treatment on the position of hyoid bone.If the hyoid bone is in the same position after functional appliance treatment then the soft tissues must still be in the same balanced rest position,



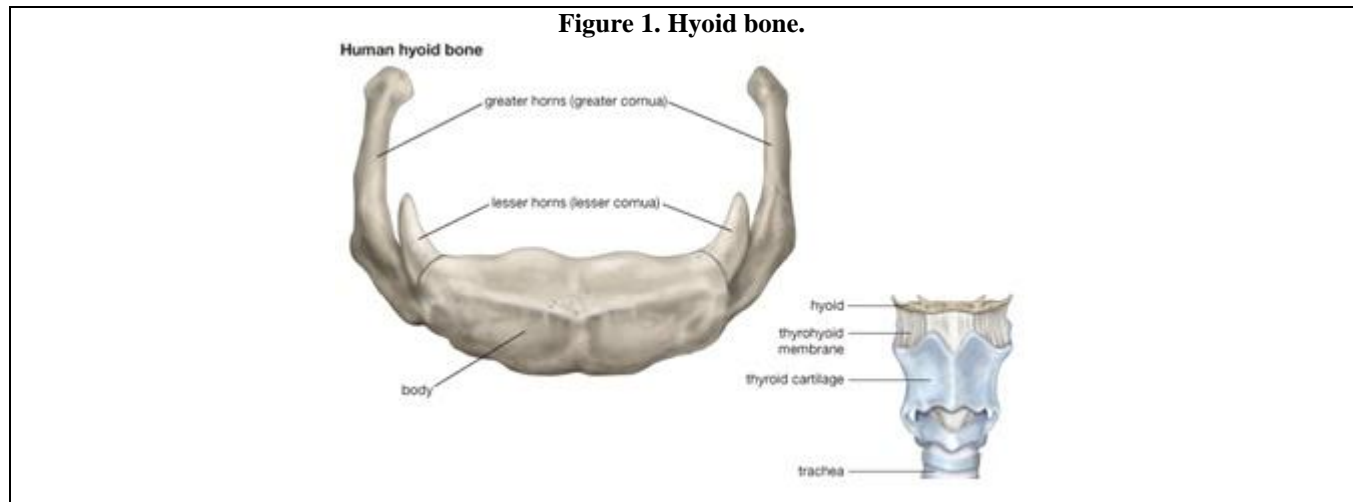
thus reducing the chances of relapse due to soft tissue forces. However, difference observed in the position of hyoid bone beyond its normal range increases the chances of skeletal relapse are limited, therefore the by the steepness of the lower margin of the mandible. Position of hyoid bone can be used as a good indicator to their study depicted that a brachyfacial person has a hyoid predict relapse tendencies [40].

Another study done by Farhana²² observed that there was no statistically significant change in the position

of hyoid bone with functional appliance treatment.

Hyoid bone position following orthodontic treatment of Class I bimaxillary protrusion.

According to Wang Q et al. the pharyngeal airway size became narrower after the treatment. Extraction of four premolars with retraction of incisors did affect velopharyngeal, glossopharyngeal, hypopharyngeal, and hyoid position in bimaxillary protrusive adult patients [41].



CONCLUSION

The hyoid bone is connected to the pharynx, mandible, and cranium through muscles and ligaments. Without the hyoid bone, our facility for maintaining an airway, swallowing, preventing regurgitation, and

maintaining the upright postural position of the head could not be controlled as carefully. So thorough understanding of hyoid bone and its position and also change in position in various orthodontic treatments is helping in successful outcome of orthodontic results.

REFERENCES

1. Maria JP, Coelho F, Darcy FN, José RT, Fausto B. (2007). Cephalometric assessment of the hyoid bone position in oral breathing children. *Brazilian Journal Of Otorhinolaryngology*, 73(1).
2. Meredith Pediatrics HV. (1953). Growth in head width during the first twelve years of life. *Pediatr*, 12(4), 411-429.
3. Kuroda T, Nunota E, Hanada K, Ito G, Shibasaki Y. (1966). A roentgenocephalometric study on the position of the hyoid bone. *Bull Tokyo Med Dent Univ.*, 13, 227-243.
4. Rocavado M. (1983). Biomechanical relationship of cranial, cervical, and hyoid bone regions. *Journal of craniomandibular practice*, 1, 61 – 66.
5. Rocavado M Tapia V. (1987). Radiographic study of craniocervical relation in patients under orthodontic treatment and the incidence with related symptoms. *Journal of craniomandibular practice*, 5, 1 – 6
6. Jack TS. (1990). *Essential of gross Anatomy.*, first Indian Edition.
7. Rocabado M. Craniocervical principles for growth, development and normalization. In: Grummons D. (1997). *Orthodontics for the TMJ.TMD patient.* Arizona: Wright &Co.Publishers, 205 – 221
8. Tsai H. (2002). The positional changes of hyoid bone in children. *J ClinPediater Dent*, 27, 29-34.
9. Nishimura T, Mikami A, Suzuki J, Matsuzawa T. (2003). Descent of the larynx in chimpanzee infants. *ProcNatlAcadSci*, 100, 6930-6933.
10. Nishimura T. (2005). Developmental changes in the shape of the supralaryngeal vocal tract in chimpanzees. *Am J PhysAnthropol*, 126, 193-204.
11. Lieberman DE, McCarthy RC, Hiiemae KM, Palmer JB. (2001). Ontogeny of postnatal hyoid and larynx descent in humans. *Arch Oral Biol*, 46, 117-128.
12. Fant G. (1960). *Acoustic theory of speech production.* The Hague: Mouton & Co., 100-107.



13. Kollias I, Krogstad O. (1999). Adult craniocervical and pharyngeal changes a longitudinal cephalometric study between 22 and 42 years of age. Part II: morphological uvulo-glossopharyngeal changes. *Eur J Orthod*, 21, 345-355.
14. Worsnop C, Kay A, Kim Y, Trinder J, Pierce R. (2000). Effect of age on sleep onset-related changes in respiratory pump and upper airway bone changes muscle function. *J Appl Physiol*, 88, 1831-1839.
15. King EW. (1952). A roentagenographic study of pharyngeal growth. *Angle orthod.*, 22, 23-37.
16. Bobby RE, Preston CB. (1981). The hyoid triangle. *Am J Orthod.*, 80, 92-97.
17. Stepovich ML. (1965). A cephalometric positional study of the hyoid bone. *Am J Orthod*, 51(12), 882-890.
18. Winnberg A, Pancherz H. (1983). Head position and masticatory muscle function an emg investigation. *European Journal of Orthodontics*, 5, 209 – 217.
19. Wenzel A, Williams S, Ritzau M. (1983). Changes in head posture and nasopharyngeal airway following surgical correction of mandibular prognathism. *European Journal of Orthodontics*, 11, 37 – 42.
20. Cuzzo GS and Bowmen DC. (1975). Hyoid positioning during deglutition following forced positioning of the tongue. *Am J Orthod.*, 68, 564-570.
21. Pae EK, Quas C, Quas J, Garrett N. (2008). Can facial type be used to predict changes in hyoid bone position with age? A perspective based on longitudinal data. *Am J OrthodDentofacialOrthop*, 134, 792-797.
22. Farhana G, Mubassar F, Attiya S. (2010). Change in the position of hyoid bone with functional appliance treatment. *J Pak Dent Assoc*, 19(1), 19-23.
23. Maltais F, Carrier G, Cormier Y, Series F. (2009). Cephalometric measurements in snorers, non snorers, and patients with sleep apnoea. *Thorax*, 46, 419-423.
24. Lyberg T, Krogstad O, Djuspesland G. (1989). Cephalometric Analysis In Patients with Obstructive Sleep Apnoea Syndrome: I. Skeletal morphology. *Journal of Laryngoscopy and Otology*, 103, 287-292.
25. Adamidis and spyropoulous. (1992). Hyoid bone position. *Am J OrthodDentofacialOrthop*, 101, 308-312.
26. Bibby RE. (1984). The hyoid bone position in mouth breathers and tongue-thrusters. *Am J orthod*, 85(5), 431-33.
27. Grant LE. A radiographic study of the hyoid bone position in Angle Class I, II and III. Unpublished Master thesis, Univ. of Uanas City
28. Eggensperger N, Smolka K, Johner A, Rahal A, Iizuka T. (2005). Long-term changes of hyoid bone and pharyngeal airway size following advancement of the mandible. *Oral Surg Oral Med Oral Pathol Oral RadiolEndod.*, 99, 404-410.
29. Gale A, Kilpela`inen PV, Laine-Alava MT. (2001). Hyoid bone position after surgical mandibular advancement. *Eur J Orthod*, 23, 695-701.
30. Hayes RJ, Sarver DM, Jacobson A. (1994). The quantification of soft tissue cervicomental changes after mandibular advancement surgery. *Am J OrthodDentofacialOrthop*, 105, 383-391.
31. Schendel SA, Epker BN. (1980). Results after mandibular advancement surgery: an analysis of 87 cases. *J Oral Surg*, 38, 265-281.
32. LaBanc JP, Epker BN. (1984). Changes of the hyoid bone and tongue following advancement of the mandible. *Oral Surg Oral Med Oral Pathol Oral RadiolEndod*, 57, 351-356.
33. Wessberg GA, Schendel SA, Epker BN. (1982). The role of suprahyoidmyotomy in surgical advancement of the mandible via sagittal split ramus osteotomies. *J Oral Surg*, 40, 273-277.
34. Chung DH, Hatch JP, Dolce C, Van Sickels JE, Bays RA, Rugh JD. (2001). Positional change of the hyoid bone after bilateral sagittal split osteotomy with rigid wire fixation. *Am J OrthodDentofacialOrthop*, 119, 382-389.
35. Carlson DS, Ellis III E, Dechow PC. (1987). Adaptation of the supra hyoid muscle complex to mandibular advancement surgery. *Am J OrthodDentofacialOrthop*, 92, 134-143
36. Schendel SA, Epker BN. (1980). Results after mandibular advancement surgery; an analysis of 87 cases. *Journal of oral surgery*, 38, 265 -269.
37. Lake SL, Macneil RW, Little RW. (1981). Surgical mandibular advancement a cephalometric analysis of treatment response. *Am J Orthodontics.*, 13, 99 -108.
38. Takagi Y, Gamble JW, Proffit WR, Christensen RL. (1967). Postural change of the hyoid bone following osteotomy of the mandible. *J Oral Surg*, 23, 688-692.
39. Athanasiou, Toutountzakis, Mavreas, Ritzau, and Wenzel. (1991). Hyoid and pharynx changes after mandibular set-back osteotomy. *Am J OrthodDentofacialOrthop*, 100, 259-265.
40. Jan H. (1999). Post treatment changes in hyoid bone position in dental Class I, II and III [In dissertation] College of Physicians and Surgeons Pakistan.
41. Wang Q, Jia P, Anderson NK, Wang L, Lin J. (2012). Changes of pharyngeal airway size and hyoid bone position following orthodontic treatment of Class I bimaxillary protrusion. *Angle Orthod.*, 82(1), 115-121.

