



NETHERTON'S SYNDROME: A CASE REPORT

Jayakar Thomas^{1*} and Padam Kumar M²

¹Professor & Head, ²Junior Resident, Department of Dermatology, Sree Balaji Medical College & Bharath University, Chennai 600044, Tamilnadu, India.

Corresponding Author: - **Jayakar Thomas**
E-mail: jayakarthomas@gmail.com

<p>Article Info <i>Received 15/08/2015</i> <i>Revised 27/08/2015</i> <i>Accepted 19/09/2015</i></p> <p>Key words: Netherton's syndrome, trichorrhexis invaginata, ichthyosis linearis circumflexa, atopic diathesis.</p>	<p>ABSTRACT</p> <p>Netherton's syndrome is a rare Mendelian autosomal recessive genodermatosis characterized by congenital ichthyosiform erythroderma, atopic diathesis & trichorrhexis invaginata with failure to thrive. We report a case of Netherton syndrome in an 18-year-old woman who presented with the history of red, scaly lesions over the trunk, arms and thighs since 1 month of age, atopic dermatitis and bronchial asthma since childhood and dry brittle hair for the past 6 months.</p>
--	--

INTRODUCTION

Netherton's syndrome is a rare autosomal recessive disorder. The association between bamboo node and ichthyosiform erythroderma was first noted by Touraine and Solente [1] but this syndrome was first described by Netherton in the year 1958 [2]. It was Mevorah et al [3] who for first time established the relationship between Netherton syndrome and Ichthyosis Linearis Circumflexa. They also reported that atopic diathesis occurs in approximately 75% of the patients with Netherton syndrome. This syndrome is linked to mutations in SPINK5 gene. The clinical manifestations vary in severity among different individuals.

CASE REPORT

An 18-year-old woman born out of non-consanguineous marriage came to our skin OPD, with complaints of red coloured, dry and itchy skin since childhood and fragile hair for the past 6 months. The red itchy lesions were initially small in size, which subsequently enlarged to leave scales. Each lesion lasted a few days to disappear and reappear at different sites. The

lesions first appeared at the age of 1 month along with generalized dryness of the skin for which she was diagnosed with atopic dermatitis and was treated till date. She gives history of bronchial asthma since 9 years of age and treatment for the same. There is history of sudden gain in weight with development of multiple stretch marks over the trunk, arms and thighs. There is a history of developing dry, fragile hair which easily breaks on combing for past 6 months. The antenatal, natal and early postnatal periods were uneventful. There is no history suggestive of delayed milestones. There is no history of chronic diarrhoea in her childhood. There is positive history of atopy in the family. On examination she was moderately built and nourished, with normal systemic examination. Dermatological examination revealed multiple erythematous annular lesions with polycyclic margins with double-edge scales at the periphery over the background of dry, scaly skin with multiple pink to violaceous striae (Figure 1), probably due to chronic application of topical steroids. The lesions were predominantly distributed on the back, chest, abdomen and both the arms and thighs. The scalp hair density appeared



to be normal but fragile hair with multiple nodular elevations on their shaft were seen (Figure 2). Hair over the brows, eyelids and the axillae were sparse. The general body hair and the pubic hair appeared normal. Palms, soles, nails and the oral mucosa appeared normal.

Routine blood and urine investigations were normal. Serum IgE levels were raised. Light microscopy of the scalp hair after clipping revealed multiple nodular elevations (Figures 3&4) over the shaft at irregular

intervals at the low power and invagination of the distal hair shaft into the bulging proximal hair shaft in the high power (Figure 5), suggesting trichorrhexis invaginata. Histopathological examination of the lesional skin revealed non-specific dermatitis. Thus the diagnosis of Netherton's syndrome was made due the classical history and examination findings, suggestive of congenital ichthyosiform erythroderma, Ichthyosis linearis circumflexa, atopic diathesis, and trichorrhexis invaginata.

Figure 1. Clinical photograph of the thigh showing multiple erythematous annular plaques with polycyclic margins showing double-edge scales at the periphery. The skin appears dry and scaly with multiple pink to violaceous striae.

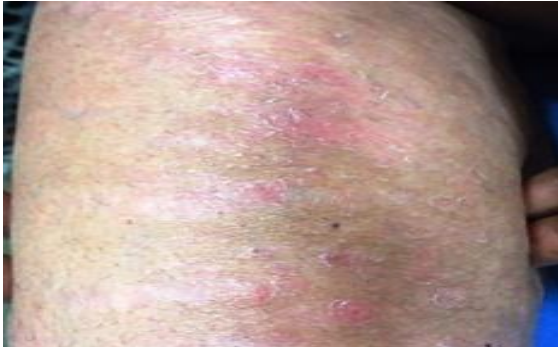

Figure 2. Clinical photograph of the scalp showing multiple broken hairs with nodular beaded thickening at irregular intervals.

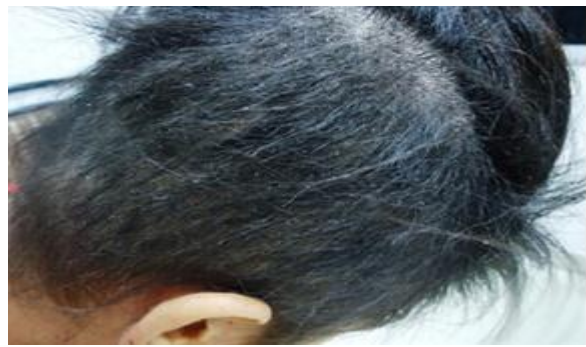

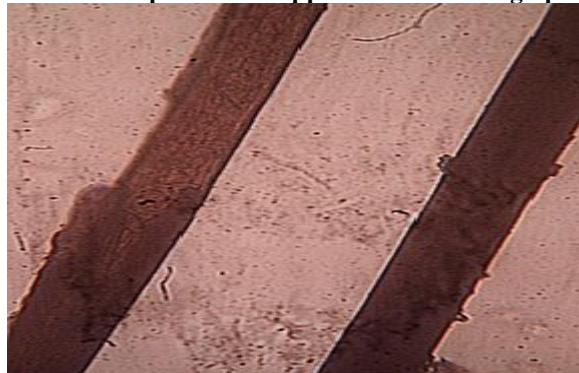
Figure 3. Light microscopy of the hair reveals acute angulation of hair over nodular thickening and the broken distal end in the scanning view giving an appearance of 'Bamboo hair'.



Figure 4. Light microscopy of the hair shows shows nodular thickening of hair at low power.



Figure 5. Light microscopy of the hair showing the invagination of the distal hair shaft into the proximal hair shaft in the form of 'Cup and ball' appearance in the high power.



DISCUSSION

Netherton syndrome has been reported in all the races with increase preponderance of trichorrhexis invaginata in females. The incidence is reported as 1 in 2,00,000 [5]. The usual age of onset is between one to six weeks of birth as congenital ichthyosiform erythroderma. The mutations are linked to both the copies of the *SPINK 5* genes which are localized to band 5q31-32 [4, 5, and 6]. This gene encodes the serine protease inhibitor [6] LEKTI (lympho-epithelial Kazal-type- inhibitor). The loss of LEKTI results in increased protease activity [6] of the stratum corneum resulting in chronic inflammation, increased scaling and exfoliation, predisposing these patients to life-threatening infections and dehydration.

Manifestations of the skin and associated symptoms vary considerably among the individuals with Netherton's syndrome. There is failure to thrive as a consequence of dermopathic enteropathy [7] in a few subjects resulting in chronic diarrhoea. Most children improve by the age of two and subsequently develop allergic manifestation to certain foods [8]. There is a strong positive family history of atopic diathesis and can manifest as atopic dermatitis, hay fever, allergic rhinitis and bronchial asthma. Ichthyosis linearis circumflexa is usually seen after the age of two and is characterized by serpiginous migratory, annular or polycyclic rash with double-edged scale [3]. They are usually short-lived followed by complete clearance. The hairs in these patients are generally sparse, short, spiky, lusterless and brittle. The scalp hair grows for a few centimetres before breaking. Some patients show reduced and fragile body hair. The light microscopy [9] of the hair reveals the expanded proximal hair shaft as a cup in which accommodates the distal hair shaft as a ball and this has been referred to as Trichorrhexis invaginata or the cup-and-ball hair-shaft

deformity also known as bamboo hair [2]. This invagination is secondary to the hair cortical weakness due to defective conversion of the sulfhydryl (-SH) group into disulfide bonds in the protein of the cortical fibres. The site of fracture in hairs is the weak junctions and is described as 'golf tee hairs' [10]. Early involvement of eyebrows and eyelashes is seen and there diagnostic role has been reported [11].

Management is mainly conservative. Keratolytics, emollients, antibiotics & hydration are the mainstay of treatment. Equal proportions of soft paraffin and liquid paraffin have been used as a topical treatment. Moderate potency topical steroids, 12% lactic acid [12], Pimecrolimus [13] 1% cream, PUVA and NBUVB [14] are reported to be effective.

CONCLUSION

This case is reported for the rare occurrence of the syndrome, also highlighting the prevalence of steroid abuse and poor quality of life among people affected with the syndrome.

ACKNOWLEDGEMENT: NIL

CONFLICT OF INTEREST:

The authors declare that they have no conflict of interest.

STATEMENT OF HUMAN AND ANIMAL RIGHTS

All procedures performed in human participants were in accordance with the ethical standards of the institutional research committee and with the 1964 Helsinki declaration and its later amendments or comparable ethical standards. This article does not contain any studies with animals performed by any of the authors.

REFERENCES

1. Ali M, Marks R, Young E, et al. (1998). Netherton's syndrome. A familial occurrence. *Br J Dermatol*, 226-271.
2. Netherton EW. (1958). A unique case of trichorrhexis nodosa, bamboo hairs. *AMA Arch Derm*, 78(4), 483-7.
3. Mevorah B, Frenk E, Brooke EM, comel. (1974). Ichthyosis linearis circumflexa, a clinico-statistical approach to its relationship with Netherton's syndrome. *Dermatologica*, 149(4), 201-9.
4. Chavanas S, Garner C, Bodemer C, et al. (2000). Localization of the Netherton syndrome gene to chromosome 5q32, by linkage analysis and homozygosity mapping. *Am J Hum Genet*, 66(3), 914-21.
5. Emmanuelle Bitoun, Alain Hovnanian, et al. (2002). Netherton Syndrome, Disease Expression and Spectrum of *SPINK5* Mutations in 21 Families, *Journal of Investigative Dermatology*, 118, 352-361.
6. Komatsu N, Saijoh K, Jayakumar A, et al. (2008). Correlation between *SPINK5* gene mutations and clinical manifestations in Netherton syndrome patients. *J Invest Dermatol*, 128(5), 1148-59.
7. Fartasch M, Williams ML, Elias PM. (1999). Altered lamellar body secretion and stratum corneum membrane structure in Netherton syndrome, differentiation from other infantile erythrodermas and pathogenic implications. *Arch Dermatol*, 135(7), 823-32.
8. Judge MR, Morgan G, Harper JI. (1994). A clinical and immunological study of Netherton's syndrome. *Br J Dermatol*, 131, 615-21.
9. Burk C, Hu S, Lee C, Connelly EA. (2008). Netherton syndrome and trichorrhexis invaginata--a novel diagnostic approach. *Pediatr Dermatol*, 25(2), 287-8.
10. De Berker DA, Paige DG, Ferguson DJ, Dawber RP. (1995). Golf tee hairs in Netherton disease. *Pediatr Dermatol*, 12(1), 7-11.



11. Powell J. (2000). Increasing the likelihood of early diagnosis of Netherton syndrome by simple examination of eyebrow hairs. *Arch Dermatol*, 136(3), 423-4.
12. Wehr RF, Hickman J, Krochmal L. (1988). Effective treatment of Netherton's syndrome with 12% lactate lotion. *J Am Acad Dermatol*, 19(1 Pt 1), 140-2.
13. Yan AC, Honig PJ, Ming ME, Weber J, Shah KN. (2010). The safety and efficacy of pimecrolimus, 1%, cream for the treatment of Netherton syndrome, results from an exploratory study. *Arch Dermatol*, 146(1), 57-62.
14. Maatouk I, Moutran R, Tomb R. (2012). Narrowband ultraviolet B phototherapy associated with improvement in Netherton syndrome. *Clin Exp Dermatol*, 37(4), 364-6.

