



## ANAESTHESIA MANAGEMENT OF EXCISION OF LARGE VALLECULAR (EPIGLOTTIS) CYST

Sandhya Gujar<sup>1\*</sup>, Sucheta Meshram<sup>2</sup>, Tejas Bhandari<sup>3</sup>, Kruti Mehata<sup>3</sup>

<sup>1</sup>Professor and HOD, <sup>2</sup>Specialist in Anaesthesia, <sup>3</sup>JR in Anaesthesia,  
<sup>3</sup>JR in Anesthesia, ESI-PGIMSR, Andheri, Mumbai-400093, Maharashtra, India.

Corresponding Author:- **Sandhya Gujar**  
E-mail: [drsandhyagujar@gmail.com](mailto:drsandhyagujar@gmail.com)

<p><b>Article Info</b></p> <p>Received 15/08/2015 Revised 27/08/2015 Accepted 12/09/2015</p> <p><b>Key words:</b> Airway Surgery, Epiglottic cyst, Fiberoptic Intubation</p>	<p><b>ABSTRACT</b></p> <p>Young 37 yr old male patient came for excision of large epiglottis cyst at vallecular area immediately above base of epiglottis. ASA grade I patient with no positive history in past was posted for excision of cyst under G.A. IDL was done, maintaining protocol of difficult intubation, it was decided to do awake FIBROPTIC INTUBATION with nasal armored tube. After thorough preparation for fiberoptic intubation like 4 % xylocaine viscous gargles, otrivin nasal drops and intratracheal injection of 2% xylocaine 6.5 no armored tube was passed nasally. Patient was induced with inj.profofol and maintained on inj atracurium with IPPV and O2: N2O and Sevoflurane .as surgery was proceeded with complete excision of cyst base of epiglottis was getting thinned out hence patient was monitored meticulously for any untoward events such as fire hazards of airway after excision of cyst pt. was reversed and it was decided to keep pt on t'piece with 4 liter of oxygen in postop. Period for 24 hrs .to increase tolerance of tube and decrease symph .response pt. sedated within buprenorphine 90 µg IV 12 hrly. Pt was very much comfortable, conscious and oriented in immediate postop period.</p>
--	--

### INTRODUCTION

Large Epiglottis cysts are rare and often benign lesion .they present with symptoms of airway obstruction like stridor,chronic cough ,dysphagia,foreign body sensation .sometimes asymptomatic cyst are usually discovered with unanticipated difficult intubation following muscle relaxant causing cyst to enter airway or during otolaryngological examination ,or at post-mortem.

In our case pt had symptoms of airway obstruction and was diagnosed to have large epiglottis cyst on IDL posted for excision of cyst with microdebrider with monitor

Any pt with respiratory symptoms should be thoroughly investigated to rule out possibility of airway cyst which can be lifethreatening.

### Case report

A 37-year-old male weighing 49 kg presented with dysphasia, change in voice and occasionally dyspnoea on exertion since 6 months. External examination of the neck revealed a cystic swelling 3 cm x 2 cm on right side near hyoid bone. Examination of the oral cavity showed a globular cystic swelling arising from hypo pharynx behind the tongue. On Indirect laryngoscopy, the vocal cords could not be visualized as cyst was filling the entire hypo pharynx. Pt was ASA grade I, no other positive history, Mouth opening was adequate. Mallampatti score was Grade I. CT scan showed a cystic lesion 3.9 cm x 2.8 cm in the region of epiglottis. Marinating protocols for difficult intubation, it was decided to awake fiberoptic intubation. The patient was kept fasting for 10 hours pre-operatively. Informed consent for the procedure and emergency



tracheostomy was taken. The upper airway was prepared as follows:

- i. Premedication: Glycopyrrolate 0.2 mg intramuscularly with emset iv
- ii. Otrivin drops to decongest nostrils. Gargles with 2% Lignocaine viscous
- iii. 4% Lignocaine nebulisation.
- iv. Bilateral superior laryngeal nerve blocks
- v. 2% Lignoadrenaline packs in both nostrils
- vi. 2% Lignocaine transtracheal injected up to 2 ml

A cuffed No.6.5 PVC endotracheal tube was threaded over a fibrotic endoscope. Tip of the scope and tube were lubricated with 2% Lignocaine jelly. After preoxygenation with 100% oxygen, the scope was introduced through one of the nostrils and advanced. Rupture of the cyst had to be avoided. It was difficult to visualize laryngeal inlet. The scope was advanced till the carina was reached. The tracheal rings were identified. The endotracheal tube was now railroaded over the scope, passed through the vocal cords and placed in the trachea without rupturing the cyst. Anaesthesia was induced with Propofol 2 mg /kg and atracurium 0.5 mg /kg was given to maintain intraoperative muscle relaxation. Miadozolam 0.03 mg/kg-1 and Fentanyl 50 µg were given for sedation and analgesia

respectively. Maintenance was with O<sub>2</sub>: N<sub>2</sub>O (40:60) and Sevoflurane 2 to 3 % to end tidal levels at 1.5 MAC.

As surgery proceeded with attempt to excise cyst completely base of epiglottis was getting thinned out. Hence pt was monitored meticulously for untoward hazards like epiglottis getting cut completely, as well as fire hazards because of cautery and oxygen if there is rupture of epiglottis reaching ETTUBE.

Intraoperative Period-patient maintained vital parameters normally.

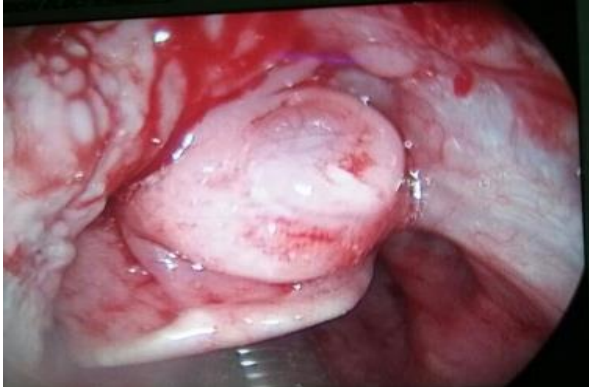POST OP.-Pt was reversed routinely after return of spontaneous muscle power .but as it was surgery of airway it was decided to keep patient on t'piece with 6 liters of oxygen

To increase tolerance of tube and decrease sympathetic response and associated hypertension and tachycardia patient was sedated with inj .buprenorphine 90 µg iv.

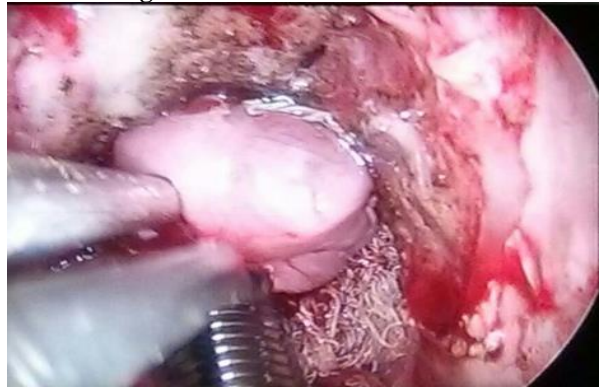Pt was very much comfortable and conscious, oriented and obeying oral commands.

Pt was extubated next day after thorough suctioning of endotracheal tube .patient was observed for any airway obstruction in postop period.

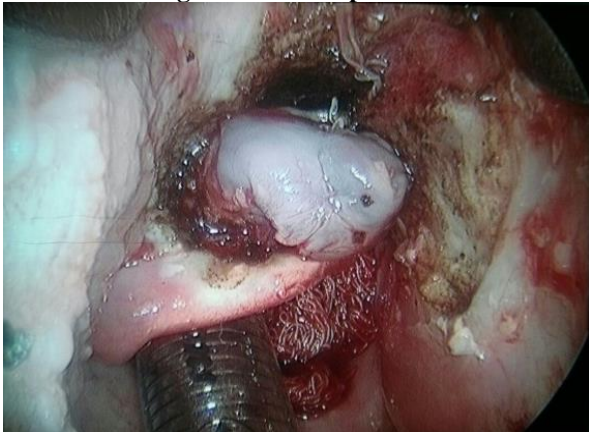
**Figure 1. Epiglottis Cyst**



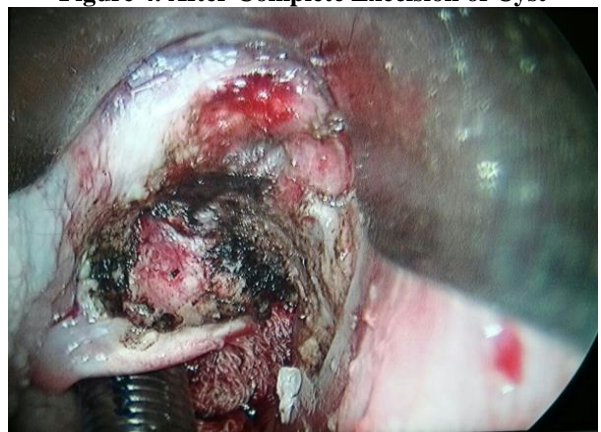
**Figure 2. Armoured Tube in-situ**



**Figure 3. Intra Operative**



**Figure 4. After Complete Excision of Cyst**



## DISCUSSION AND CONCLUSION

Known case of epiglottis cyst for surgery and anaesthesia has become easier with fibreoptic intubation; otherwise pt may risk loss of airway rupture of cyst obscuring views of larynx at intubation and potential aspiration of cyst content. Most of time these pt are easy for mask ventilation which can avoid catastrophes fall in saturation, Because of difficulty in intubation. When it is unexpected finding people have tried with large McCoy laryngoscope and ENT rigid laryngoscope Unexpected findings of epiglottis cyst should be kept in as one of reasons of difficult to ventilate and intubate.

**ACKNOWLEDGEMENT:** None

## REFERENCES

1. Lam H9C, Abdullah VJ, Soo G. (2000). Epiglottis cyst. *Otolaryngology Head Neck Surg*, 122(2), 311.
2. Flint PW. (2000). Powered surgical instruments for laryngeal surgery. *Otolaryngology Head Neck Surg*, 122(2), 263–266.
3. Adelsmayr E, Keller C, Erd G et al. (1998). The laryngeal mask and high-frequency jet ventilation for resection of high tracheal stenosis. *Anesth Analg*, 86, 907.
4. Brimacombe J, Dunbar-Reid K. (1996). The effect of introducing fiberoptic bronchoscopes on gas flow in laryngeal masks and tracheal tubes. *Anaesthesia*, 51, 923.
5. Brooker CR, Hunsaker DH, Zimmerman AA. (1998). A new anesthetic system for microlaryngeal surgery. *Otolaryngol Head Neck Surg*, 118, 55.
6. Gronnebech H, Johansson G, Smedebol M et al. (1993). Glycopyrrolate versus atropine during anaesthesia for laryngoscopy and bronchoscopy. *Acta Anesthesiol Scand*, 37, 454.
7. Kovacs S. (1957). Method of ventilation during bronchoscopy. *Anesthesiology*, 18, 335.
8. Perera ER, Mallon JS. (1987). General anaesthetic management for laser resection of central airway lesions in 85 procedures. *Can J Anaesth*, 34, 383.
9. Warner MA, Warner MA, Weber JG. (1993). Clinical significance of pulmonary aspiration during the perioperative period. *Anesthesiology*, 78, 58.

## CONFLICT OF INTEREST:

The authors declare that they have no conflict of interest.

## STATEMENT OF HUMAN AND ANIMAL RIGHTS

All procedures performed in human participants were in accordance with the ethical standards of the institutional research committee and with the 1964 Helsinki declaration and its later amendments or comparable ethical standards. This article does not contain any studies with animals performed by any of the authors.

