



ARYTENOID DISLOCATION OCCURRING IN TWO CONSECUTIVE ENDOTRACHEAL INTUBATIONS

Ho-Kyung Song^{1*} and Soon Ju Baek²

¹Professor, Dept of Anesthesia and Pain Medicine,

²Residency, Dept of Anesthesia and Pain Medicine, Incheon St. Mary's Hospital, College of Medicine, The Catholic University of Korea, #56 Dongsu-ro, Bupyeong-gu, Incheon, Republic of Korea.

Corresponding Author: **Ho-Kyung Song**
E-mail: genovia@catholic.ac.kr

<p>Article Info <i>Received 15/08/2015</i> <i>Revised 27/08/2015</i> <i>Accepted 02/09/2015</i></p> <p>Key words: Postoperative hoarseness, Endotracheal intubation, arytenoid cartilage dislocation.</p>	<p>ABSTRACT</p> <p>In case of persistent hoarseness after endotracheal intubation, specialists should consider arytenoid cartilage dislocation/subluxation as an unusual complication of intubation because the cricoarytenoid joint is prone to dislocation/subluxation by anatomically synovial-lined diarthrodial joint. Cases are misdiagnosed as vocal cord paresis, laryngeal edema or laryngospasm, and thus, early diagnosis and reduction of dislocation are important. We present a case of arytenoid cartilage dislocation caused by endotracheal intubation which was occurred in succession of shorter elapsed time a week in a patient who had no specific clinical conditions or risk factors for arytenoid cartilage dislocation.</p>
--	--

INTRODUCTION

Postoperative hoarseness is a common complication after tracheal intubation. The incidence varies widely from 16% to 55% [1]. Symptoms are temporary and improve within several days in most cases [2]. Endotracheal intubation may lead submucosal hemorrhage, granuloma formation, subglottic edema. These complications are also characterized by hoarseness or stridor [3]. In case of persistent hoarseness, specialists should also consider arytenoid cartilage dislocation/subluxation as an unusual complication of intubation. The incidence is reported to occur in 0.1% of intubation [2], however, it is probably higher than reported because the cricoarytenoid joint is prone to dislocation/subluxation by anatomically synovial-lined diarthrodial joint [4,5].

Cases are misdiagnosed as vocal cord paresis, laryngeal edema or laryngospasm [4,6]. Thus, early diagnosis and reduction of arytenoid dislocation are important [7].

In this report, we present a case of arytenoid cartilage dislocation caused by endotracheal intubation which was occurred in succession of shorter elapsed time a week in a patient who had no specific clinical conditions or risk factors for arytenoid cartilage dislocation. The patient consent was not achieved because she did not visit OPD anymore since when the symptom was resolve in Oct. 2014. In place of written consent, we obtained the Institutional ethics board approval (OC15ZISE0063) as the case was exempted from getting the patient consent.

CASE

A 77-year-old, 50 kg female with hypertension and dyslipidemia was scheduled for a right side total knee replacement arthroplasty (TKRA) under general anesthesia. She had no history of laryngeal disorders but had received a lumbar spine surgery one year before. There was no apparent diabetes mellitus, chronic renal failure, chronic corticosteroid use, laryngeal malacia, acromegaly



or other factors that might weaken the cricoarytenoid joint. Her past medical history, physical examination and laboratory examination were unremarkable (preoperative physical status classification of patients according to the American Society of Anesthesiologists; ASA II). Airway assessment showed a modified Mallampati class 2 and slight limitation of neck extension. After securing intravenous access and beginning standard monitoring, anesthesia was induced with propofol (2 mg.kg-1) and rocuronium (0.6 mg.kg-1) intravenously. After sufficient depth of anesthesia and complete muscle relaxation was achieved, direct laryngoscopy (Macintosh 4 laryngoscope blade) revealed a Grade II (Cormack-Lahene) laryngeal view. On the first attempt, a 7.0-mm Mallinckrodt endotracheal tube was inserted without stylet. The patient did not cough during the intubation. During the 4-hour operative procedure, anesthesia was maintained with nitrous oxide, oxygen and propofol. Upon completion of surgery, the endotracheal tube cuff was deflated and removed without any difficulty, coughing or vomiting. She had no complaints of hoarseness or coughing postoperatively.

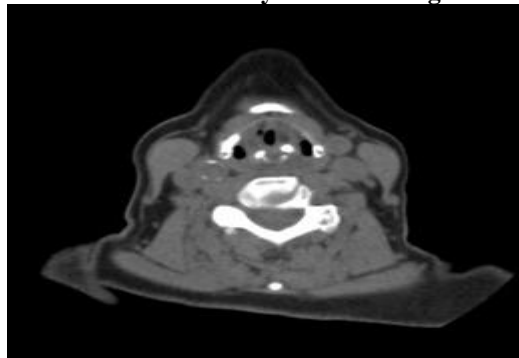
After a week, she returned to operation room for left side TKRA. Anesthesia was induced by the same way as the first case. However, at this time, a 7.0-mm endotracheal tube was barely able to be inserted, and we decided to a smaller diameter of 6.5 mm.

On the 6th postoperative day, the patient complained of persistent hoarseness, aspiration on liquid, acid belching and dysphagia. There was no evidence of respiratory distress and SpO2 remained at 97% to room air. Auscultation of the chest demonstrated good alveolar air entry without wheezing but inspiratory stridor was noticed in auscultation of the larynx. The findings of flexible fiberoptic laryngoscopy showing anteromedial dislocation of the left arytenoids cartilage raised the possibility of arytenoids subluxation/dislocation as a more likely diagnosis than airway edema or vocal cord paresis. Neck computed tomography (CT) also showed anteromedial dislocation of the left arytenoids cartilage without any abnormal findings on thyroid cartilage, cricoid cartilage and laryngeal soft tissue (Figure 1).

Closed reduction under the general anesthesia was scheduled. In the Boyce position, the larynx was exposed using a Nagashima laryngoscope and close reduction was performed with laryngeal forceps under operating microscope. But, hoarseness persisted. We suggested injection laryngoplasty, but the patients refused more intervention.

The patient's hoarseness resolved spontaneously over the next two months without further treatment. Vocal cord movement and dysphagia were fully recovered in 4 months after intervention.

Fig. 1. Neck CT shows anteromedial dislocation of left arytenoid cartilage and medial fixation of the left vocal cord



DISCUSSION AND CONCLUSION

The cricoarytenoid joint is a synovial joint and the pyramidal shape arytenoid provides extended movement of the cartilage. In addition, the arytenoid cartilage is supported by the posterior crico-arytenoid ligament and the intrinsic muscles of the larynx. The cricoarytenoid joint also contains large, well-vascularized, synovial folds. Thus, trauma to the cricoarytenoid joints may lead to joint cavity hemorrhage or serosynovitis. After this, adhesion of articular surfaces or periarticular structures can follow that fix the arytenoid in an abnormal position leading vocal fold immobility [3]. Intubation trauma is the most common etiologic factor related to direct laryngoscopy under incomplete neuromuscular blockage or motor reactions during intubation. The use of a laryngeal mask airway,

lighted stylet, McCoy laryngoscope and double lumen tube, difficult intubation, blind instrumentation of the esophagus with a rigid nasogastric tube and transesophageal echocardiogram probe are also associated with arytenoid dislocation [2,5]. Some clinical conditions including laryngomalacia, diabetes mellitus, chronic renal failure, acromegaly and chronic steroid use might increase the risk of arytenoid dislocation by weakening the joint capsule [3].

In the present case, there was no history contributing the degeneration of the cricoarytenoid joint or factors for difficulties in intubation. Gastric catheter was not inserted and the patient did not cough during intubation. Intubation-related laryngeal trauma predominates in anteromedial dislocations [7]. Trauma can



be caused directly by the blade of a laryngoscope as it is inserted and lifted in an anterior direction. It is also possible that a misdirected endotracheal tube tip or stylet knocking into the arytenoids for the glottic opening could be a factor. Hence, a conclusive view of the laryngeal inlet including the position of the arytenoids is important prior to intubation.

Though we changed the endotracheal tube with smaller diameter (6.5-mm) than previous endotracheal tube, it is assumed that intubations occurring in succession a week apart and with somehow larger endotracheal tube than patients size or subsequent intubation on edematous larynx could be factors for the complication in this case [8]. In fact, the cause of arytenoid cartilage dislocation might not induced by direct trauma such as intubation. The intubation conditions and intraoperative factors are known to influence on pH and thus, long duration of surgery may lead to vocal cord sequelae by mucosal damage from endotracheal intubation or changes in pH [1]. The primary reporting complaints of arytenoid dislocation present hoarseness, vocal fatigue, stridor, dysphagia, odynophagia and sore throat [4,5,9]. Our patient was prone to hoarseness, being old, female and the recipient of a long operation [2]. In addition to hoarseness, she also presented dysphagia, which is a less common symptom. Dysphagia and odynophagia are similar presenting conditions under laryngeal edema, laryngospasm or recurrent laryngeal nerve paralysis [9]. In cases where endoscopic evaluation of the larynx is obscured by edema and hematoma,

imaging techniques such as computed tomography and magnetic resonance imaging may be useful [10]. In addition, electromyography of the laryngeal musculature is helpful in distinguishing a neurologic from a joint abnormality [11]. Flexible fiberoptic laryngoscope and neck CT of the present case showing abnormal vocal cord mobility and loss of arytenoid symmetry suggested the possibility of arytenoids dislocation.

Spontaneous resolution of symptoms by arytenoid repositioning may occur during forceful laryngeal maneuvers, such as coughing or emesis [12] though, anesthetists should be aware of the necessity of early diagnosis and surgical intervention. In order not to lead fibrotic ankylosis of the joint, close reduction within 21 days is needed for superior recovery and favorable clinical outcome [7]. In the present case, closed reduction under general anesthesia was ineffective. It is known that only 21% of patients showed immediate improvement. The majority of reported cases of arytenoid dislocation/subluxation showed delayed (6 months) or no improvement after closed reduction [6].

Even following the regular intubation, it is important that the anesthesiologist should suspect the injury to the cricoarytenoid joints in case of persistent hoarseness and accomplish closed reduction as soon as possible after the recognition of arytenoid dislocation.

ACKNOWLEDGEMENT: NIL

CONFLICT OF INTEREST: NIL

REFERENCES

1. Mencke T, Echternach M, Kleinschmidt S, Lux P, Barth V, Plinkert PK, Fuchs-Buder T. (2003). Laryngeal morbidity and quality of tracheal intubation. A randomized controlled trial. *Anesthesiology*, 98, 1049-1056.
2. Yamanaka H, Hayashi Y, Watanabe Y, Uematu H, Mashimo T. (2009). Prolonged hoarseness and arytenoid cartilage dislocation after tracheal intubation. *Br J Anaesth*, 103, 452-455.
3. Paulsen FP, Rudert HH, Tillmann BN. (1999). New Insights into the Pathomechanism of Postintubation Arytenoid Subluxation. *Anesthesiology*, 91, 659-666.
4. Hoffman HT, Brunberg JA, Winter P, Sullivan MJ, Kileny PR. (1991). Arytenoid subluxation: diagnosis and treatment. *Ann Otol Rhinol Laryngol*, 100(1), 1-9.
5. Rubin AD, Hawkshaw MJ, Moyer CA, Dean CM, Sataloff RT. (2005). Arytenoid cartilage dislocation: a 20-year experience. *J Voice*, 19, 687-701.
6. Norris BK, Schweinfurth JM. (2011). Arytenoid dislocation: An analysis of the contemporary literature. *Laryngoscope*, 121(1), 142-146.
7. Lee SW, Park KN, Welham NV. (2014). Clinical features and surgical outcomes following closed reduction of arytenoid dislocation. *JAMA Otolaryngol Head Neck Surg*, 140(11), 1045-1050.
8. Mikuni I, Suzuki A, Takahata O, Fujita S, Otomo S, Iwasaki H. (2006). Arytenoid cartilage dislocation caused by a double-lumen endo-bronchial tube. *Br J Anaesth*, 96(1), 136-138.
9. Tan V, Seevanayagam S. (2009). Arytenoid subluxation after a difficult intubation treated successfully with voice therapy. *Anaesth Intensive Care*, 37, 843-846.
10. Alexander AE Jr, Lyons GD, Fazekas-May MA, Rigby PL, Nuss DW, David L, Williams K. (1997). Utility of helical computed tomography in the study of arytenoid dislocation and arytenoid subluxation. *Ann Otol Rhinol Laryngol*, 106(12), 1020-1023.
11. Munin MC, Murry T, Rosen CA. (2000). Laryngeal electromyography: diagnostic and prognostic applications. *Otolaryngol Clin North Am*, 33(4), 759-770.
12. Gauss A, Treiber HS, Haehnel J, Johannsen HS. (1993). Spontaneous reposition of a dislocated arytenoid cartilage. *Br J Anaesth*, 70(5), 591-592.

