



## CONGENITAL CUTANEOUS CANDIDIASIS REPORTED IN AN 8-DAY OLD NEONATE FROM A PRIVATE HOSPITAL IN HUBLI, KARNATAKA

Mohammed Ashraf Ali Namaji<sup>1\*</sup> and Sharon V A<sup>2</sup>

<sup>1</sup>Consultant Microbiologist, Shifa Diagnostic Center, Navanagar, Hubli-580025, Karnataka, India.

<sup>2</sup>Post graduate, Department of Microbiology, Karnataka Institute of Medical Sciences, Hubli, Karnataka, India.

Corresponding Author:- **Mohammed Ashraf Ali Namaji**

**E-mail:** ashrafnamaji@gmail.com

### Article Info

Received 15/08/2015

Revised 27/08/2015

Accepted 02/09/2015

### Key words:

Congenital cutaneous candidiasis, *Candida albicans* in neonates, Candida infection in Pregnancy

### ABSTRACT

An 8 day old neonate was brought to the outpatient department with history of developing generalised erythematous macular eruptions over body especially on trunk, back (Fig:1) and extremities, sparing face, palms, soles and buccal mucosa since the 3rd day of birth. Few lesions had fine scaling. The eruptions soon became confluent at some sites and progressed to vesicles and pustules. The child was active with no other systemic manifestations

### INTRODUCTION

Nearly one-fourth of pregnant women are colonized by *Candida albicans* in their vaginal flora. *Candida albicans* is a frequent pathogen of the female genital tract, especially during pregnancy [1]. The Congenital Cutaneous Candidiasis is a disease of the newborn which is secondary to a chorioamnionitis caused due to *Candida* [2].

### CASE REPORT

An 8 day old neonate was brought to the outpatient department with history of developing generalised erythematous macular eruptions over body especially on trunk, back (Fig:1) and extremities, sparing face, palms, soles and buccal mucosa since the 3rd day of birth. Few lesions had fine scaling. The eruptions soon became confluent at some sites and progressed to vesicles and pustules. The child was active with no other systemic manifestations. A comprehensive history was taken from the mother; a 19 year old woman para 1 living 1. The

antenatal period was uneventful except for a history of recurrent UTI treated with antibiotics given by a local practitioner. Later she developed pruritis and curdy white discharge per vaginum since 30 weeks of gestation. Mother was seronegative for Venereal Disease Research Laboratory (VDRL) test and Human Immunodeficiency Virus (HIV). There were no h/o rashes in the mother or exposure to chickenpox in the perinatal period. An emergency lower segment caesarean section was performed at 34 weeks of gestation with an indication of prolonged rupture of membranes and a 1.9 kg female baby was delivered. The baby cried immediately and was well at birth. Skin scraping and vesicle fluid were collected and subjected to direct (KOH) mount microscopic examination. Budding yeast-like cells with pseudohyphae were demonstrated (Fig 2). Gram's stain revealed Gram positive budding yeast like cells (Fig 3). Simultaneously the sample was also inoculated onto Blood agar (BA) and Sabouraud's dextrose agar (SDA) with antibiotics and incubated at 37°



C and 25°C, respectively. After 24 hrs of incubation white creamy pasty colonies were observed on BA (Fig 4) and SDA. The isolate was identified as *Candida albicans* on the basis of gram's staining, positive germ tube test (GTT), demonstration of blastoconidia, chlamydoconidia on the Corn meal agar (Fig 5) and sugar assimilation and fermentation tests. Total leucocyte counts and differential leucocyte counts were within normal limits. Mother was tested seronegative for Toxoplasma, Rubella, Cytomegalovirus, Herpes simplex (TORCH) test. A high vaginal swab collected from mother demonstrated the presence of *C. albicans* on culture. The diagnosis of CCC was made on the basis of clinical picture and relevant microbiological investigations. Clotrimazole (1%) cream was applied on the lesions which resulted in a dramatic improvement and lesions healed with superficial desquamation of the involved skin after approximately four days. Despite the frequency and ease with which *Candida* species are isolated from the genital tracts of pregnant patients, antenatal fetal infections with this group of organisms are rare. In our case, the mother had recurrent episodes of UTI, and was treated with antibiotics by a local doctor without culture and drug susceptibility reports. This has favoured the colonization of vagina with *Candida*.

#### Mode of acquisition

Neonatal candidiasis can either be acquired

- at birth, by delivery through an infected canal, or
- postnatally from nursery contacts [3].

However, cutaneous congenital candidiasis (CCC) is frequently secondary to *Candida* chorioamnionitis caused by an ascending infection from vagina which is considered the mechanism of fetal infection [4].

In our case the baby might have acquired the infection following prolonged rupture of membranes and has not shown any signs of infection until the first week of life

#### Risk factors for CCC:

- Preterm babies especially in extremely low and very low birth weight infants, defined as birth weights below 1000 g and 1500 g, respectively.
- Foreign intrauterine bodies such as intrauterine devices and cervical cerclage.
- Prolonged rupture of membranes

One case of CCC infection has been reported from an apparently healthy mother without risk factors. The mother showed no evidence of abnormal vaginal discharge or presence of *Candida* in her cytological exam.

#### Clinical features

- CCC can occur as an asymptomatic infection or as a disseminated infection
- The most common presentation is a cutaneous generalized eruption of erythematous macules, papules, and/or pustules, with a benign outcome [5,6]

The baby showed characteristic eruptions covering the trunk, extremities as described in the literature.

#### Epidemiology

- CCC is a rare condition with less than 150 cases reported till date. However it may occur more frequently than is indicated by the literature because the condition may remain unrecognized related to the commonly self-limited course.<sup>[1,7]</sup>

#### Differential Diagnosis

The differential diagnosis like erythema toxicum, transient neonatal pustular melanosis, drug eruptions, and infections such as syphilis were ruled out in our case with comprehensive history taking and relevant microbiological tests.

#### RESULTS

The following microbiological techniques helped in arriving at the diagnosis of *Candida albicans* infection.

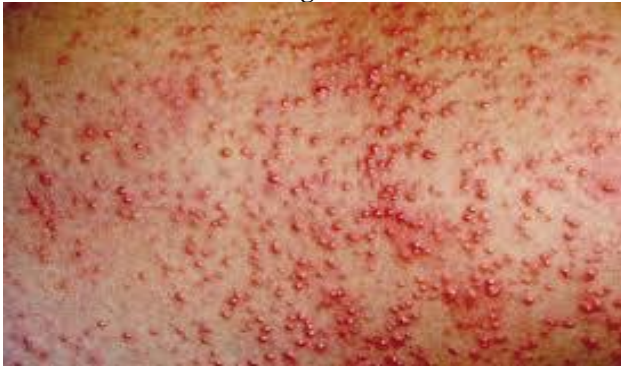1. Microscopy
  - i. Gram staining (Fig: 3) – Gram positive budding yeast cells with pseudohyphae seen
  - ii. KOH mount (Fig: 2) – Budding yeast cells seen
2. Culture
  - i. Blood Agar (Fig: 4)-  
Colonies were dry, around 1-2mm, low convex smooth with entire edges, no haemolysis seen
  - ii. Sabouraud's Dextrose Agar  
Creamy colonies were seen, which were dry and confluent
3. Confirmation of isolate
  - i. Germ tube testing- Positive
  - ii. Corn meal Agar (Dalmu plate technique) (Fig :5)  
Blastoconidia seen in clusters along the pseudohyphae placed irregularly, single terminal chlamydoconidia were seen.

#### Treatment

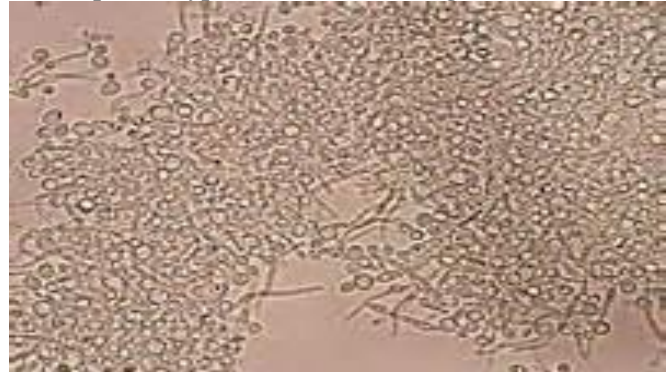
- The patient responded to topical therapy alone with Clotrimazole (1%) cream.
- There was no indication for systemic antifungal therapy as the lesions were only topical.



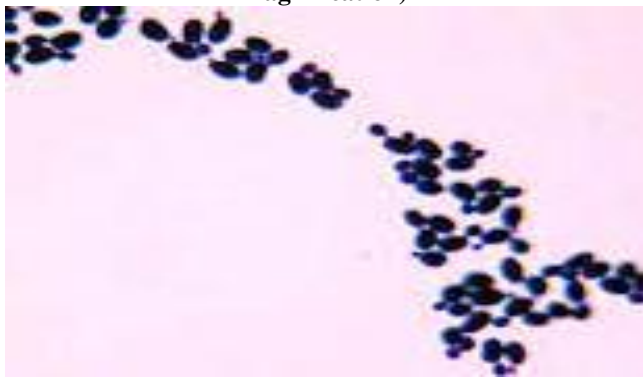
**Figure 1. Erythematous rash over the back and loin region**



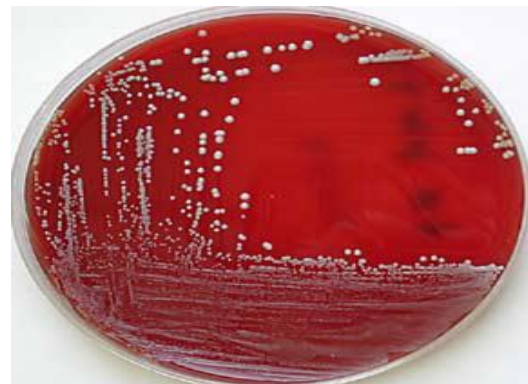**Figure 2. KOH mount showing yeast like cells with pseudohyphae (Under 40 X magnification).**



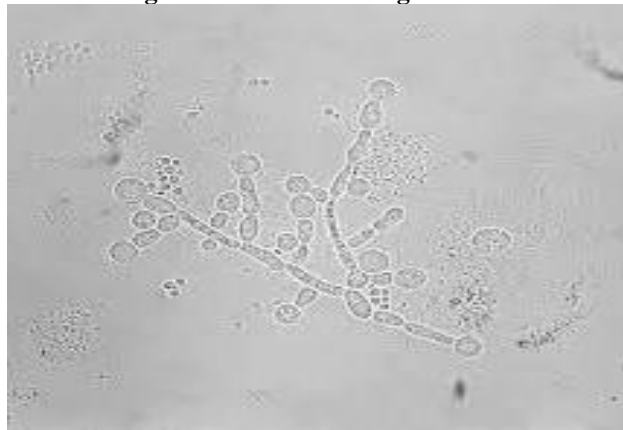**Figure 3. Gram staining showing Gram positive budding yeast-like cells with pseudohyphae (Under 100 X magnification)**



**Figure 4. Blood Agar showing cream coloured, dry colonies**



**Figure 5. Under 40X magnification**



Corn meal agar showing single Terminal Chlamydo spores and clusters of blastoconidia

### CONCLUSION

- Avoid inadvertent use of antibiotics in pregnant woman unless she is symptomatic, because it facilitates colonization of fungi especially Candida.
- Antenatal candidal infections should be diagnosed timely to prevent diseases like Congenital Cutaneous Candidiasis.
- Though a rare and unpredictable disease, CCC should always be as a differential diagnosis in a newborn

presenting with generalized rashes after 1<sup>st</sup> week of its birth.

**ACKNOWLEDGEMENT: NIL**

**CONFLICT OF INTEREST: NIL**

## REFERENCES

1. Bertha TA, Diana HB, Adriana EP, Juan Pablo CC. (2013). Cutaneous congenital Candidiasis in a full-term newborn from an asymptomatic mother. *Dermatology Online Journal*, 19(7), 13.
2. Whyte RK, Hussain Z, deSA D. (1982). Antenatal infections with *Candida* species. *Archives of Disease in Childhood*, 57, 528-35.
3. Lane AT. (1995). Cutaneous Candidiasis. *Pediatr Dermatol*, 12, 369.
4. Diana A, Epiney M, Ecoffey M, Pfister RE. (2004). White dots on the placenta and red dots on the baby, congenital cutaneous candidiasis –a rare disease of the neonate. *Acta Paediatrica*, 93, 996-99.
5. Darmstadt GL, Dinulos JG, Miller Z. (2000). Congenital cutaneous candidiasis, clinical presentation, pathogenesis and management guidelines. *Pediatrics*, 105, 438-44.
6. Broberg A, Thirnger K. (1989). Congenital cutaneous candidiasis. *Int J Dermatol*, 28, 464-65.
7. Jagtap SA, Saple PP, Dhaliat SB. (2011). Congenital cutaneous candidiasis, a rare and unpredictable disease. *Indian J Dermatol*, 56(1), 92-3.

