

## CASE REPORT ON “PEDIATRIC LUDWIGS ANGINA: A LIFE THREATENING ENTITY REVISITED”.

**Basavaraj C. Sikkerimath<sup>1</sup>, Niranjan S. Patil<sup>2\*</sup>, Semmia Mathivanan<sup>3</sup>,  
Mustafa I. Merchant<sup>2</sup>, Sriram Kaliamoorthy<sup>4</sup>**

<sup>1</sup>Prof & Head, Dept. of Oral & Maxillofacial Surgery, P.M.N.M. Dental College & Hospital, Bagalkot, Karnataka 587101.

<sup>2</sup>Consultant Oral and Maxillofacial Surgeon, <sup>4</sup>Oral and Maxillofacial Pathology, Senior Lecturer,

<sup>3</sup>Chettinad Dental College & Research Institute,

Chettinad Health City Campus, Kelambakkam, Kancheepuram District, Tamilnadu 603103, India.

### Article Info

Received 23/06/2015

Revised 16/07/2015

Accepted 19/08/2015

**Key words:-** Airway obstruction, Ludwig's angina, life-threatening, space infection.

### ABSTRACT

Space infection in the Oral and Maxillofacial region is common from odontogenic origin. Ludwig's angina which is relatively uncommon in the pediatric population remains a potentially life-threatening condition due to the risk of impending airway obstruction. Thus, because of its invasive nature, early identification and management of Ludwig's angina is extremely important. Late stages of the disease should be addressed immediately and given special importance towards the maintenance of airway followed by surgical decompression under antibiotic coverage. The appropriate use of parenteral antibiotics, airway protection techniques, and surgical drainage of the infection remains the standard protocol of treatment in advanced cases of Ludwig's angina. Here we present a case report on a child who was diagnosed with Ludwig's angina.

### INTRODUCTION

A rare disorder, Ludwig's angina is a serious, potentially life-threatening infection of the neck and the floor of the mouth. Originally described by Wilhelm Frederick von Ludwig in 1836 [1]. This condition is known for its aggressive behaviour, rapid progression to airway compromise, and high mortality when not treated promptly [2–6]. Ludwig's angina is a severe diffuse cellulitis that presents with an acute onset and spreads rapidly, affecting the submandibular, sublingual, and submental spaces bilaterally. Beginning with the submandibular space infection from second or third lower molar, it spreads to the sublingual space of the same side. From there it crosses to the opposite sublingual space and thence to the contralateral submandibular space. It can also start from sublingual space and progress to the

submandibular space. Infection from the sublingual space spreads posteriorly in the substance of the tongue in the cleft between the hypoglossus and genioglossus muscles and reaches epiglottis which causes edema of the glottis and respiratory obstruction [7]. Causes include odontogenic infection, osteomyelitis, penetrating injury of the floor of the mouth, compound fracture of the jaw, otitis media, submandibular gland sialadenitis, sialolithiasis. Of these causes, the major one is odontogenic infection, mainly from the second and third lower molar teeth [8]. In Ludwig's angina, patients demonstrate swelling in the floor of the mouth and neck, pain, malaise, fever, and dysphagia. In these patients, inability to swallow saliva and stridor indicate imminent airway compromise. Aggressive use of intravenous antibiotics and surgical decompression with removal of source of infection and airway management is mandatory to prevent mortality [10].

Corresponding Author

**Niranjan S. Patil**

Email: - [niranjanspatil01@gmail.com](mailto:niranjanspatil01@gmail.com)



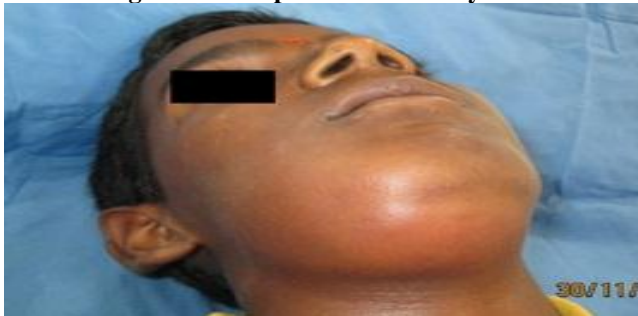## CASE REPORT

A 12 year old patient reported to the department of oral and maxillofacial surgery with a complaint of severe pain, large swelling in the lower part of the face and inability to open the mouth since past 5 days. On asking the patient revealed that he had applied hot fermentation to the affected area. Physical examination was suggestive that the patient was toxic in appearance.

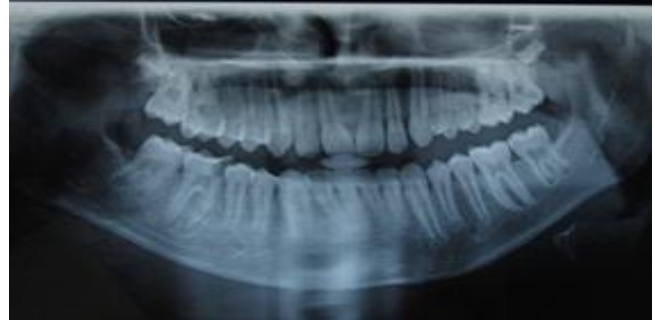
Vital signs were monitored immediately. It was found that the patient was febrile with a temperature of 100.5<sup>0</sup> F. pulse rate was 90 bpm, BP was 100/ 70 mm of Hg. Respiratory rate was 24 breaths per min. Mouth opening was limited to 1.2 cm (interincisal distance). Extra-oral swelling was indurated and non-fluctuant with bilateral involvement of the submandibular and sublingual region. An infected first molar was found to be the etiologic factor. Finally the diagnosis of Ludwig's Angina was made and the patient was posted for surgical decompression under local anesthesia with monitoring of oxygen saturation and vital signs. Blood picture revealed a

rise in ESR, total leucocyte count and neutrophil percentage. Intravenous access was established and fluids started with close monitoring for the amount of fluid infused per hour. The deeply carious first molar tooth was extracted. A stab incision was made in relation to the submandibular and submental space and a Sinus Forceps was introduced into the incision to open up the tissue spaces. Drainage of the pus was achieved and the abscess cavity was thoroughly irrigated with normal saline and povidone iodine solution. A corrugated rubber drain was secured in the cavity with 3-0 black braided silk for additional decompression. Intravenous administration of Augmentin 1.2 g T.D. (three times), Amikacin 250 mg B.D., ofloxacin in combination with ornidazole 100 mg B.D. , along with dexamethasone 4mg B.D. tapering were given for 5 days. Postoperative irrigation was done through the drain which was removed after 36 hr. Patient recovery was satisfactory. The neck swelling regressed spontaneously.

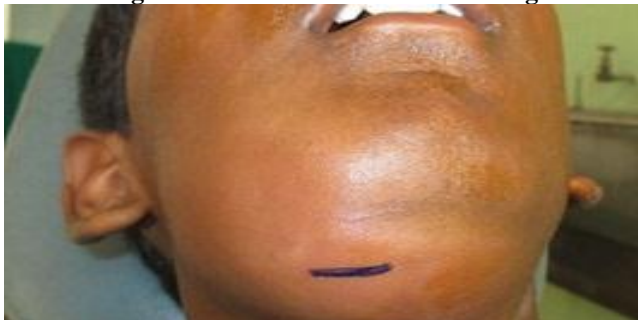**Figure 1. Pre operative worms eye view**



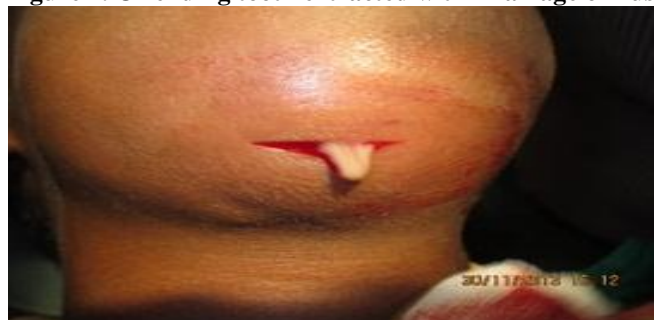**Figure 2. Pre operative OPG showing Carious 46**



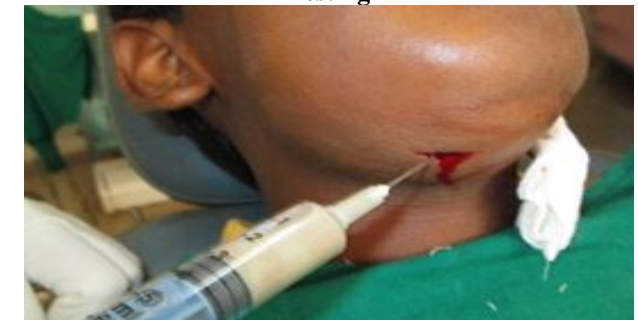**Figure 3. Incision marked for drainage**



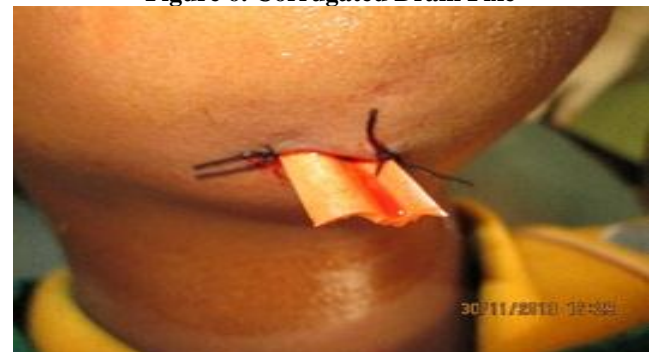**Figure 4. Offending tooth extracted with Drainage of Pus**



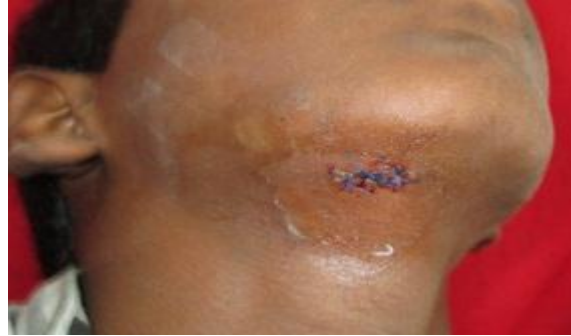**Figure 5. Aspirate for Culture and Antibiotic Sensitivity Testing**



**Figure 6. Corrugated Drain Fixe**



**Figure 7. Immediate post operative view**



## DISCUSSION

Ludwig's angina in the pre-antibiotic era carried a very high mortality rate of around 50% which has dropped down to around 8-10% today. Ludwig's angina and deep neck infections are dangerous because of their normal tendency to cause edema, distortion, with the most feared complication being airway obstruction due to elevation and posterior displacement of the tongue and edema of the glottis [5]. The presence of swelling in the neck and floor of the mouth, edema of the glottis, makes it difficult to anaesthetize the patient. In the early stages of the disease, patients may be managed with observation and intravenous antibiotics. Advanced infections require the airway to be secured with surgical drainage. This is complicated by pain, trismus, airway edema, and tongue displacement creating a compromised airway.  $\beta$ -Hemolytic streptococcus associated with anaerobic germs such as peptostreptococcus and pigmented bacteroides have been described as causative agents. Streptococcus viridans (40.9%), Staphylococcus aureus (27.3%), and Staphylococcus epidermis (22.7%) were isolated from deep neck infections. Initial antibiotic treatment should be broad spectrum to cover gram-positive and gram-negative bacteria as well as anaerobes.

Recent case reports advocated the use of intravenous steroids which potentially avoided the need for airway management [12, 13]. If patients present with swelling, pain, elevation of the tongue, malaise, fever, neck swelling, and dysphagia, the submandibular area can be indurated, sometimes with palpable crepitus. Inability to swallow saliva and stridor should raise concern because of imminent airway compromise. Airway compromise is always synonymous with the term Ludwig's angina, and it

is the leading cause of death. Therefore, airway management is the primary therapeutic concern [3]. In the management of children careful observation of their breathing ability and swallowing are helpful [15]. In our report since it was an established case of Ludwig's angina, we chose to start with intravenous infusion of fluids with antibiotics and dexamethasone followed by extraction of the offending tooth and surgical drainage of the abscess. Surgical decompression allowed the release of pressure along with reduction of edema and the risk of airway compromise was negated. Additionally studies have shown that surgical decompression allows for increased oxygenation and delivery of antibiotics via enhanced blood supply to the tissues thereby decreasing the course of the disease and improving the healing time. We also observed the same.

## CONCLUSION

In conclusion, Ludwig's angina is an extensive manifestation of soft tissue infection to occur in the cervico-facial region. Ludwig's Angina results in an aggressive form of cellulites. Due to the grotesque appearance which is specific it is not difficult to diagnose prompt and specific treatment protocol are the key to management strategy. Management of Ludwig's angina should be based on patient's clinical condition. It is essential to identify Ludwig's angina in the earlier stages of the disease, when it is easier to manage. In advanced cases, airway management and surgical drainage with organism specific antibiotic therapy are important in avoiding complications. The management policies for pediatric and adult patients largely remain the same.

## CONFLICTS OF INTEREST

None.

## REFERENCES

1. Murphy SC. (1996). The person behind the eponym, Wilhelm Frederick von Ludwig (1790-1865). *J Oral Pathol Med*, 25, 513-5.
2. Kurien M, Mathew J, Job A, Zachariah N. (1997). Ludwig's angina. *Clin Otolaryngol*, 22, 263-5.
3. Marple BF. (1999). Ludwig angina, a review of current airway management. *Arch Otolaryngol Head Neck Surg*, 125, 596-9.
4. Neff SP, Merry AF, Anderson B. (1999). Airway management in Ludwig's angina. *Anaesth Intensive Care*, 27, 659-61.



5. Barakate MS, Jensen MJ, Hemli JM, Graham AR. (2001). Ludwig's angina, report of a case and review of management issues. *Ann Otol Rhinol Laryngol*, 110(5 Pt 1), 453–6.
6. Nguyen VD, Potter JL, Hersh-Schick MR. (1992). Ludwig angina, an uncommon and potentially lethal neck infection. *Am J Neuroradiol*, 13, 215–9.
7. Seward GR, Malcolm H, David AM. (1987). *Killey and Kay's Outline of Oral Surgery*. Part 1. 2nd ed. Bristol, Wright, . p. 139-40.
8. Gbolahan OO, Olowookere S, Aboderin A, Omopariola O. (2012) Ludwig's angina following self- application of an acidic chemical. *Ann Ibadan Postgrad Med*, 10, 34-7.
9. Saifeldeen K, Evans R. (2004). Ludwig's angina. *Emerg Med J*, 21, 242-3.
10. Kaluskar S, Bajaj P, Bane P. (2007). Deep space infections of neck, *Indian J Otolaryngol Head Neck Surg*, 59, 45-8.
11. Kassam K, Messiha A, Heliotis M. (2013). Ludwig's Angina, The Original Angina. *Case Rep Surg Article I 0974269*, 4 Pages.
12. Bush RF, Shaha D. (1997). Ludwig's angina- improved treatment. *Otolaryngol Head Neck Surg*, 117, S172–5.
13. Freud B, Timon C. (1992). Ludwig's angina, a place for steroid therapy in its management. *Oral Health*, 82, 23–5.
14. Jee Hyun, Seok et al., (2009). NF versus pyomyositis, discrimination with using MR imaging. *Korean J. Radiol*. 10, 121–128.
15. Topazian R. et al. (2002). *Oral and Maxillofacial Infections*. 4<sup>th</sup> ed, W.B. Saunders, 410- 415, 177- 181.

