



DYSCHROMATOSIS UNIVERSALIS HEREDITARIA A CASE REPORT

Jayakar Thomas^{1*}, Shrisindhuja T², Tamilarasi S², and Manoharan D³

¹Professor & Head, ²Junior Residents, ³Professor, Department of Dermatology,
Sree Balaji Medical College & Bharath University, Chennai 600044, Tamilnadu, India.

Corresponding Author: - **Jayakar Thomas**
E-mail: jayakarthomas@gmail.com

Article Info <i>Received 15/06/2015</i> <i>Revised 27/06/2015</i> <i>Accepted 12/07/2015</i> Key words: Dyschromatosis universalis hereditaria, Dyschromatosis symmetrica hereditaria, Genodermatosis, Acropigmentation of Dohi.	ABSTRACT Dyschromatosis universalis hereditaria is an autosomal dominant disorder but it can be transmitted sporadically or by autosomal recessive trait. DUH is a rare genodermatosis with pigmentary changes, consisting of varying sized, intermixed with hypopigmented and hyperpigmented macules that make an overall impression of mottling or reticulate pigmentation. We report a 3 year old boy who is presented with asymptomatic diffuse reticulate hyperpigmentation involving the whole body without involvement of eye.
---	---

INTRODUCTION

Dyschromatoses (DUH) are a group of disorders characterized by the presence of both hypopigmented and pigmented macules, which are smaller in sized and irregular shaped. These are a spectrum of diseases, which includes Dowling-Degos disease, acropigmentation of Dohi, dyschromatosis symmetrica hereditaria (DSH), dyschromatosis universalis hereditaria (DUH), and a segmental form of which is called as unilateral dermatomal pigmentary dermatosis (UDP). Dyschromatosis symmetrica hereditaria (DSH) was first reported in Toyama in 1929[1, 2].

CASE REPORT

A 3 year old boy was brought to our skin OPD by his father with complaints of asymptomatic generalized hyper pigmentation. The child was born out of a fourth

degree consanguineous marriage, at birth, pigmentation was allegedly noticed only at the ear lobes and tongue, which later progressed into entire body by the end of 1st month of life. The father doesn't give any h/o photosensitivity in the child. No h/o any abnormality or illness in natal and post natal period. No h/o of similar conditions in the family. No history of delay in developmental milestones.

On examination, the boy was moderately nourished, alert and cooperative with a normal level of intelligence appropriate to his age.

On dermatological examination multiple pigmented and hypopigmented macules were present in a reticulate pattern involving scalp, face, earlobes, upper and lower limbs, trunk, genitalia, palms and soles (Fig 1&2). Dystrophy of nails noted in the feet, while nails of the



hands was normal (Fig 4). On oral examination, high arched palate was noted with pigmented patches over the tongue and buccal mucosa (Fig 3).

No dental abnormality. Normal distribution and pigmentation of hair was noted. Systemic examination did not reveal any abnormality. Routine laboratory investigations such as complete haemogram, urine

analysis, renal and liver function tests, serum electrolytes were within normal limits. A skin biopsy was taken from the pigmented lesion, which revealed, hyperkeratotic, focally atrophic epidermis and increased pigmentation of basal layer and basal cell vacuolar degeneration along with pigmentary incontinence. Dilated papillary capillaries are present (Fig 5).

Figure 1. Generalized reticulate pigmented patches interspersed with numerous hypo pigmented macules involving scalp, face, earlobes, upper limbs, palms, trunk, genitalia, lower limbs, and soles.

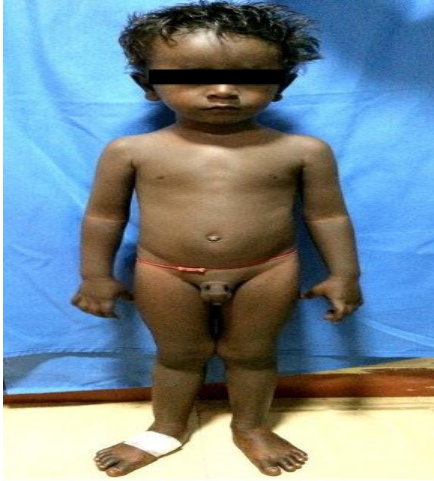

Figure 2. Clinical photograph showing lesions involving palms and soles

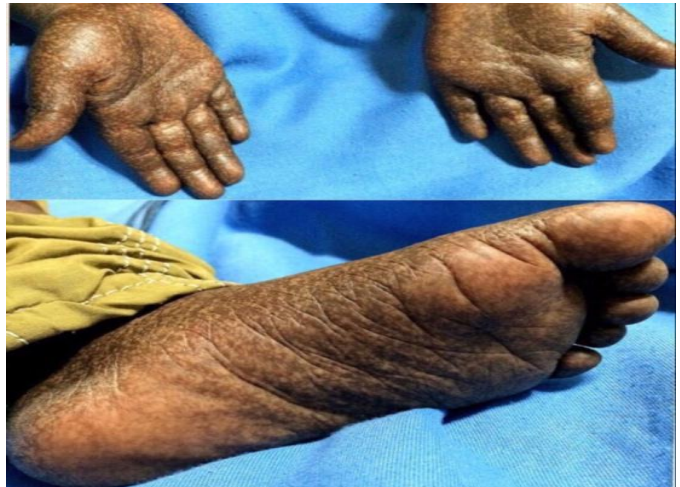

Figure 3. Clinical photograph showing pigmented patches over the tongue and high arched palate. Teeth were normal.

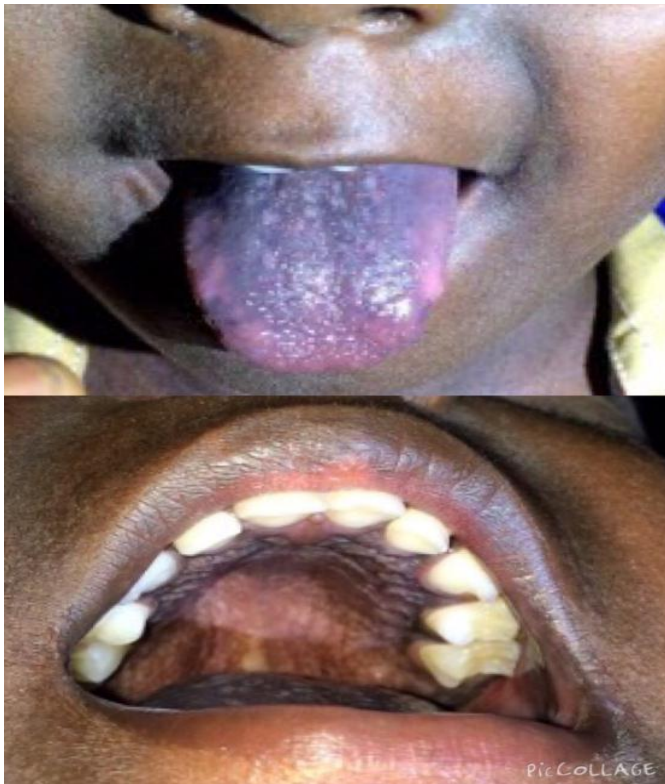
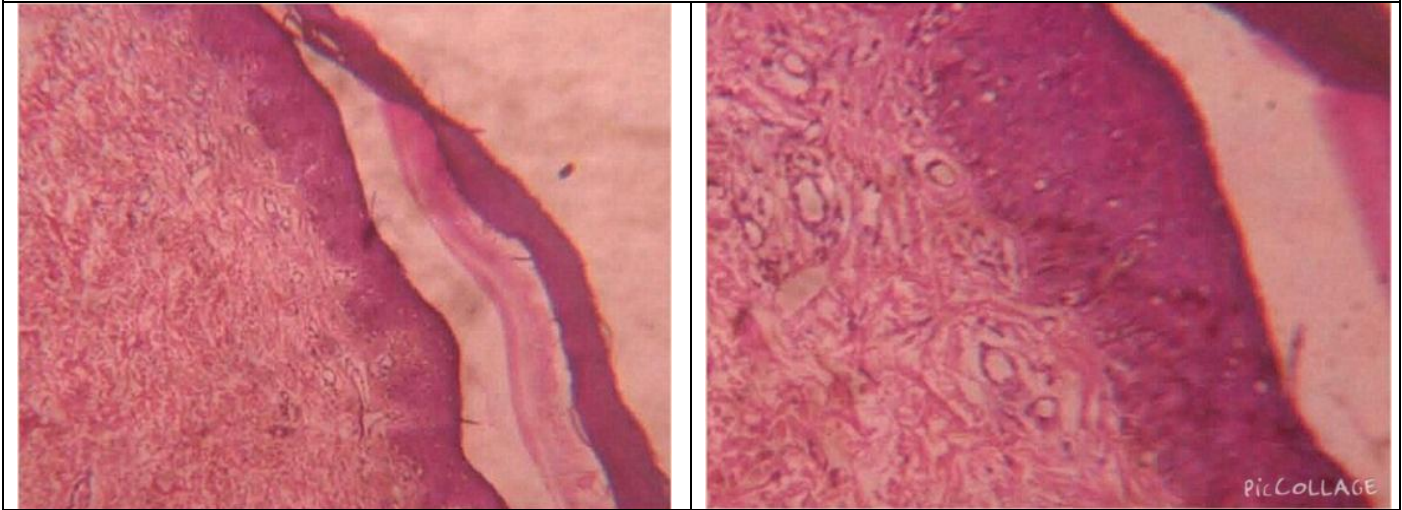


Figure 4. Clinical photograph showing reticulate pigmented patches interspersed with numerous hypo pigmented macules involving dorsum of hands and feet.

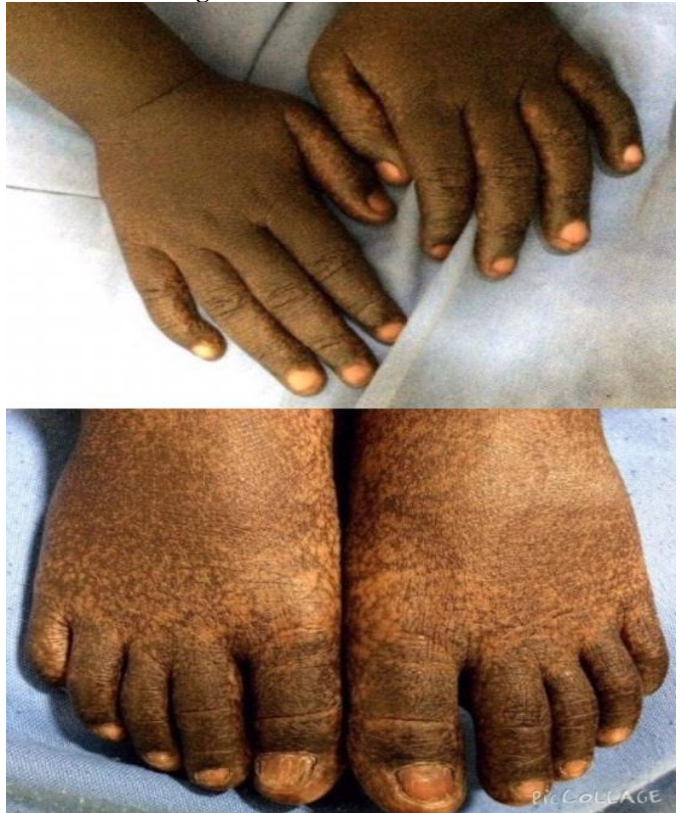

Figure 5. Histopathology showing increased pigmentation of basal layer and basal cell vacuolar degeneration along with melanin incontinence.



DISCUSSION AND CONCLUSION

Toyama described DSH as a distinct entity in 1929, Ichikawa and Hiraga described DUH in 1933, which had similar features of DSH but occurring in generalized as in opposed to acral distribution.

A novel mutation in RNA-specific adenosine deaminase gene (ADAR1, DSRAD) was reported in DSH, but there was no such mutation in DUH. Recently, ABCB6 has been identified as the first pathogenic gene associated with DUH. The exact etiology of DUH is however unclear [2]. It has been suggested that DUH is due to disorder of the number of melanocytes. But, in electron microscopic study suggested that DUH may be a disorder of melanosome production in epidermal melanin units rather than a disorder of the number of melanocytes [3].

Generally it manifested in early childhood, as mottled (reticulated) pigmentation that usually starts from hands and can progress to involve the trunk, limbs, face and feet. Hair, teeth, nails and oral mucosa may also be involved [4].

The classical nail changes are hyperpigmentation, dystrophy with pterygium formation.

Other associated conditions are photosensitivity, coxa valga and neurosensory hearing defect [4].

The histopathology shows a focal decrease or increase in melanin content of the basal layer (depending on the type of the lesion biopsied) and pigmentary incontinence. In our case, histopathology of skin biopsy reveals hyperpigmentation of basal layer and suprabasal cells with mild orthokeratosis, occasional melanophages and mild pigmentary incontinence. Number of melanocytes is within normal histological limits [5, 6].

Lesions of dyschromatosis symmetrica hereditaria have to be differentiated from xeroderma pigmentosum, dyschromic amyloidosis, dyskeratosis congenita and exposure to chemicals such as monobenzyl ether of hydroquinone and diphenylcyclopropanone [5].

Targeting the pigmented lesion with Q-switched alexandrite laser is an option, but recurrence may occur. As the condition is more emotionally harming and considering there is no definitive treatment modality for cure. Genetic counseling is advised because of the recent reports of genetic etiology.

This case of dyschromatosis universalis hereditaria (DUH) is reported because of its rarity and it assumes significance as it must be distinguished from other dyschromias [6].

REFERENCES

1. Irvine AD and Mellerio JE. (2010). Genetics and Genodermatoses. *Rook's Textbook of Dermatology*. 8th ed. Oxford: Wiley Blackwell, 15.95.
2. Kabir Sardana, Khushbu Goel, Shikha Chugh. (2013). Reticulate pigmentary disorders. *Indian Journal of Dermatol Venereol Leprol*, 79, 17-29.
3. Chang MW. (2008). Disorders of hyperpigmentation. In: Callen JP, Horn TD, Mancini AJ, Salasche SJ, Schaffer J, Schwarz, et al, editors, Bologna JL, Jorrizo JL, Rapini RP. *Dermatology*. 2nd ed. Spain: Elsevier publication, 939-963.
4. Hari Kishan Kumar Yadalla, Srivalli Pinninti, and Anagha Ramesh Bab. (2013). Dyschromatosis Universalis Hereditaria: Infrequent Genodermatoses in India. *Ind J of Human Genetics*, 19, 487-490.
5. Kikkeri Narayanshetty Naveen and U. S. Dinesh. (2014). Dyschromatosis Universalis Hereditaria with Involvement of Palms. *Ind Dermatol Online J*, 5, 296-299.

