



TOXOPLASMA LYMPHADENITIS DIAGNOSED BY FINE NEEDLE ASPIRATION CYTOLOGY

Sushma R. Gulhane^{1*}, Madhuri S. Kate², Smita S. Sonawane³, Bahoran Singh⁴

¹Specialist-Cum- Assistant Professor, Department of Pathology, ESIPGIMSR & ESIC Model hospital, Andheri (E), Mumbai-93, Maharashtra, India.

²Professor and HOD, ³Senior Resident, ⁴Post Graduate Student, Department of Pathology, ESIPGIMSR & ESIC Model hospital, Andheri (E), Mumbai-93, Maharashtra, India.

Corresponding Author:- **Sushma R. Gulhane**

E-mail: sushmar.gulhane@esic.in

Article Info	ABSTRACT
<p>Received 12/05/2015 Revised 27/05/2015 Accepted 02/06/2015</p>	<p>Diagnosis of toxoplasma lymphadenitis with demonstration of bradycyst on fine needle aspiration cytology (FNAC) has been very rarely reported. We hereby report a case of toxoplasma lymphadenitis in thirty six year old male diagnosed on FNAC. Patient presented with bilateral posterior cervical swelling since two months. There were no other constitutional symptoms. FNAC smears showed epithelioid microgranuloma, monomorphous population of lymphoid cells along with a few plasma cells and tingible body macrophages. Toxoplasma cysts containing numerous bradyzoites which is pathognomonic of Toxoplasma gondii were also demonstrated in a Papanicolaou and MGG stained smears. Considering a cytological features, positive serological test and history of animal contact the diagnosis of toxoplasma lymphadenitis was offered. Patient was treated with pyrimethamine and sulfadiazine and was followed up for recurrence for six months. To conclude, FNAC is valuable, cheap, noninvasive tool for the diagnosis of toxoplasma lymphadenitis and it avoids unnecessary surgical excision</p>
<p>Key words: Toxoplasma, Bradycyst, Lymphadenitis.</p>	

INTRODUCTION

Toxoplasmosis is caused by common obligate intracellular parasite called *Toxoplasma gondii*. It can present with varied signs and symptoms, of which asymptomatic lymphadenopathy is most common. The toxoplasma lymphadenitis is also called as Pinner-Kuchinka lymphadenitis [1]. Felines such as cats, serve as definite hosts while man and other mammals act as intermediate hosts. The presence of parasite in toxoplasma lymphadenitis is quite unusual, having been reported occasionally in histologic preparations and only rarely in cytological FNA smears.

Case history

A thirty six year old male presented with a bilateral swelling over posterior cervical region since two months. Local examination revealed, left posterior cervical lymph node measuring 4 x 3 cm and right

posterior cervical lymph node measuring 2 x 1 cm. Both the lymph nodes were solitary, discrete, painless, and firm in consistency. There were no other constitutional symptoms. Patient gave history of chronic contact with cat. Clinicians suspected it as tuberculous lymphadenitis. The patient underwent FNAC of the swellings. FNAC smears were stained with Papanicolaou and May-Grunwald-Giemsa (MGG) stains. It revealed epithelioid microgranuloma, monomorphous population of lymphoid cells along with a few plasma cells and tingible body macrophages (Fig.1). Three to four Toxoplasma cysts containing numerous bradyzoites, pathognomonic of toxoplasma gondii were also demonstrated in MGG and Papanicolaou stained smears (Fig 2 & 3). The serological test by ELISA revealed IgG specific antibody to *Toxoplasma gondii* at a level of 100 IU/ml (normal < 6 IU/ml) and IgM specific antibody at a level of 0.78 IU/ml



(normal < 0.8 IU /ml). Considering FNAC features, positive serological test and history of animal contact the diagnosis of toxoplasma lymphadenitis was given. This

patient was treated with pyrimethamine and sulfadiazine and followed up for six months and was found free of recurrence.

Fig 1. Monomorphic population of lymphoid cells along with epitheloid cell granuloma (MGG 100X)

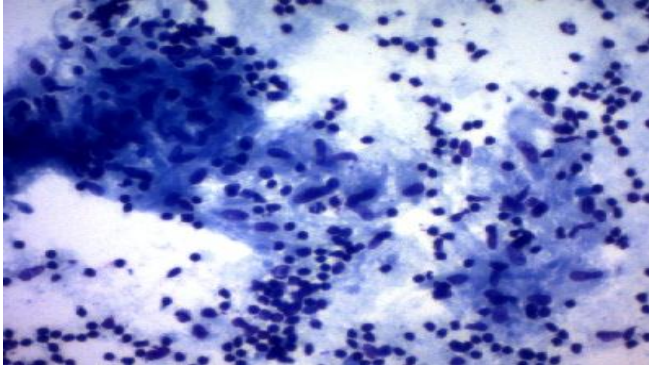


Fig 2. Tissue cyst with bradyzoite of toxoplasma gondi along with epitheloid cell microgranuloma (MGG 100x ; inset 400X)

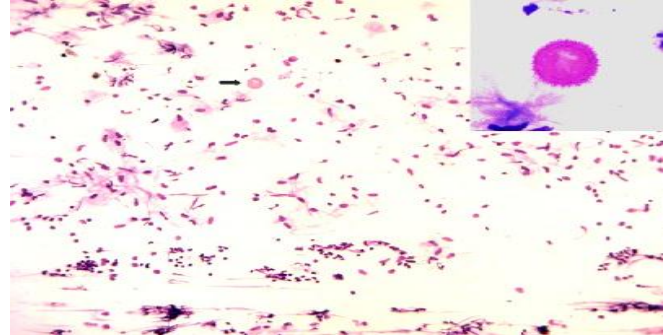
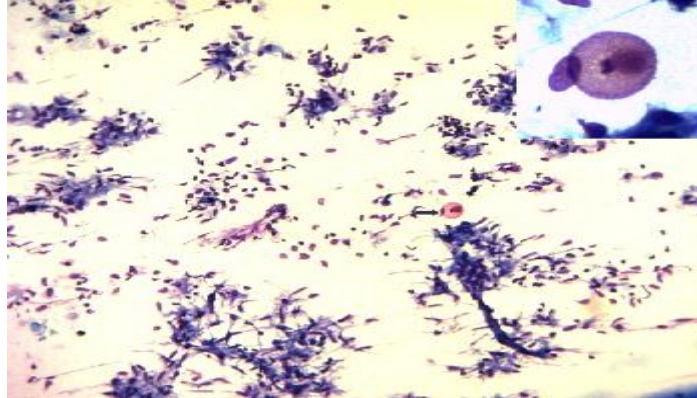

Fig 3. Tissue cyst with bradyzoite of toxoplasma gondi along with epitheloid cell microgranuloma (pap 100x ; inset 400X)



DISCUSSION

As much as 40% of the adult world population is infected with *Toxoplasma gondii* [2]. Seroprevalence average of *Toxoplasma gondii* infection in India is 24.3%, a seroconversion rate of 1.5% had been reported [3]. Toxoplasmic lymphadenitis is the most frequently observed clinical form of acquired toxoplasmosis. It was first recognized in 1950 by Siim [4] and by Gard and Magnussen on tissue section of cervical lymph node [5]. The parasite occurs in three forms namely oocyst, tachyzoites and tissue cysts. Tissue cyst containing bradyzoites is inactive and pseudocyst containing tachyzoites is active form. *Toxoplasma* infection is acquired by ingestion of viable tissue cyst in a meat or oocysts excreted by cats that contaminate the environment [6]. Our patient was in chronic contact with cat, from which he must have acquired infection.

Toxoplasma infection may be transmitted congenitally or may be acquired. Commonest presenting sign of acquired toxoplasmosis in man is enlargement of superficial lymph nodes. *Toxoplasma* lymphadenitis is the main clinical manifestation and cervical lymphnodes are usually affected [7]. The persistence of the nodes may lead to a suspicion of malignant lymphoma. The importance of

toxoplasma lymphadenitis lays in its differentiation from much more serious conditions such as lymphoma, leukemia, infectious mononucleosis, cytomegalo virus infection, cat scratch disease, sarcoidosis, tuberculosis and metastatic carcinoma [8].

The clinical presentation of *toxoplasma* infection depends on the age and immune status of the patient. In majority of immunocompetent patients, primary infection is usually asymptomatic. The lymph nodes are usually discrete, non-tender and do not suppurate. Very infrequently immunocompetent hosts might also suffer from myocarditis, polymyositis, pneumonitis, hepatitis or encephalitis. After the acute phase, almost all patients will remain chronically infected with tissue cysts that are dormant and cause no clinical symptoms. In contrast, toxoplasmosis in patients who are immunocompromised can be lead to life threatening infection [9].

The diagnosis of toxoplasmosis is based on a combination of FNAC or tissue biopsy and serological assays detecting antibodies against the parasite. However, if the patient is immunocompromised, serology may be falsely negative [10] According to Argyle *et al* [2], tissue cysts are identified very rarely (1%) on tissue section and

hardly ever in smears. we were also particularly careful in differentiating organisms, similar in size and shape, such as cyst of the Sarcocystis, Isospora, Microsporidia and Leishmania. FNAC classically shows microgranuloma which consists of small clusters of characteristic epithelioid histiocytes, with mature lymphocytes and show absence of any necrosis, suppuration or giant cells in a background of reactive lymphoid hyperplasia [11].

Treatment of Toxoplasmosis is with pyrimethamine, sulfadiazine and folic acid. Treatment is usually reserved for immunocompromised patients and those patients who are immunocompetent with severe or persistent symptoms. Our patient was also treated with sulfadiazine and pyrimethamine. Follow up of patient is necessary as bradyzoites can remain dormant in the tissue for decades to be reactivated later. Our patient was found to be well after six month of follow-up and free of recurrence.

There is much literature available on tissue

diagnosis of toxoplasma lymphadenitis however only seven to eight cases are reported till date regarding its diagnosis on FNAC. Our patient presented with bilateral posterior cervical swelling without constitutional symptoms and was clinically suspected as a tuberculous lymphadenitis . FNAC revealed the unusual finding of toxoplasma eliminating tuberculosis, thus confirming the utility of such noninvasive, OPD procedure in detecting a potentially lethal infection.

CONCLUSION

FNAC is valuable, cheap, noninvasive tool for the diagnosis and differentiating toxoplasma lymphadenitis from more serious causes of lymphadenopathy, such as metastatic lymphadenopathy or lymphoma. Papinocolou and MGG stains are appropriate for demonstration of the parasite. Bradyzoite or tachyzoite are pathognomonic of toxoplasmosis and serology is an excellent adjunct in clinching the diagnosis.

REFERENCES

1. Jose M Viguer, Jose A Jimenez-Hefferman, Pilar Lopez-Ferrer, Pilar Gonzalez- Peramato, Blanca Vicandi. (2005). Fine Needle Aspiration of Toxoplasmic (Piringer- Kuchinka) Lymphadenitis. *Acta Cytologica*, 49, 139-143.
2. Argyle JC, schumann GB, Kjeldsberg CR, Athense JW. (1983). Identification of toxoplasma cyst by fine needle aspiration. *AM J Pathol*, 80, 256 -258.
3. Dhumme M, Sengupta C, Kadival G, Rathinaswamy A, Yelumani. (2007). National seroprevalance of Toxoplasma gondii in India. *J Parasitol*, 93, 1520-1.
4. Siim JC. (1950). Epidemiological aspects of toxoplasmosis, Summaries of communications, The Sixth International Congress of Pediatrics, 365-366,
5. Gard S, Magnusson JH. (1950). Glandular form av toxoplasmos i samband med gravidet. *Sven Laktartidn*, 47, 2141-2148.
6. Remington JS, McLeod R, Desmonts G. (1995). Toxoplasmosis. In: Remington JS, Klein JO, editors. Infectious diseases of the fetus and newborn. 4th ed. Pennsylvania: WB Saunders, 140–267.
7. Ioachim HL. (1994). Toxoplasmic lymphadenitis. In *Lymph node pathology. Jb Lippincott*, 155 – 161.
8. Gupta RK. (1997). Fine needles aspiration cytodiagnosis of toxoplasmic lymphadenitis . *Acta Cytol*, 41, 1031- 1034.
9. Aneta K Tiala, Ameet S Hingwe, Laura E Johnson. (2011). Toxoplasmosis in patient who was immunocompetent: a case report. *Journal of medical case reports*, 5, 16.
10. Chen X, Remotii F, Tong GX, Gorczyca E, Hemele Bena D. (2010). Fine needle aspiration cytology of subcutaneous toxoplasmosis: A case report. *Diagn Cytopathol*, 38, 716-20.
11. Viguer JM, Heffernan J, Ferrer PL, Peramato G, Vicandi B. (2005). Fine needle aspiration of toxoplasma lymphadenitis: A cytohistologic correlation. *Acta Cytol*, 49, 139-43.

