



## OSSEOUS METAPLASIA IN AN ADENOCARCINOMA OF THE RECTUM: A CASE REPORT

<sup>1</sup>R Sharmilla Devi, <sup>2</sup>Leena Dennis Joseph, <sup>3</sup>CN Sai Shalini, <sup>4</sup>G Barathi, <sup>5</sup>Lawrence De Cruze, <sup>6</sup>Vishwanath Pai

<sup>1</sup>Postgraduate student, <sup>2</sup>Professor (Pathology), <sup>3</sup>Assistant Professor (Pathology), <sup>4</sup>Assistant Professor (Pathology), <sup>5</sup>Assistant Professor (Pathology), Professor (Surgery) Sri Ramachandra University, Chennai, Tamilnadu, India.

Corresponding Author:- **Leena D Joseph**

E-mail: [leenadj@gmail.com](mailto:leenadj@gmail.com)

Article Info	ABSTRACT
<p>Received 15/03/2015 Revised 27/04/2015 Accepted 02/05/2015</p> <p><b>Key words:</b> Osseous, Metaplasia, Colon, Carcinoma, BMP.</p>	<p>Osseous metaplasia is a rare feature to be seen in any type of tumour. Very few cases of osseous metaplasia in benign or malignant tumours of the gastro intestinal tract have been reported. We report a case of osseous metaplasia in a 48 year old male patient who was operated for adenocarcinoma of the rectum. Etiopathogenesis of osseous metaplasia is not well known but bone morphogenic proteins are known to play an important role in pathogenesis of this condition. Awareness of this condition is necessary to avoid overdiagnosis of bone invasion in malignant tumors.</p>

### INTRODUCTION

Necrotic areas of tumors often show dystrophic calcification, but mature bone formation also known as osseous metaplasia or heterotopic bone formation is a rare phenomenon. Osseous metaplasia refers to the formation of mature bone elements in the stroma of the neoplasm. This rare finding has been reported in both benign and malignant tumors of various organs. In malignant lesions they are more so in adenocarcinomas. Very few cases of adenocarcinoma of the rectum with osseous metaplasia are reported in the literature. Other sites include lung, breast, thyroid and parotid. Although osseous metaplasia is clinically and prognostically insignificant and most of the times it is an incidental microscopic finding, yet the presence of bone fragments in a malignant tumor should be evaluated carefully before labeling the lesion as osseous metaplasia. Not much is known about the pathogenesis of osseous metaplasia though there are some evidences indicating the role of Bone morphogenic proteins (BMP).

### Case details

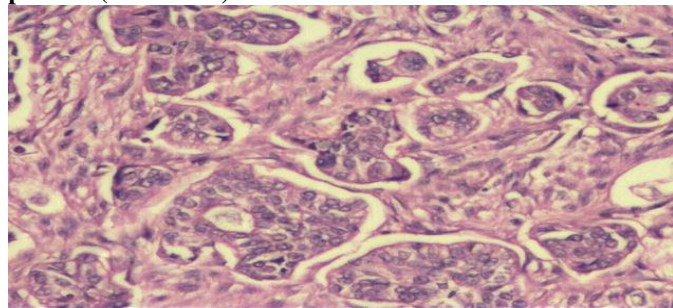
A 48 years old male patient presented with complaints of abdominal distension for one day and a

history of constipation for the past 1 week. General physical examination was within normal limits. On systemic examination he had abdominal distension. CT scan revealed an annular mass in the splenic flexure / descending colon causing obstruction with metastasis, & mesenteric vein thrombus. A subtotal colectomy was done and the specimen sent for histopathological examination.

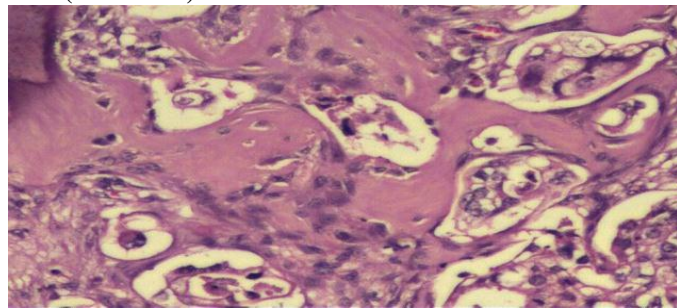
Grossly, there was a circumferential ulceroproliferative growth measuring 5 x 2x1 cms at the splenic flexure of the colon. Thirty two nodes were identified ranging in size from 3 cm to 0.3 cm in diameter. The tumor resection showed a moderately differentiated adenocarcinoma (Fig 1) with extensive necrosis and foci of comedo necrosis and calcification. The tumor was seen invading through the muscularis propria into the subserosa and non peritonealised pericolic soft tissue. Eight out of 32 lymph nodes showed metastasis. There was evidence of lymphatic invasion, but no perineural invasion. The margins were free of tumor. There were extensive areas of osseous metaplasia between the tumor islands (Fig 2). These islands consisted of irregular trabeculae of mineralised osteoid bone rimmed by a layer of scattered osteoblasts.



**Figure 1. Tumor cells arranged in an adenocarcinoma like pattern (H&Ex100)**



**Figure 2. Extensive osseous metaplasia between the tumor cells (H&Ex100)**



## DISCUSSION AD CONCLUSION

Osseous metaplasia refers to the formation of mature bone elements in the stroma of the neoplasm [1]. Heterotopic bone is rarely seen in the gastrointestinal tract (GIT). Osseous metaplasia in GIT is considered a histopathological curiosity. It is mostly seen in mucin producing colonic adenocarcinoma. The formation of bone outside the skeletal system occurs in many pathological conditions such as in generalised myositis ossificans or may represent an incidental finding. In both these situations the ossification process is initiated by a local osteogenic factor, which stimulates osteoblasts to differentiate and synthesise ground substance and collagen. Hydroxyapatite crystal formation, which is the final step in bone formation depends on the presence of an adequate concentration of calcium and phosphate. Randall et al [2] suggested that metastatic colonic carcinoma can promote heterotopic ossification, and that alkaline phosphatase is intimately associated with bone formation under these pathological condition. Bone morphogenic proteins (BMP) an inducer of osteoblastic differentiation are known to play an important role in the pathogenesis of this condition [3].

Osseous metaplasia has been reported in both benign and malignant tumours of various organs. In malignant lesions, it is mostly observed in adenocarcinoma of the GIT, lung, breast, thyroid and pancreas. Very few cases of adenocarcinoma of the rectum with osseous metaplasia are reported in the literature.

Although osseous metaplasia is clinically and prognostically insignificant and most of the times, it is an incidental microscopic finding, the presence of bone fragments in a malignant tumour should be evaluated carefully.

## REFERENCES

1. Van Patter HT, Whittick JW. (1955). Heterotopic Ossification in intestinal neoplasms. *Am J Pathol*, 31, 73-91.
2. Randall JC, Morris DC, Torrita T et al. (1989). Heterotopic Ossification, A Case report and immunohistochemical observations. *Hum Pathol*, 20, 86-8.
3. Byard RW, Thomas MJ. (1988). Osseous Metaplasia with tumors, a review of 11 cases. *Ann Pathol*, 8, 64-66.
4. WI Al-Daraji, A abdellaoui and WD Salmon. (2005). Osseous metaplasia in a tubular adenomas of the colon. *J Clin Pathol*, 58(2), 220-221
5. Victoria White, Aidan G Shaw, Gillian M Tierney, Jonathan N Lund and David Semeraro. (2008). Osseous Metaplasia in an ulcerating tubular adenoma, a case report. *J Med Case Reports*, 2, 130

Ossification can also occur in non-neoplastic lesions of the GIT like in colonic polyps, mucocoele of the appendix, gastric carcinoids and adenocarcinomas. Daraji et al [4] reported the first case of osseous metaplasia in a case of tubular adenoma of the colon in an 85 year old woman who presented with change in bowel habits. Another case of osseous metaplasia in an ulcerating tubular adenoma was reported by White et al [5]. Association of osseous metaplasia with diversion proctocolitis has been reported by Kim [6].

In contrast to dystrophic calcification which frequently occurs in necrotic areas of cancer, bone formation is extremely rare. A rare case of osseous metaplasia has been reported in renal cell carcinoma in a 35 year old female patient [7]. Yet another case of stromal osseous metaplasia was reported in a low grade ovarian adenocarcinoma [8]. To conclude, the histopathologist should be aware of osseous metaplasia in colorectal cancer to avoid misdiagnosis of carcinosarcoma, which carries a worse prognosis. The bony material is always histologically benign. Clinically it needs to be distinguished from other causes of soft tissue ossification that may be detected radiologically.

However the course and prognosis of adenocarcinoma with osseous metaplasia does not differ from that of adenocarcinoma without osseous metaplasia. Most of the times osseous metaplasia is an incidental finding on microscopic examination. Whenever mature bony fragments are found in the tumour tissue osseous metaplasia should be considered only after excluding invasion of adjacent bony tissue to the organs.

6. Kim Billingham, Miroslav Radoj Kovic. (2009). Osseous metalasia of the colon in a diversion Proctocolitis. *International Journal of Surgical Pathology*, 17(1), 81-83.
7. Paari Murugan, Debdatte Basu, R Manikandan, LN Dorairajan, Santhosh Kumar. (2008). Osseous Metaplasia in renal cell carcinoma. Report of a rare case. *Indian J Pathol Microbiol*, 51, 399-401.
8. P. Mukonosweshuro, A Oriowolo. (2005). Stromal Osseous metaplasia in a low grade ovarian adenocarcinoma. *Gynaecologic Oncology*, 99, 222-224.

