



PLEOMORPHIC XANTHOASTROCYTOMA IN A PATIENT WITH NEUROFIBROMATOSIS TYPE I

**Umesh Phalke, Sarang Gotecha*, Mangesh Sagale, Pravin Ganjare, Prashant Punia,
Shrikant Sharma**

Padmashree Dr. D.Y.Patil Medical College, Pimpri, Pune, Maharashtra 411018, India.

Corresponding Author:- **Sarang Gotecha**

E-mail: dr.sarangsgotecha@gmail.com

<p>Article Info <i>Received 15/02/2015</i> <i>Revised 27/03/2015</i> <i>Accepted 16/04/2015</i></p> <p>Key words: Pleomorphic Xanthoastrocytoma, neurofibromatosis, Left temporal lesion, India.</p>	<p>ABSTRACT</p> <p>Pleomorphic xanthoastrocytoma (PXA), a new addition to the recent 1993 World Health Organization (WHO) classification of tumors of the central nervous system, was first described in 1973 is a rare neoplasm that accounts for 1% of all astrocytic tumors. Neurofibromatosis type 1 (NF1) is an autosomal dominant genetic disorder with complete penetrance involving the chromosomal 17q11.2 gene locus. The first case of cerebral PXA-NF1, that is, PXA in association with NF1, was reported in 1993. Since then, only very few other cases have been documented, only 9 cases were reported till 2012. 40 year old male patient presented with progressive right sided weakness, slurred speech and severe headache since 10 days. Examination revealed multiple subcutaneous neurofibromas and café au lait spots all over the body. Neurological examination was also consistent with right sided weakness with no other neurological deficit. Computed tomography of the brain revealed large hypodense lesion in left frontal lobe. Left frontal craniotomy and excision of the mass lesion was done. Histopathological examination and Immunohistochemistry were suggestive of Pleomorphic xanthoastrocytoma. The first association of PXA with NF1 was reported in 1993 and 9 previously well documented cases of PXA-NF1 have been reported in the global literature of which only 2 cases have been reported in Asia and this is the first reported case in India. In a slow growing tumor such as PXA, longer period of follow up will be essential. Post-operative adjuvant therapy is required in patients with plastic changes in histopathology.</p>
--	---

INTRODUCTION

Pleomorphic xanthoastrocytoma (PXA), a new addition to the recent 1993 World Health Organization (WHO) classification of tumors of the central nervous system, was first described in 1973 as a superficially located supratentorial glioma occurring in young patients that shows extensive involvement of the leptomeninges. Kepes and coauthors in 1979 coined the term pleomorphic xanthoastrocytoma in 1979 [1]. It is a rare neoplasm that accounts for 1% of all astrocytic tumors [2].

This morphologically distinctive cerebral glioma occurred primarily in young subjects. It showed a predilection to superficial growth, and had a relatively favorable prognosis. Prior to that time, such tumors were

often classified among giant cell glioblastomas given their ominous histologic features, which include marked cellular pleomorphism, nuclear atypia, and the presence of bizarre, multinucleate giant cells. Due to the rich reticulin network that characterizes superficial portions of PXA, some had initially been considered mesenchymal tumors and were designated fibrous xanthomas or xanthosarcomas by the same author. Finally, some had been included in the now defunct category of "monstrocellular sarcoma" [3].

Neurofibromatosis type 1 (NF1) is an autosomal dominant genetic disorder with complete penetrance involving the chromosomal 17q11.2 gene locus [9, 17]. The estimated population prevalence is between 1/2,000



and 1/8,000 worldwide although that from certain parts of the developing countries is less well documented. Neurofibromatosis type I is associated with increased risk of development of intracranial tumours, particularly multiple peripheral neurofibromas. NF1 also predisposes to tumours of the central nervous system such as pilocytic astrocytomas in the optic pathway and brainstem [4].

The first case of cerebral PXA-NF1, that is, PXA in association with NF1, was reported in 1993. Since then, only very few other cases have been documented, only 9 cases were reported till 2012 [4].

We present a case of neurofibromatosis type I associated with pleomorphic xanthoastrocytoma.

Case report

A 40 year old male patient presented to our Hospital with progressive right sided weakness, slurred speech and severe headache since 10 days. General physical examination revealed multiple subcutaneous neurofibromas all over the body and café au lait spots, some which were more than 20mm wide which were located on the trunk, on the back and in the upper and lower limbs compatible with the criteria for Neurofibromatosis type I. Ophthalmic examination was normal. Neurological examination was also consistent with right sided weakness with no other neurological deficit. There was no history of trauma, convulsions, vomiting, cognitive impairment or focal deficits. There was no family history or obvious clinical symptomatology of neurofibromatosis.

Computed tomography of the brain revealed large hypodense lesion 7.8 x 5.7 cm in size in left frontal lobe surrounded by moderate edema causing significant mass effect on frontal horns of both lateral ventricles, more on left side, extending up to septum pellucidum, genu of corpus callosum, causing marked splaying of frontal horns of both lateral ventricles and shift of the anterior midline structures to the right side. Probable diagnosis of giant cell tumor or glioma or astrocytoma was given.

Left frontal craniotomy and excision of the mass lesion was done. Immediate post operative period was free of any complications. There was no worsening of deficit. Post operative magnetic resonant imaging done on tenth day post operatively showed gross total tumour resection with mild post operative hemorrhage. On follow up after one month patient was neurologically intact with resolved right hemiparesis and recovered speech. Post operatively patient was referred for radiotherapy.

Pathological findings

Histopathological examination of the specimen showed tumour made up of spindle cells having elongated nuclei arranged in interlacing fascicles, plenty of multinucleated and mononuclear tumor giant cells having abundant eosinophilic cytoplasm and many foamy cells (xanthomatous cells). Large areas of tumour necrosis and mitosis were also seen. Tumor stroma showed lymphocytic infiltrate and perivascular lymphocytic cuffing. Immunohistochemistry was done which was also suggestive of Pleomorphic Xanthoastrocytoma.

Figure 1. Computed tomography of the brain showing left temporal lesion with mural nodule

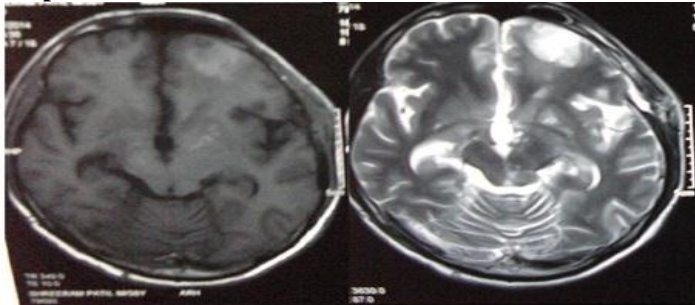


Figure 2. Clinical picture showing multiple subcutaneous neurofibromas and cafe au lait spots

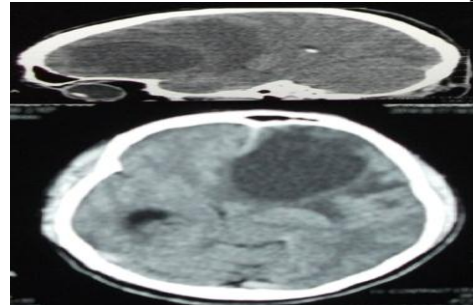


Figure 3. Post operative MRI showing gross total tumour resection with mild post operative hemorrhage



DISCUSSION

PXA is a rare (<1%), usually low grade (WHO Grade II) astrocytic lesion. Occurs most commonly in the 1st three decades with no gender predilection despite its significant histologic pleomorphism, it behaves in a less aggressive fashion [1]. It is mostly sporadic and rarely associated with NF1[5]. They are postulated to originate from subpial astrocytes, multipotential neuroectodermal precursor cells or preexisting hamartomatous lesions. Given their superficial “meningo cerebral localisation, patients typically present with a long standing history of seizures. Headache may also be the presenting symptom [6].

PXAs are almost always supratentorial and superficially situated within the cerebral hemispheres (most commonly the temporal or parietal lobe) with involvement of the Leptomeninges. Rare sites include the cerebellum, spinal cord, thalamus, globe of the orbit, pineal gland, sella turcica and cerebellopontine angle [1]. 70% arise as a cyst with solid mural nodule, the remainder being predominantly solid with variable small cystic areas [7]. Their solid component is iso to hypodense on CT, isointense on T1-weighted MR imaging, mildly hyperintense on T2-weighted imaging, and strongly enhances following gadolinium administration. Intratumoral hemorrhage or calcifications are uncommon. Peritumoral edema may be present, but is typically minimal. They may rarely show multifocality or leptomeningeal dissemination.

Its histological hallmarks, as first described by Kepes et al. is that of a benign astrocytic tumor displaying cellular and nuclear pleomorphism, intracytoplasmic eosinophilic granules, and lipid (xanthomatous) droplets, and some areas of spindle cell differentiation. There are occasional mono or multinucleated tumor giant cells, but despite this pronounced cellular pleomorphism which would otherwise suggest malignancy, mitosis, vascular endothelial proliferation, and tumor necrosis is rare. Hence, the clinical course is usually benign.

Immunohistochemistry PXAs are notable for their biphenotypic glial and neuronal Staining pattern. They are consistently positive for S-100 and GFAP, though the latter may be patchy. CD34 expression is also frequently encountered [4].

The treatment of choice in patients with PXAs is surgery. The single most significant predictor of recurrence-free survival in multivariate analysis was the extent of resection ($P = 0.007$). Recurrence-free survival

was significantly longer for patients who underwent GTR (>80% at 15 years) rather than STR (>50% at 15 years) ($P = 0.003$). Adjuvant chemotherapy or radiotherapy have not been shown to prolong survival but may reduce recurrence of this rare tumour. Postoperative radiation is reserved mainly for recurrence with anaplastic change because of the risk of radiation induced malignancy. Chemotherapy has been used to facilitate the surgical resection of PXA. Review of literature demonstrates an emphasis on a favourable prognosis despite the appearance of pleomorphic and bizarre cells microscopically. Prognosis for these tumours following surgical resection is generally good, with a 70% survival rate at 10 years. Nonetheless, PXA is associated with a higher frequency of recurrence, anaplastic transformation and death with other astrocytic tumours with a favourable prognosis [1].

The nervous system is affected in a number of familial tumour syndromes, of which neurofibromatosis type I (NF1) is one of the most frequently occurring. It is characterized by café-au-lait coloured skin spots, subcutaneous neurofibroma, Lisch nodules of the iris, and bone lesions. It is an autosomal dominant disorder which affects approximately one in every 3000- 4000 people with almost complete penetrance and about one half of the patients are believed to be a proband of the disease [7].

NF-1-associated gliomas are mostly pilocytic astrocytomas, whereas PXA is quite rare in NF-1. The first association of PXA with NF1 was reported in 1993 in a 14 year old boy from Turkey. 9 previously well documented cases of PXA-NF1 have been reported in the global literature (3 in children and 6 in young adults). Of the 9 cases reported till date, only 2 cases have been reported in Asia and this is the first reported case in India. The last case reported was of a 10 year old boy Africa.

Unusual findings on histopathological examination in our case were large areas of necrosis and mitosis which are usually absent in PXA. On account of these findings seen on HPE patient was referred for post operative radiation therapy.

CONCLUSION

In a slow growing tumor such as PXA, one with an inherently good prognosis, longer period of follow up will be essential. Our patient was advised post operative adjuvant therapy due to the anaplastic changes seen on HPE.

REFERENCES

1. Crespo-Rodriguez AM, Smirniotopoulos JG, Rushing FJ. (2007). MR and CT imaging of 24 pleomorphic xanthoastrocytomas (PXA) and a review of literature. *Neurology*, 49, 307-315.
2. Fouladi M, Jenkins J, Burger P, Langston J, Merchant T, Heideman R et al. (2001). Pleomorphic xanthoastrocytoma: Favourable outcome after complete surgical resection. *Neuro-Oncology*, 184-192.
3. Giannini C, Scheithauer B, Burger P, Brat D, Wollan P, Lach B et al. (1999). Pleomorphic Xanthoastrocytoma What Do We Really Know about it?. *Cancer*, 85(9), 2033-2045.
4. Adeleye AO, Okolo CA, Akang EE, Adesina AM. (2012). Cerebral pleomorphic xanthoastrocytoma associated with NF1: an updated review with a rare atypical case from Africa. *Neurosurg Rev*, 35, 313-319.



5. Horiguchi S, Mitsuya K, Watanabe R, Yagishita S, Nakasu Y. (2011). Pleomorphic Xanthoastrocytoma and Moyamoya Disease in a Patient with Neurofibromatosis Type1. *Neurol Med Chir*, 51, 310-314.
6. Yokoo H, Kamiya M, Sasaki A, Hirato J, Nakazato Y, Kurachi H. (2001). Neurofibromatosis type-1 associated unusual pleomorphic astrocytoma displaying continual malignant progression. *Pathology International*, 51, 570-577.
7. Van Roost D, Kritsof R, Zentner J, Wolf HK, Schramm J. (1996). Clinical, radiological and therapeutic features of pleomorphic xanthoastrocytoma: report of three patients and review of literature. *Journal of Neurology, Neurosurgery, and Psychiatry*, 60, 690-692.

