

## STUDY OF VARIATION IN THE BRANCHES OF MEDIAL CORD OF BRACHIAL PLEXUS

Sharadkumar Pralhad Sawant\*

Professor and Head, Department of Anatomy, K.J.Somaiya Medical College, Somaiya Ayurvihar, Eastern Express Highway, Sion, Mumbai-400 022, Maharashtra, India.

### Article Info

Received 29/01/2015

Revised 16/02/2015

Accepted 19/03/2015

### Keywords :-

Ulnar nerve, Median Nerve, Brachial plexus, Communication, Study of variation in the branches of medial cord of brachial plexus.

### ABSTRACT

Aim to study the variation in the branches of medial cord of brachial plexus. 100 upper limbs of 50 donated embalmed cadavers (45 males & 5 females) of age group ranging from 70 to 80 years were dissected in the department of Anatomy at K. J. Somaiya Medical College, Sion, Mumbai, India. The variations in the branches of medial cord of brachial plexus were observed in 2 specimens. The musculo - vascular pattern in the arm was also observed. The photographs of the variation of the formation of median nerve were taken for proper documentation. Variations in the formation of brachial plexus are common and have been reported by several investigators in relation to origin of roots, trunks, cords, divisions and branches. The nerves of the extremities are especially vulnerable to injury because of their long course and superficial distribution. The basic anatomy of median and ulnar nerves in the upper limb is well described in the textbooks. Previously, an ample amount of work has been done upon the communications between the median and ulnar nerves in the forearm and hand. In the present study, an unreported pattern was seen where whole of the ulnar nerve was arising from the median nerve in the arm. Its phylogeny and clinical implications are discussed in detail. A lack of awareness of variations might complicate surgical repair and may cause ineffective nerve blockade.

### INTRODUCTION

The arm is particularly vulnerable to neurological injury due to an intimate anatomical relationship between the brachial plexus and the traction zones. The brachial plexus has two fixed points, an upper one at the vertebrae and a lower one at the axillary fascia. During surgery, the combination of the arm abduction and the contralateral rotation of the head increases the stretch on the brachial plexus. Similarly, the posterior positioning of the abducted arm creates a considerable traction on it [1]. Kroll et al [2] (1990) found ulnar neuropathies to be the most frequent causes of nerve injury litigations for pain, suffering and

financial losses (33%), followed by brachial plexus injuries, which represented 23% of all the nerve injuries. The risk factors which are attributed to such injuries include abnormal posture, anaesthetic agents [1], spinal analgesia, prolonged hospitalization, neuropathies and the last but the most important one, the anatomical anomalies. Apart from the surgeons, the variations in the nerves which supply the upper limb are of interest, not only to the radiologists who interpret plain computerized imagings and MRI and anesthesiologists who place needles in the neck to administer anaesthetic blocks, but also to the neurosurgeons, neurologists, vascular surgeons and orthopaedic surgeons [3]. According to the standard textbooks of Anatomy, in the lower axilla, the cords of the brachial plexus divide into the nerves of the upper limb. The ulnar nerve arises as a branch of the medial cord, but it often receives fibres from the lateral root of the median nerve. On the other hand, the median nerve is formed by

Corresponding Author

Sharadkumar Pralhad Sawant

Email: - [drspasawant@gmail.com](mailto:drspasawant@gmail.com)

Review Article



the union of the lateral and the medial roots of the median nerve, arising from the lateral and the medial cords of the brachial plexus respectively.

#### MATERIALS AND METHODS

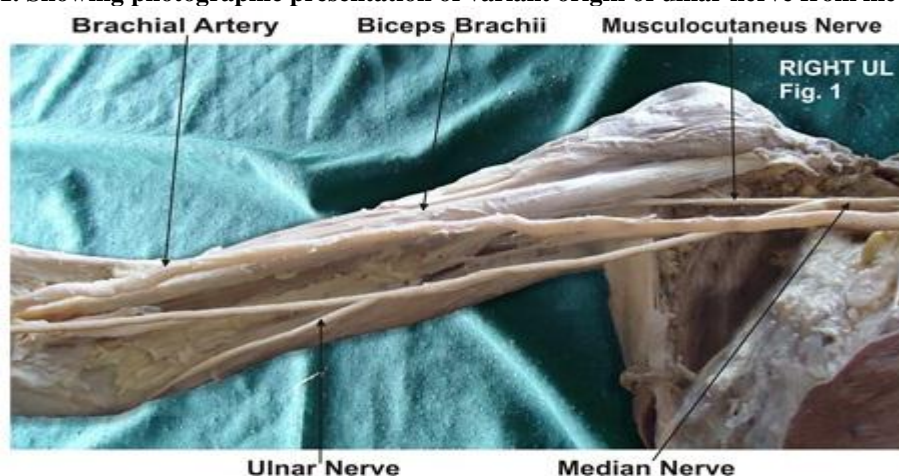
100 upper limbs of 50 donated embalmed cadavers (45 males & 5 females) of age group ranging from 70 to 80 years were dissected in the department of Anatomy at K.J. Somaiya Medical College, Sion, Mumbai, INDIA. The variation in the branches of medial cord of brachial plexus was observed in 2 specimens.

The musculo-vascular pattern in the arm was also observed. The photographs of the variation of the formation of median nerve were taken for proper documentation.

#### Observations:

Variations in the formation of brachial plexus are common and have been reported by several investigators in relation to origin of roots, trunks, cords, divisions and branches. The nerves of the extremities are especially vulnerable to injury because of their long course and superficial distribution. The basic anatomy of median and ulnar nerves in the upper limb is well described in the textbooks. Previously, an ample amount of work has been done upon the communications between the median and ulnar nerves in the forearm and hand. In the present study, an unreported pattern was seen where whole of the ulnar nerve was arising from the median nerve in the arm.

**Figure 1. Showing photographic presentation of variant origin of ulnar nerve from median nerve**



#### DISCUSSION

Many variational patterns of the branches of the brachial plexus have been described earlier. These include the communication between the median nerve and the musculocutaneous nerve [4]; the absence of the posterior cord, merging of all the cords to form a single cord [5]; the ulnar nerve arising from the posterior cord [6]; and the communication between the median and the ulnar nerves [7]. An anomalous median-to-ulnar forearm communication, which is known as the Martin-Gruber anastomosis, has been well reported in the literature, while the Marinacci communication, the reverse of the Martin-Gruber anastomosis, with a forearm ulnar-to-median communication, has been under-recognized [8]. However, none of the authors have commented upon a variation where the whole of the ulnar nerve arose from the median nerve, as in the present case. Phylogeny Miller [9] (1934) summarized the work which was done by earlier authors on the brachial plexus in amphibians, reptiles, birds, monotremes, dogs, primates in general and in anthropoid apes. He observed that in animals with poorly developed hand structures, the ulnar and the median nerves were

undifferentiated and that a single nerve trunk supplied the region. This condition is especially marked in the wing of the bird. In reptiles, the two nerves are formed from the trunk, although at a distance, peripherally. The actual differentiation of the ulnar nerve is evident in the monotremes and marsupials, in which the forelimbs are better developed and have a greater range of action. Conversely, the nerves to the compressed forefeet of dogs are fused or anastomosed for a greater part of their extent. The differentiation of the separate ulnar and median nerves are more definite in higher animals with well-developed forelimbs. The pattern which was observed in the present case was similar to the patterns which were usually observed in lower animals like reptiles and dogs. The anomalies at the high humeral level of the brachial plexus may present as a complicating factor during a surgical attempt to cause a nerve blockade. At high humeral levels, the median nerve descends from the axilla in close proximity to the brachial artery, frequently lying just lateral to the artery. Likewise, the ulnar nerve remains close to the artery to this point and is especially found just

medial to the artery [10]. But in a case like ours, when the ulnar nerve originates at a distal level from the median nerve; an attempted ulnar nerve block at a proximal level may fail or an attempted median nerve blockade may result in an associated ulnar nerve blockade.

## CONCLUSION

An effective brachial plexus blockade requires a thorough understanding of the anatomy of the plexus, as well as an appreciation of the anatomical variations that may occur. Variant nerve communications may cause ineffective nerve blockade and also, the blockade of unexpected areas. During a surgical procedure, such variations may lead to possible complications. Therefore, it is very important to know all the variants of the brachial plexus for a successful regional nerve blockade and operations.

## REFERENCES

1. Williams PL, Bannister LH, Berry MM et al. (2008). Gray's Anatomy. In, Nervous System. 40<sup>th</sup> ed. London Churchill Livingstone, 231-232, 1270.
2. Neto EPS, Durand PG, Sassolas F, Vial C, Lehot JJ. (1998). Brachial plexus injury during cardiac catheterisation in children. *Acta Anaesthesiol Scand*, 42, 876-9.
3. Kroll DA, Caplan RA, Posner K, Ward RJ, Cheney FW. (1990). Nerve injury which is associated with anaesthesia. *Anaesthesiology*, 73, 202-7.
4. Collins JD, Shaver ML, Disher AC, Miller TQ. (1995). Compromising abnormalities of the brachial plexus as displayed by magnetic resonance imaging. *Clin Anat*, 8, 1-16.
5. Li Minor JM. (1992). A rare variant of the median and the musculocutaneous nerves in man. *Arch Anat Histol Embryol*, 73, 33-42.
6. Pandey SK and Kumar S. (2004). Anomalous formation of the brachial plexus cords and the median nerve. In, Jethani SL, editor. *J Anat Soc Ind 2004. Proceedings of the 5th Annual Conference of the Anatomical Society of India*, 2003 Dec, Ahmedabad, Gujarat. India, 31.
7. Goncalves J, Duparc F, Auquit- Auckbur I, Milliez PY. (2002). Constitutional anomalies of the terminal branches of the brachial plexus in the axial and the brachial regions. Results of 42 cases and review of literature. *Ann Chir Plast Esthet*, 47(1), 30-5.
8. Kazakos KJ, Smyrnis A, Xarchas KC, Dimitrakopoulou A, Verettas DA. (2005). Anastomosis between the median and the ulnar nerve in the forearm. An anatomical study and literature review. *Acta Orthop Belg*, 71, 29- 35.
9. Meenakshi-Sundaram S, Sundar B, Arunkumar MJ. (2003). Marinacci communication, an electrophysiological study. *Clin Neurophysiol*, 114(12), 2334- 37.
10. Miller RA. (1934). Comparative studies on the morphology and the distribution of the brachial plexus. *Am J Anat*, 54(1), 143-66.
11. Stanescu S, Post J, Ebraheim NA, Bailey AS, Yeasting R. (1996). Surgical anatomy of the radial nerve in the arm, practical considerations of the branching patterns to the triceps brachii. *Orthopedics*, 19, 311-15.

## Competing Interests

The author declares that he has no competing interest.

## Authors' contributions

SPS draft the manuscript, performed the literature review & obtained the photograph for the study.

## ACKNOWLEDGEMENT

The authors wish to convey his sincere thanks to our Dean Dr. Geeta Niyogi Madam for her valuable help, support and inspiration. I am also thankful to Mr. M. Murugan. Author also acknowledges the immense help received from the scholars whose articles are cited and included in references of this manuscript. The author is also grateful to authors / editors / publishers of all those articles, journals and books from where the literature for this article has been reviewed and discussed.

