



UNICYSTIC AMELOBLASTOMA WITH RADIOGRAPHIC MULTILOCLARITY-A CASE REPORT

Sumanth Kanjekar¹ and Shyamala K^{*2}

¹ENT Dept, Bidar Institute of Medical sciences, Bidar, India.

²Oral Pathology, Rajarajeswari Dental College & Hospital, Mysore Road, Bangalore-560 060, India.

Corresponding Author:- **Shyamala K**
E-mail: shyamalakprasanna@gmail.com

| | |
|---------------------------------------------------------------------------------------------------------------------------------------------------------------------------------------------------------------------------|------------------------------------------------------------------------------------------------------------------------------------------------------------------------------------------------------------------------------------------------------------------------------------------------------------------------------------------------------------------------------------------------------------------------------------------------------------------------------------------------------------------------------|
| Article Info <i>Received 26/02/2015</i> <i>Revised 27/03/2015</i> <i>Accepted 12/04/2015</i> Key words: Unicysti ameloblastoma, Multicystic, odontogenic, Stellate reticulum | ABSTRACT Unicysti Ameloblastoma, a benign epithelial odontogenic tumor, histologically shows a cystic lumen surrounded by epithelium with basal columnar cells and superficial stellate reticulum cells. Radiographically it ideally should present as unilocular lesion but has been seen to present itself as unilocular, scalloped or even multilocular lesion. This is a case report of a 30 year old male patient diagnosed with unicysti cameloblastoma histologically showing radiographic multilocularity. |
|---------------------------------------------------------------------------------------------------------------------------------------------------------------------------------------------------------------------------|------------------------------------------------------------------------------------------------------------------------------------------------------------------------------------------------------------------------------------------------------------------------------------------------------------------------------------------------------------------------------------------------------------------------------------------------------------------------------------------------------------------------------|

INTRODUCTION

Unicysti cameloblastoma was first described as a distinct entity more than three decades ago by Robinson and Martinez (1977). It has been termed variously as mural, intracystic, cystic or plexiform unicysti cameloblastoma [1].

Mandibular third molar area is almost the exclusive site for this lesion where most cases are associated with unerupted teeth [1]. Controversial origin of these lesions as suggested by some authors favors origin from preexisting odontogenic cyst usually dentigerous cyst and rarely odontogenic keratocyst and residual cysts [2], while others regard de novo origin of this cystic neoplasm [1].

The term unicystic derived from the macroscopic -and microscopic appearance. Unicystic is the term applied when the lesion in discussion is a well-defined single cystic sac macroscopically and histopathologically lined by odontogenic (ameloblastomatous) epithelium, whereas unilocular on the other hand, is a term used in radiographic

interpretation of a radiolucency having only one loculus or compartment [3].

Against the much described unilocularity of this lesion, confusion arises when a unicysticameloblastoma appears not only as a unilocular, but also as a multilocular bone defect.

This report describes the unicysti cameloblastoma in the left mandibular posterior region showing a multilocular picture radiographically.

CASE REPORT

A 30-year-old male patient had a painless swelling on the left lower third of the face. The lesion appeared a year back from the time of visit which gradually increased in size. Patient gave a history of the swelling in the same location 5 years back which was treated by aspiration of fluid and medications, diagnosis of which we could not receive. On examination, extra oral swelling was measuring about 4cmX 4cm. Extending from molar to ramus area up to the lower border of the ear.



Ramus was involved up to the level of coronoid and condylar processes. Intraorally swelling extended from 46-47 region to ramus and showed bicortical expansion. Radiographically, multilocular radiolucency with well-defined border extending from 43 to the left molar ramus area. Multilocularity is seen in the lower portion of the lesional area. Lower mandibular border was thinned out. 46 were missing* (Fig. 1). Provisionally diagnosed as

ameloblastoma, histological examination confirmed the unicystic nature of the lesion. Cystic lumen was lined by proliferative odontogenic epithelium with basal columnar ameloblast like cells and overlying stellate reticulum like cells (Fig. 2). Immunohistochemical staining with Parathyroid hormone related protein (PTHrP) was done, which showed positivity in cystic lining demonstrating its bone resorbing nature (Fig. 3).

Fig 1. Unicystic ameloblastoma showing radiographic multilocularity

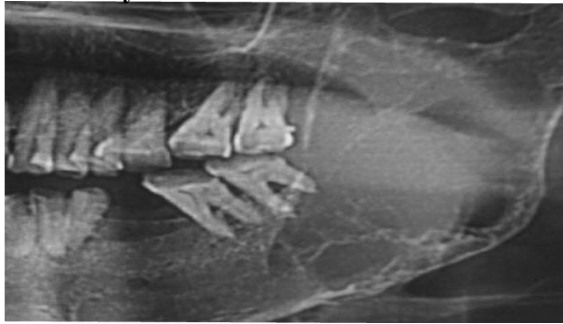


Fig 2. Histopathologic photomicrograph of UNICYSTIC ameloblastoma

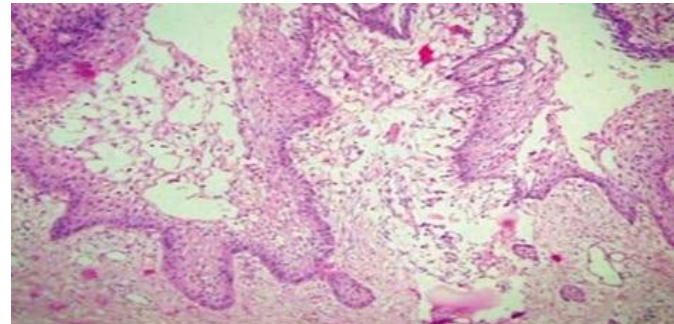
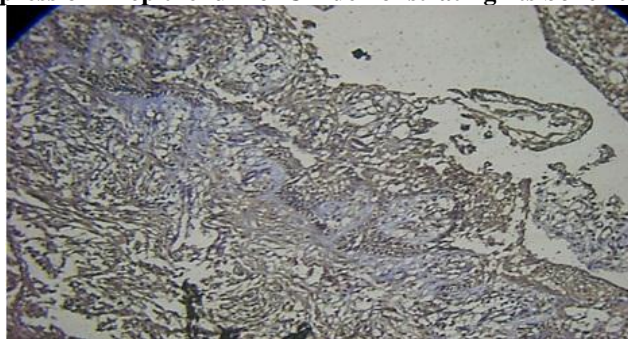


Fig 3. PTHrP expression in epithelium of UA demonstrating its bone resorptive tendency



DISCUSSION AND CONCLUSION

Eversole, Leider and Strub (1984) have detailed the radiographic pattern variations observed in 31 instances of cystogenic or unicystic ameloblastomas. They have segregated the radiographic features of unicystic ameloblastoma into two major categories [4].

1. Location relationship to contiguous teeth and
2. Radiographic configuration pattern

Eversole et al In their study they also suggested a correlation between radiographic pattern and age. Unilocular radiolucencies were encountered more often in younger patients than were multilocular radiolucencies. Average age of unilocular – impaction associated tumors was 22 years, whereas multilocular lesions without impaction occurred at an average age of 33 years [4]. In the present case age of the patient was 30 years and radiolucency was not associated with impacted or unerupted tooth and was showing multilocular appearance radiographically [4].

Among 15 cases studied by Eversole et al. without an impacted tooth, the three observable patterns included expansile unilocular periapical radiolucency without root

resorption, a pear shaped radiolucency interposed between contiguous teeth causing tooth divergence, or a periapical multilocular radiolucency with root resorption [4].

In our case it was observable that radiolucency was showing multilocularity only at the lower border of the mandible similar to the third type of radiographic picture explained by Eversole et al (1984).

As evidenced by the previous and the present report, we can arrive at a conclusion that unicystic ameloblastoma may present as unilocular, scalloped or multilocular radiolucencies.

Robinson and Martinez based on the character and combination of various tumor components recognized three histologic subtypes of unicystic ameloblastoma [1]. Later Gardner added a fourth histological subtype and pointed out that there was a difference in biological behavior between those lesions that were simply cystic and where there was an intraluminal epithelial proliferation and those in which the epithelium proliferated outwards breaching the fibrous wall and therefore having the capacity to invade adjacent cancellous bone [5].

In 1988, Ackerman and Altini have given a schematic representation of histologic subtypes.

Group I- consisted of a cystic lesion lined by simple odontogenic epithelium,

Group II- consisted of a cystic lesion showing intraluminal plexiform proliferation of the epithelial lining and

Group III- consisted of a cystic lesion with epithelial invasion of the supporting connective tissue in either a follicular or plexiform pattern [6].

Further histologic subgrouping has been given by Philipsen and Reichart [7].

Subgroup 1—luminal UA;

Subgroup 1.2—luminal and intraluminal;

Subgroup 1.2.3—luminal, intraluminal and intramural;

Subgroup 1.3—luminal and intramural.

Histological examination of the entire lesion is must for a definitive diagnosis of unicystic ameloblastoma and it cannot be predicted preoperatively on clinical or radiographic grounds. As preoperative incisional biopsy is not representative of the entire lesion, it may result in an incorrect classification. True nature of the lesion becomes evident only after enucleation when the entire specimen is available for microscopy [8].

Histopathology of present case coincides with group III subtype in which lining epithelium of odontogenic origin showing basal columnar cells with hyperchromatic nuclei, reversal of polarity and supra basilar portion with 2-3 layers of stellate reticulum like cells lining a single cystic lumen suggesting the unicystic nature of this ameloblastoma. Few islands of odontogenic epithelium is seen in deeper connective tissue which was evident only after examining the entire specimen. We also stained the tissue immunohistochemically with PTHrP, which showed moderate positivity, which demonstrated bone resorbing tendency of this tumor. This nature of UA in this case probably is responsible for radiographic multilocularity. This particular observation is supported by our previous study on ameloblastoma expressing PTHrP [9].

This case report of unicystic ameloblastoma with radiographic multilocular picture is an addition to few such lesions in the literature. This in our opinion may help to understand the biological behavior of unicystic ameloblastoma and thus aid in treatment plan.

REFERENCES

1. Robinson L, Martinez MG. (1997). Unicystic ameloblastoma: a prognostically distinct entity. *Cancer*, 40, 2278.
2. Leider AS, Eversole LR, Barkin ME. (1985). Cystic ameloblastoma: a clinicopathologic analysis. *Oral Surg*, 60, 624.
3. Philipsen HP, Reichart PA. Unicystic ameloblastoma. (1998). A review of 193 cases from the literature. *Oral Oncology*, 34, 317-325.
4. Eversole LR, Leider MA, Strub D. (1984). Radiographic characteristics of cystogenicameloblastoma. *Oral Surg*, 57, 572-577
5. Gardener DG. (1984). A pathologist's approach to the treatment of ameloblastoma. *J Oral Maxillofac Surg*, 42, 161
6. Ackermann GL, Altini M, Shear M. (1988). The unicystic ameloblastoma: a clinicopathological study of 57 cases. *J Oral Patho*, 17, 541-546.
7. Philipsen HP and Reichart PA. (2004). Classification of Odontogenic Tumors and Allied Lesions, Odontogenic tumors and allied lesions Quintessence.
8. Roos RE, Raubenheimer EJ. (1994). Clinico-pathological study of 30 unicystic ameloblastomas. *The Journal of the Dental Association of South Africa*, 49(11), 559-562.
9. Shyamala K and Hemavathy S. (2010). An Immuno histo chemical Study of Parathyroid Hormone - Related Protein: A Comparative Analysis In Ameloblastoma and Dentigerous Cyst. *Curr. Res. J. Biol. Sci*, 2(4), 262-267.

