



## STRUMA OVARIII – A RARE OVARIAN TUMOUR

**S.Srikanth**

Assistant Professor, Department of Pathology, Prathima Institute of Medical Sciences, Karimnagar, Telangana.

Corresponding Author:- **S.Srikanth**  
E-mail: [drshastrysri@yahoo.com](mailto:drshastrysri@yahoo.com)

<p><b>Article Info</b> <i>Received 15/01/2015</i> <i>Revised 27/02/2015</i> <i>Accepted 25/03/2015</i></p> <p><b>Key words:</b> Struma ovarii, right ovary, thyroid.</p>	<p><b>ABSTRACT</b> Struma ovarii is a highly specialized form of ovarian teratoma, characterized by the presence- entirely or predominantly- of mature thyroid tissue. Its most important complications, although rare, are malignant transformation and thyrotoxicosis. Struma ovarii is a variant of ovarian teratoma in which thyroid tissue components is the major constituent. Thyroid tissue is observed not uncommonly in 5-15% of teratoma, but to qualify as a struma ovarii tumor the thyroid proportion must comprise more than 50% of the overall tissue. Struma ovarii is rare type of mature cystic teratoma comprising of variable amount of functioning thyroid tissue in the tumour. The risk of malignancy in Struma ovarii is 5%.</p>
--	---

### INTRODUCTION

Struma ovarii is characterized by the presence of more than 50% of thyroid tissue in an ovarian tumor, typically seen as monodermal mature teratoma. Struma ovarii of the ovary is a relatively rare tumor which comprises 1% of all ovarian tumors and 3% of all dermoid tumors [1]. Struma ovarii was first described by Von Kalden in 1895 [2]. In 1889, Boettlin observed the presence of thyroid follicular tissue in ovaries, and then further study reports were published by Gottschalk 1899 [3]. Most cases of Struma ovarii are benign and usually unilateral, only 5%-to-10% of Struma ovarii are malignant [4]. In spite of so much amount of thyroid tissue, hyperthyroidism is seen in about 8% of patients with Struma ovarii [5]. Struma ovarii is a highly specialized form of mature ovarian teratoma. While approximately 15% of teratomas contain thyroid tissue, struma ovarii can only be diagnosed when thyroid tissue is the predominant element [6-8]. Here we are presenting a case of Struma ovarii of right ovary which is a rare presentation.

### CASE REPORT

A 40 year old female patient P<sub>2</sub>L<sub>2</sub>, presented in Gynecology OPD with mass per abdomen since two months. She gave history of decreased appetite and weight loss since 1month. Her menstrual cycles were normal. Per

abdomen examination revealed mass of size 20x10cm in right side of abdomen, mobile and firm. Gynecologists provisionally diagnosed it as ovarian malignancy. Ultrasonography revealed a large multiseptated lesion of size 20x15cm with areas of solid component suggestive of mucinous cystadenocarcinoma of right ovary ( Figure 1). Right sided oophorectomy was done and sent for histopathological examination. Grossly the right ovary was of size 19x10x8cm with multinodular external surface (Figure 2a). Cutsection revealed multiloculated cystic areas of diameter varying from 2 to 6 cm filled with brownish fluid - colloid like (Figure 2b). On microscopy it was confirmed as Struma ovarii.

### DISCUSSION

Struma ovarii, a rare neoplasm, is a monophyletic teratoma composed of thyroid tissue. It is generally considered to account for less than 5% of mature teratomas. Ludwig Pick first recognized that Struma ovarii was composed of thyroid tissue in the early part of the twentieth century and labeled it as ovarian goiter, which are actually teratomas with thyroidal elements overgrown the other tissues .

Struma ovarii is the most common type of monodermal teratoma accounting for nearly 3% of all



mature ovarian teratomas, composed of variable amount of ovarian tissue in mature cystic teratoma. The thyroid tissue component may vary from less than 50% to entire tumour tissue. The age incidence of Struma ovarii is in the 30 to 50 years, but cases have been reported in older postmenopausal women and uncommonly occur in pre-pubertal girls and early reproductive age group [9].

Struma ovarii is the most common type of ovarian tumour associated with peripheral steroid cell formation. Struma may be rarely associated with Brenner tumour, Mucinouscystadenoma and Serous cystadenoma. Strumal carcinoid, a neoplasm is unique to the ovary. It is composed of both monodermal teratoma (Struma) and secondary somatic tumour (carcinoid).

Thyroid elements can be noted in almost 20% of the cases of dermoid cyst, however the term 'struma' is used when the thyroid tissue constitutes more than 50% of the tumor. Preoperatively, the clinical diagnosis of struma ovarii is possible in patients having hyperthyroidism, but only 8% of patient with struma ovarii present with clinical hyperthyroidism. Histopathology is the confirmatory tool of diagnosis in all cases.

Mostly it is unilateral, benign and more common in right ovary, usually less than 10cm in size. The malignant struma ovarii is even rare, and makes about 5% of all cases of struma ovarii. In the present case also the tumour was unilateral and on right side.

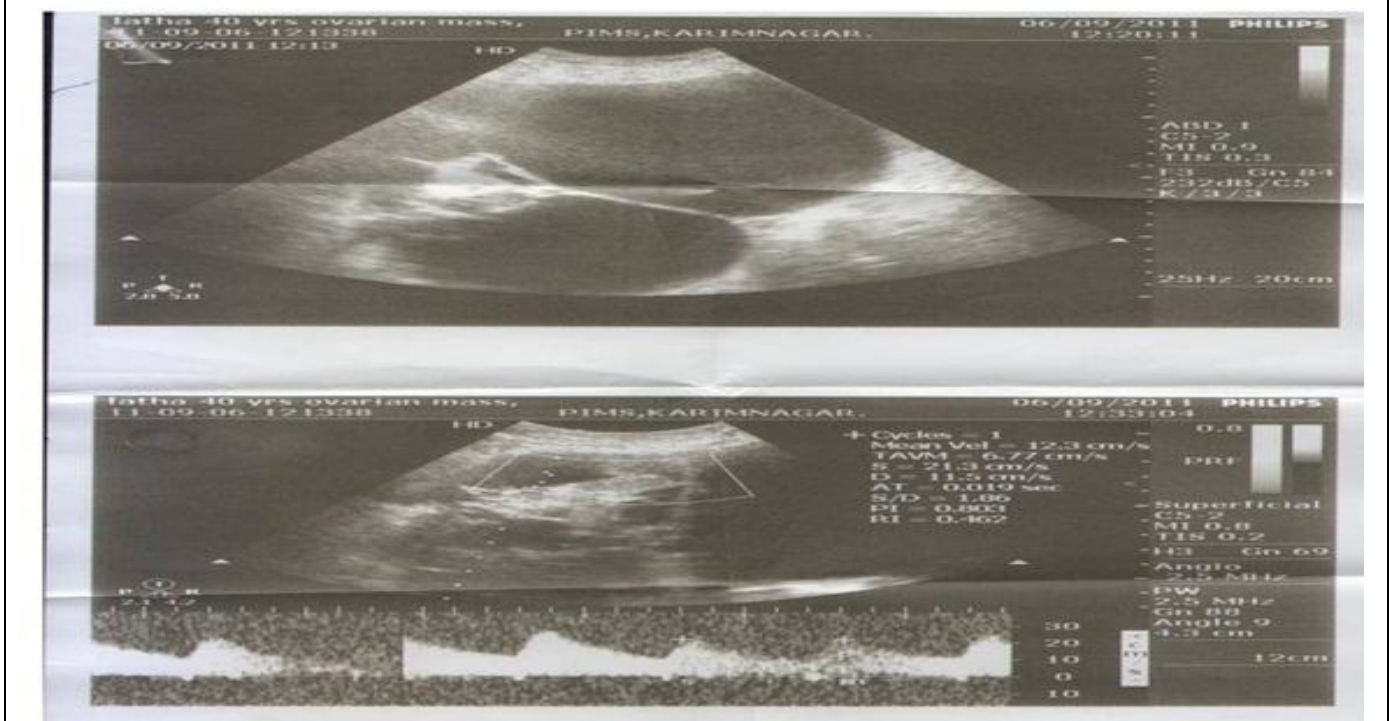
The microscopic examination reveals thyroid follicles of varying sizes, filled with pink staining, homogenous, gelatinous colloid, lined with flattened

cuboidal epithelium and separated with internal septations (Figure 3a & b). Because of its rarity, there is no consensus on struma ovarii treatment. Each case must be managed individually. Definitive therapy depends on the extent of the disease and the future childbearing wishes of the patient. Simple salpingoophorectomy is the therapy of choice for the vast majority of patients, since most cases are unilateral and benign. Total hysterectomy with bilateral salpingoophorectomy is indicated for bilateral tumors or in postmenopausal patients. In cases of malignant transformation, a combination of complete tumor resection, total thyroidectomy and adjuvant [10] ablation is usually mandatory; since there is evidence that struma ovarii behaves like its thyroid counterparts [11].

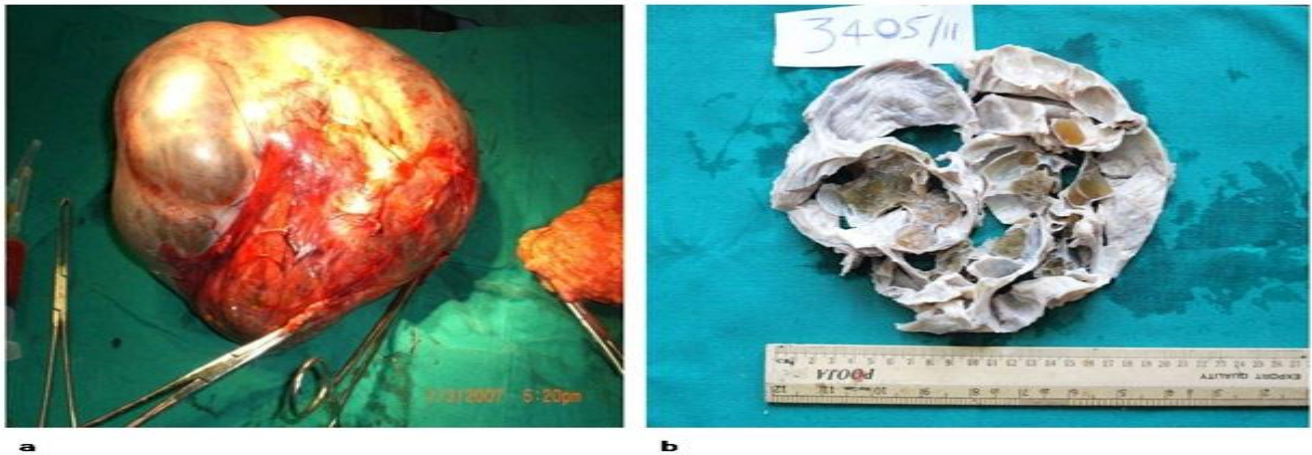
In our case right oophorectomy was done and the thyroid hormonal status was in normal range after operation. Struma ovarii is usually nonfunctional and only 8% of patients' present symptoms and signs of hyperthyroidism, as a result of autonomous activation of its thyroid tissue. The surgical removal of struma ovarii in such cases usually results in disappearance of symptoms, although in rare cases may lead to exacerbation of hyperthyroidism because of the release of TSH receptors stimulating antibodies postoperatively.

This case is being presented because of its rarity and though radiological and clinical data were suggestive of malignant lesion, Histopathology proved to be teratomatous etiology.

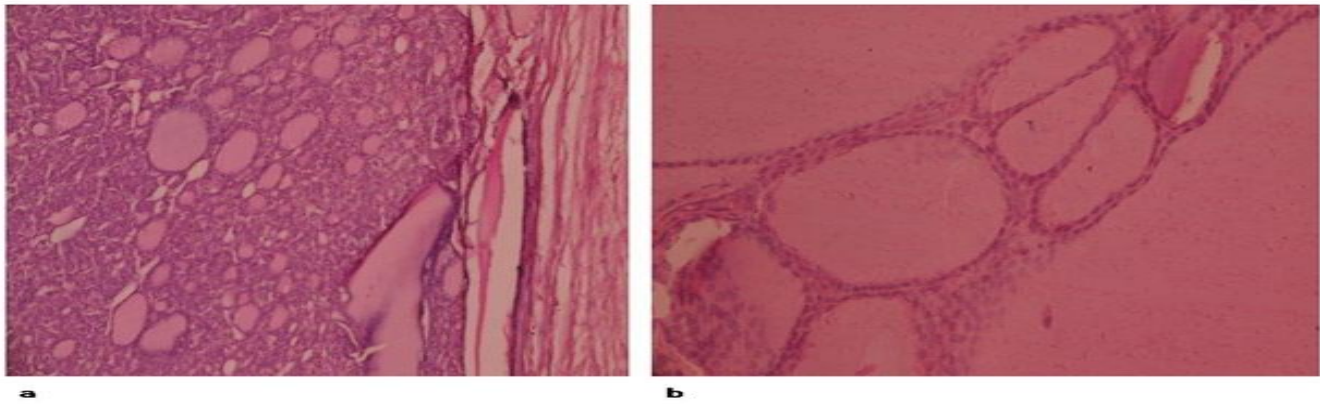
**Figure 1. Ultrasonography of abdomen showing large multiseptated lesion of size 20x15cm with areas of solid component – suggestive of mucinous cystadenocarcinoma of right ovary.**



**Figure 2. Right sided oophorectomy specimen of size 19x10x8cm with multinodular external surface (Figure a). Cut section showing multiloculated cystic areas of diameter varying from 2x6cm filled with colloid like material (Figure b).**



**Figure 3. Section showing thyroid follicles of varying sizes lined by flattened cuboidal epithelium filled with colloid. (Figure a&b,X10 X40 H&E).**



## REFERENCES

1. Ayhan A, Yanik F, Tuncer R, Tuncer ZS, Ruacan S. (1993). Struma ovarii. *Int J Gynecol Obstet*, 42, 143.
2. Yannopoulos D, Yannopoulos K, Ossowski R. Malignant struma ovarii. (1976). *Pathol Annu*, 11, 403.
3. Boettlin R. (1989). Struma ovarii. *Virchow's Arch Path Anat*, 115, 493.
4. Alfie Cohen I, Castillo Aguilar E, Sereno Gomez B, Martinez Rodriguez O. (1999). Struma ovarii: a variety of monodermic teratoma of the ovary. Report of 8 cases. *Ginecol Obstet Mex*, 67, 153.
5. Dardik RB, Dardik M, Westra W, Montz FJ. (1999). Malignant struma ovarii: Two case reports and a review of the literature. *Gynecol Oncol*, 73, 447.
6. Makhija P, Rameshkumar K, Nirmala V. (2000). Histologic spectrum of struma ovarii. *Indian J Cancer*, 37, 79-84.
7. Dardik RB, Dardik M, Westra W, Montz FJ. (1999). Malignant struma ovarii; two case reports and review of the literature. *Gynecol Oncol*, 73, 447-51.
8. Rose PG, Arafah B, Abdul-Karim FW. (1998). Malignant struma ovarii: recurrence and response to treatment monitored by thyroglobulin levels. *Gynecol Oncol*, 70, 425-7.
9. Roth L, Talerman A. (2007). The enigma of struma ovarii. *Pathology*, 39, 139.
10. Mimura Y, Kishida M, Masuyama H, Suwaki N, Kodama J, and Otsuka F et al. (2001). Coexistence of Graves's disease and struma ovarii: Case report and literature review. *Endocr J*, 48, 255- 260.
11. Dardik RB, Dardik M, Westra W, Montz FJ. (2009). Malignant struma ovarii: Two case reports and a review of the literature. *Gynecol Oncol*, 73, 447- 451.