



HIRUDOTHERAPY FOR FLAP SALVAGE- REPORT OF TWO CASES

Praveen N¹, Deepa CK² and Laxminarayan Bhandari¹

¹Department of Plastic Surgery, Government Medical College, Kozhikode, Kerala, India.

²Department of Veterinary Parasitology, College of Veterinary sciences, Wayanad, Kerala, India.

Corresponding Author:- **Laxminarayan Bhandari**

E-mail: lax321@gmail.com

<p>Article Info <i>Received 15/01/2015</i> <i>Revised 27/02/2015</i> <i>Accepted 22/03/2015</i></p> <p>Key words: Leech therapy, Flap congestion, Hirudo medicinalis.</p>	<p>ABSTRACT Hirudotherapy is the application of leeches for medical purpose. Following flap procedure or re-implantation, leeches are used to relieve post operative venous congestion and salvage the flap. We report two cases where we successfully applied leeches to save congested flaps. There were no complications. Hirudotherapy works on three mechanisms- active suction of the blood by the leeches, passive ooze from the bite site and injection of bio- active materials into the wound. Complications of leeching include- transient itching, infection, requirement of blood transfusion and regional lymphadenitis.</p>
--	--

INTRODUCTION

Hirudotherapy or the use of leech to treat various medical conditions can be traced thousands of years ago. Greek physicians used leeches to treat joint pain, fever and hearing loss [1]. Galen described the “humor” concept in which diseases were caused by imbalance in four humors- blood, black bile, yellow bile and phlegm. Balance was restored by sucking out excess humor by leeches [2]. Leech therapy became so popular that it was used for conditions such as haemorrhoids, vaginitis, mental disorders, epilepsy, skin disorders, gout and headache [1]. With beginning of modern medicine, leech therapy fell into disrepute and was almost stopped.

Since last 50 years, leeches have found a place in reconstructive surgery. With advent of microsurgery, medicinal leech therapy is enjoying a renaissance. Following flap procedure or re-implantation, leeches are used to relieve post operative congestion and salvage the flap. Deganc and Zdravic first reported treatment of congested flaps using leeches [3]. FDA approved leeches for this use in 2004.

We report two cases where we successfully applied leech therapy for flap salvage- one for a pedicled flap and the other one for free flap.

Case Report-1

A 60 yr old man presented with open comminuted fracture of both bones of right leg. After fixation of fracture, he was transferred to plastic surgery for flap cover. Due to nature of injury and vascular status of the leg, a cross leg flap was done. On the second post operative day, the flap was congested. H. Medicinalis leeches were applied. About two leeches were applied thrice daily for 4 days, following which the congestion subsided and flap was salvaged (Pic 1).

Case report-2

A 35 yr old man was referred to our department with post traumatic raw area of the foot involving heel and sole. Free antero-lateral thigh flap was done to cover the weight bearing area and heel. Remaining areas were skin grafted. On post operative day three, the flap turned dusky. It was re-explored and both veins were found to be thrombosed. After performing re-anastomosis, leech therapy was started with H. Medicinalis. Two leeches were applied on the most congested peripheral parts three times daily for five days. The congestion subsided and the flap was salvaged (Pic 2).



DISCUSSION

A flap or a re-implant may fail either due to arterial insufficiency or venous insufficiency. The latter is much more common than the former and occurs usually on the second or third post operative day. Venous thrombosis leads to stasis, increased pressure at venous end of capillaries leading to arterial insufficiency and eventually tissue necrosis. Various methods have been tried to relieve venous congestion such as, removal of tight dressing or sutures, elevation, bloodletting by creating multiple stabs in the flap with heparin irrigation and leeching.

Hirudotherapy is the use of leeches for medical applications. It works on three mechanisms- active suction of the blood by the leeches, passive ooze from the bite site and injection of bio- active materials into the wound [4, 5]. Once a leech bites into an area, it injects its saliva into the tissues. The saliva contains many bio-active substances, principal ingredient being Hirudin. Other substances include factor X inhibitor, calin, apyrase, PAF antagonist, collagenase and prostaglandins. These substances have anticoagulant, anti- platelet, vasodilating and anesthetising properties. The final effect is the accumulated result of these three mechanisms [4, 5].

Modern leeching procedure is considered safe with few complications. Slight localized itching at the bite site for three days is the most common side effect. Signs of regional lymphadenitis like swelling and pain at regional lymph nodes on the side of leech application can occur [6]. Patient may develop slight fever. Patient may need blood transfusion due to persistent bloodletting. Symbiotic bacteria such as *Aeromonas hydrophila* and *Aeromonas veronii*, living in the intestinal tract of the leech, may cause infections in 4–20% of the patients.

Accordingly, prophylactic treatment with antibiotics is necessary. *Aeromonas* infections can occur acutely (within 24 hours) or in a delayed fashion (up to 26 days) after the beginning of leech therapy. Clinical manifestations of *Aeromonas* infection vary from a minor wound infection to extensive tissue loss [6,7].

Contraindications related to hirudotherapy include arterial insufficiency, haemophilia, hemorrhagic diathesis, haematological malignancies, anaemia, hypotension, and sepsis. Leech therapy is not recommended in pregnancy and lactation, history of allergy to leeches as well as in those using anticoagulants and immunosuppressants [5,7].

Hirudotherapy has been successfully applied to salvage reimplanted fingers, ears, nasal tip, scalp and penis. Leeching is also used to relieve venous congestion of various flaps. Mumcuoglu has provided recommendations to be followed while implementing leeching [5]. These include:

- a. Obtaining a written informed consent
- b. Anti-*Aeromonas* antibiotics should be started
- c. Leeches should be applied on the darker spots of the reattached body parts or flaps.
- d. Usually 1–10 leeches are used for each treatment, while at the beginning, the patient might need two or more treatments per day.
- e. Leech therapy is used until venous capillary return is established across the wound border by angiogenesis. Usually the treatment with leeches lasts for 2–6 days.

Hematologic evaluations should be performed every 4 hrs and the patient has to receive blood transfusions when the haemoglobin level is lower than 8 g/dL.

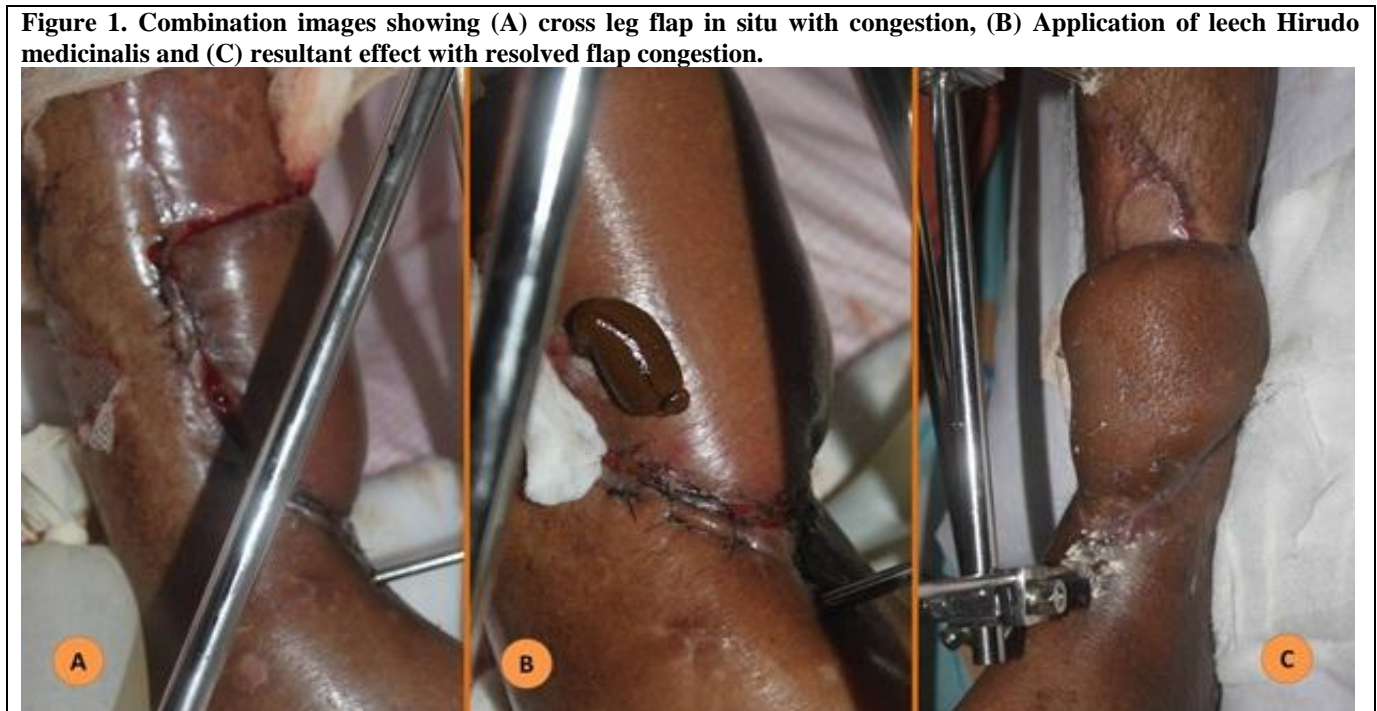
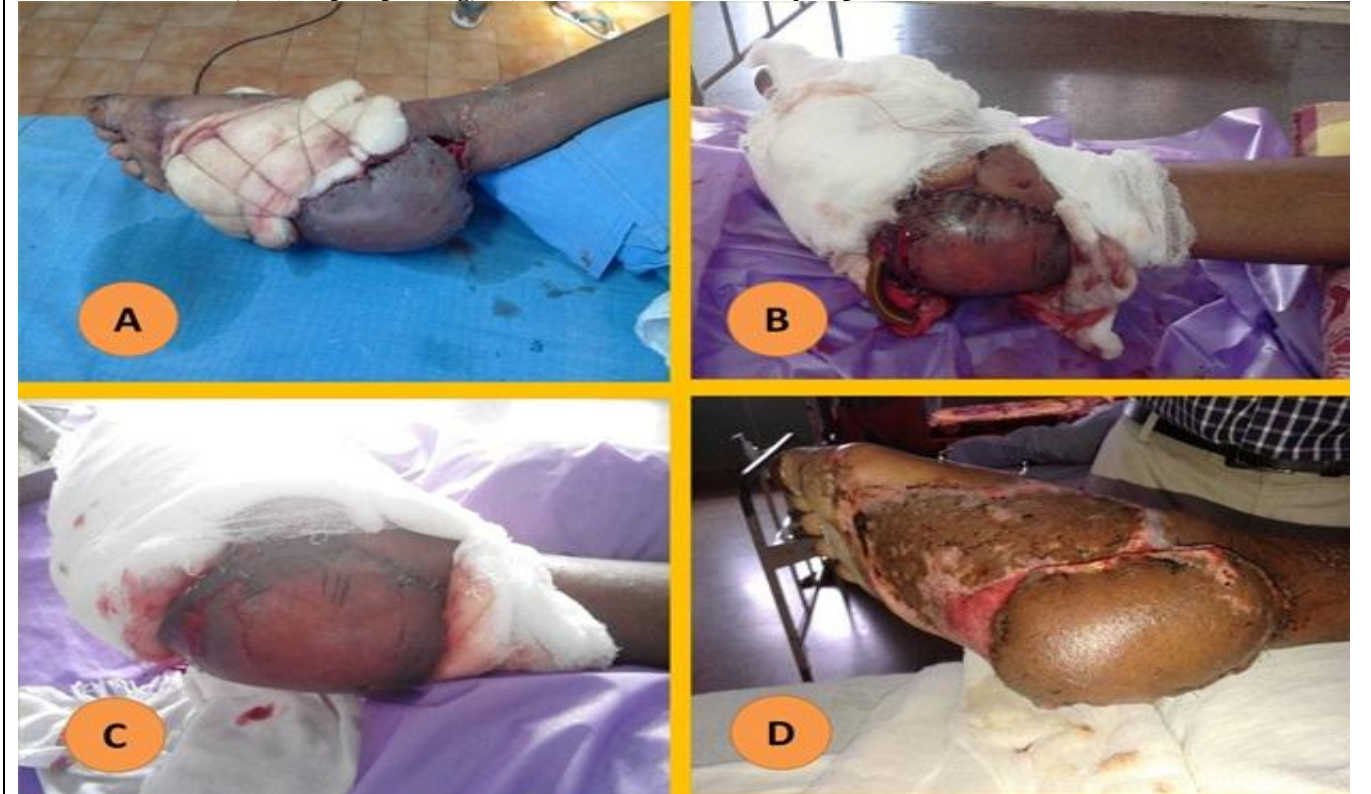


Figure 2. Combination images showing (A) free ALT flap with severe venous congestion, (B) Application of leech *Hirudo medicinalis*, (C) Flap improving, (D) Final result with healthy flap.



CONCLUSION

Hirudotherapy or application of leeches is a well established procedure to relieve venous congestion of flaps. When other measures fail, they become the last

resort. By active suction of the blood as well as implantation of bioactive substances into tissues, they relieve the congested blood from the flap. Complications are very few, and patients need anti-*Aeromonas* cover.

REFERENCES

1. Munshi Y, Ara I, Rafique H, Ahmad Z. (2008). Leeching in the history-a review. *Pak J Biol Sci*, 11(13), 1650-3.
2. Wells MD, Manktelow RT, Boyd JB, Bowen V. (1993). The medical leech: an old treatment revisited. *Microsurgery*, 14(3), 183-6.
3. Deganc M, Zdravic F. (1960). Venous congestion of flaps treated by application of leeches. *Br J Plast Sur*, 13, 187-192.
4. Eldor A, Orevi M, Rigbi M. (1996). The role of the leech in medical therapeutics. *Blood Reviews*, 10(4), 201-209.
5. Mumcuoglu K Y. (2014). Recommendations for the Use of Leeches in Reconstructive Plastic Surgery. *Evidence-Based Complementary and Alternative Medicine*, Article ID 205929, 7.
6. Lineaweaver WC, Furnas H, Follansbee S et al. (1992). Postprandial *Aeromonas hydrophila* cultures and antibiotic levels of enteric aspirates from medicinal leeches applied to patients receiving antibiotics. *Annals of Plastic Surgery*, 29(3), 245-249.
7. Gileva OS, Mumcuoglu KY. (2013). Hirudotherapy, in *Biotherapy—History, Principles and Practice: A Practical Guide to the Diagnosis and Treatment of Disease Using Living Organisms*, M. Grassberger, et al Eds, Springer, Heidelberg, Germany, 31-76.