



A RARE CASE OF RETAINED WOODEN INTRACRANIAL FOREIGN BODY FOLLOWING TRAUMATIC HEAD INJURY

Vishwanath Sidaram¹, Chandrakumar PC² and Bellara Raghavendra^{3*}

¹Associate Professor, Department of Neurosurgery, ²Associate Professor, Department of Surgery, ³Associate Professor, Department of Community Medicine, Vijyanagara Institute of Medical Sciences, Bellary, Karnataka, India.

Corresponding Author:- **Bellara Raghavendra**
E-mail: bellararaghu@gmail.com

<p>Article Info <i>Received 15/01/2015</i> <i>Revised 27/02/2015</i> <i>Accepted 20/03/2015</i></p> <p>Key words: Head injury; Foreign Body; Wooden piece; Infection; assault; Non missile</p>	<p>ABSTRACT Non missile head injuries with intra cranial foreign bodies' especially wooden piece are very rare, and lead to significant morbidity and mortality: posing a serious challenge to the neurosurgical team as the management of such injuries is complex. Wooden intra cranial foreign bodies are very difficult to diagnose radiologically and are associated with increased rates of infection due to its porous nature. Here we present such a rare case of a 32 yr old male patient who presented to us with head injury following an assault.</p>
--	--

CASE REPORT

After receiving the approval of the institutional ethics committee and obtaining an informed consent from participating human subject we are hereby report a case of a 32 year old male patient who was brought to the casualty with history of assault with a wooden plank. There was no history of loss of consciousness or Bleeding from Ear, Nose, or Throat or injury to chest and abdomen. Glasgow Coma Scale was 12/15. Patient was hemodynamically stable and did not exhibit any features of raised intra cranial pressure (except for papilloedema on fundoscopy) or neurological deficits. Local examination revealed a laceration approximately 4*3 cm over left fronto parietal region with underlying depressed fracture.

Patient was admitted to the emergency ward under neurosurgery and was subjected to CT Scan brain plain that revealed left fronto parietal haemorrhagic contusion, Acute left temporoparietal Subdural Haemorrhage extending till the frontal region, with mild midline shift

(3.5 mm shift to the right) (fig-1) pneumocephalus, and comminuted fractures of the skull (left temporal, parietal and frontal bone) (fig-2). Haematological evaluation was unremarkable and patient was posted for an emergency surgery for elevation of the depressed segment of the skull and decompression under General Anaesthesia.

Intra Operatively multiple bony pieces of depressed segment were removed, a wooden piece was felt underneath (fig-3). Careful exploration was done and the wooden piece approximately measuring 3.5*2.5 cm was extracted in Toto (fig-4); specimen was taken for culture, decompression was done and after ensuring a complete haemostasis, the lacerated wound was thoroughly cleaned. Wound closure with primary suturing was done. Patient was put on IV antibiotics and prophylactic anti convulsants along with IV mannitol was given. Patient recovered well and is on regular follow ups. Post operative CT scan was done and no underlying bleed was seen (fig-5).



Figure 1. Acute left temporoparietal Subdural Haemorrhage extending till the frontal region, with mild midline shift (3.5 mm shift to the right)

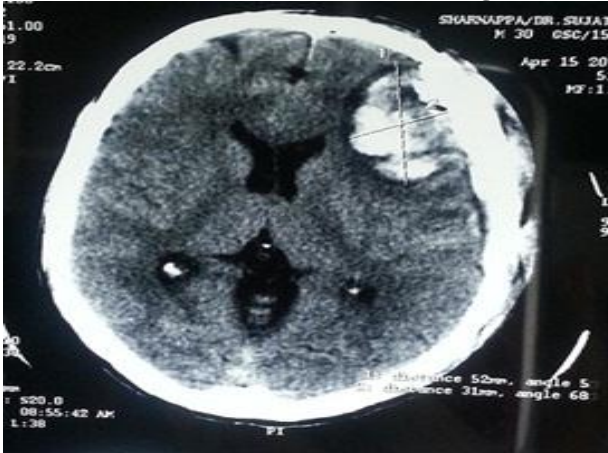

Figure 2. CT scan showing comminuted fractures of the skull (left temporal, parietal and frontal bone)

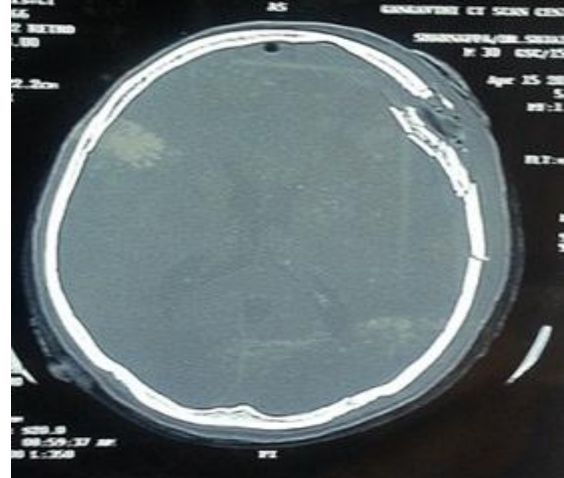


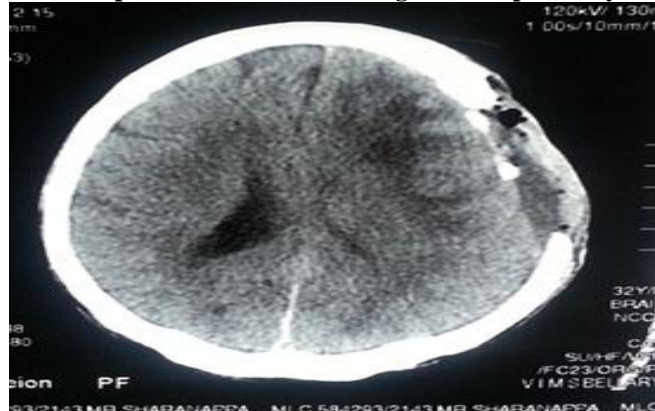
Figure 3. Showing retained intra cranial wooden pieces

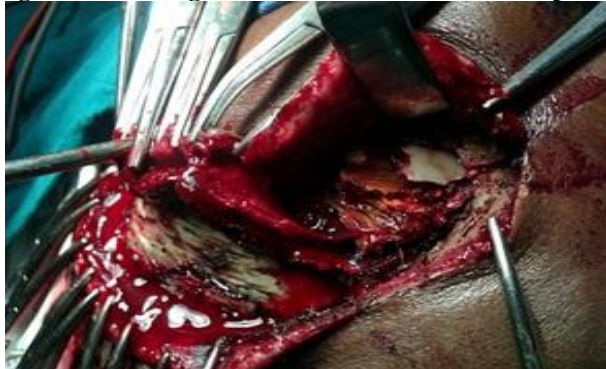

Figure 4. Extracted wooden pieces

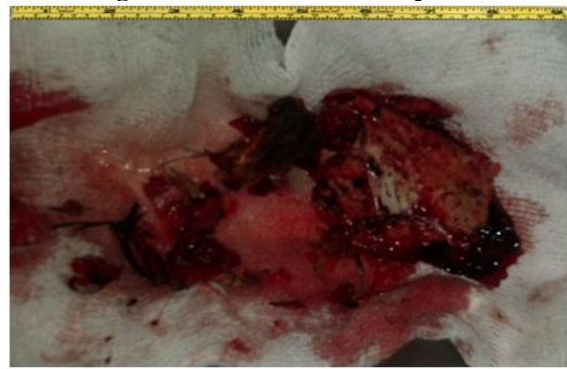

Figure 5. Post-operative CT scan showing no intra parenchymal bleed.



DISCUSSION

Non missile Penetrating injuries of the skull and Brain are relatively uncommon wounds. While most penetrating injuries in Western countries are caused by Gun shot wounds, interestingly, this is quite different in developing countries. There is a variety of non missile penetrating injuries that can occur with weapons ranging from knives, scissors, wooden planks, stones etc. These injuries are defined as wounds that involve a smaller area with relatively low velocity impact [1]. Most penetrating skull injuries, regardless of the size of penetrating bodies,

are rarely associated with major neurological symptoms, except in high velocity injuries. In this case a large amount of kinetic energy contact with the skull and the force probably acts for a shorter time which causes local deformation resulting in penetration and skull fracture [1-3]. Depressed skull fractures present as a complex problem, and are estimated to occur with the annual rate of 20 to 60 per 1 million, although this statistics varies among countries. Most commonly these fractures are located in the frontal and parietal bones; and are open and have



lacerations of the Dura with cortical injury. Early diagnosis and appropriate treatment of compound depressed fractures of the skull can minimize the risk of complications. Radiological assessment helps in the determination of the extent of injury and consists of CT scan Brain, skull radiograph and magnetic resonance imaging. CT scan can delineate the path and location of the embedded foreign body, bone or any retained foreign body fragments and the extent of intracranial damage [2,4-6] as in our case based on which the patient was timely operated and the multiple bony pieces of depressed segment were removed and along with the retained wooden foreign body. If timely intervention in such cases is not done secondary infections flare up resulting in subdural abscess formations leading to increased morbidity in terms of neurological deficits, seizures, scalp cellulitis, osteomyelitis, epidural empyemas, meningitis, ventriculitis, cerebritis, and brain abscess and even death. To prevent infection Intravenous antibiotics must be started in every case and intra operative cultures should be obtained [4,5]. In our case third generation cephalosporins were started and cultures were negative.

Intra cranial foreign bodies are very rare, early surgical exploration is successful in such cases. Different approaches can be chosen depending upon the location of the fragment. In every case after adequate resuscitation, the

goal of surgery is safe removal of the foreign body followed with careful debridement without causing further damage to the brain tissue [3,6,7].

CONCLUSION

Retained intra cranial wooden foreign body often poses a different set of challenges. Radiological difficulties and increased rates of infection due to its porous nature make these types of injuries more difficult. Thorough knowledge and understanding of such injuries helps in the appropriate treatment viz early debridement and use of adequate antibiotics thereby minimize the risk of complications.

ACKNOWLEDGEMENT

Authors acknowledge the immense help received from the scholars whose articles are cited and included in references of this manuscript. The authors are also grateful to authors / editors / publishers of all those articles, journals and books from where the literature for this article has been reviewed and discussed.

CONFLICT OF INTEREST

The authors hereby declare that there is no conflict of interest. This article has not received any funding and has no vested commercial interest.

REFERENCES

1. Trask TW, Narayan RK. (1996). Civilian penetrating head injury, In, Narayan RK, Wilberger JE, Povlishock JT, (editors), Neurotrauma. New York, McGraw Hill, 868-89.
2. Tibbs RE, Lee DC, Parent AD. (2003). Depressed skull fracture, in Batjer HH, Loftus CM, (eds), Textbook of Neurological Surgery, Principles and Practice. Philadelphia, Lippincott Williams and Wilkins, 1082- 95
3. Gennarelli TA, Champion HR, Sacco WJ, Copes WS, Alves WM. (1989). Mortality of patients with head injury and extracranial injury treated in trauma centers. *J Trauma*, 29, 1193-201.
4. Aarabi B, Cook J. (2005). Missile wounds of the head, In, Reilly PL, Bullock R, (editors). Head Injury, Pathophysiology and Management, 2nd ed. UK, Hodder Arnold Publishing, 384-403.
5. Valadka AB. (2003). Penetrating Cranial Trauma, In, Batjer HH, Loftus CM, (editors), Textbook of Neurological Surgery, Principles and Practice. Philadelphia, Lippincott Williams and Wilkins, 2851-9.
6. Dutcher S, Sood S, Ham S, Canady AI. (2001). Depressed Skull Fractures, In McLone DG, (editor), Pediatrics Neurosurgery, Surgery of the Developing Nervous System, 4th ed. USA, WB Saunders, 584-6.
7. Martin S, Raup GH, Cravens G, Arena-Marshall C. (2009). Management of Embedded Foreign Body, Penetrating Stab Wound to the Head. *J Trauma*, 16, 82-6.

