

## RANDOMISE VARIATION OF HEPATOBILIARY SYSTEM: EMBEDDED GALLBLADDER INTO THE LIVER

Serdar Yormaz\*, Huseyin Yilmaz, Husnu Alptekin, Ilhan Ece, Mustafa Sahin

Department of Surgery, Faculty of Medicine, Selcuk University, 42075, Konya, Turkey.

### Article Info

Received 23/10/2014

Revised 16/11/2014

Accepted 19/11/2014

### Key words:-

gallbladder,  
intrahepatic,  
Embedded.

### ABSTRACT

The occurrence of gallbladder into liver is well-documented incidental pathology but the underlying aetiology is not clear. Here, we describe a randomize anomaly of gallbladder in a 49 year old man with a known history of cholelithiasis, was admitted with a progressive pain over 6 months, without fever, or another symptoms where a gallbladder was found embedded into the liver. Ultrasonographic control described the presence of stones in the gallbladder. On first operation the gallbladder unsighted giving the impression of an agenesis and the bile duct was not approachable, at that time patient was referred to us perioperatively .In the second look we did not see the gallbladder and cystic duct too ,after a reflection area incision of liver, it was found that gallbladder was encapsulated and located in the liver. Gallbladder stones were palpated; after dissection of the area, then a difficult cholecystectomy was performed followed by cholangiography. The patient had a totally uneventful postoperative course. Therefore, in incidental cases, whatever the final diagnosis turns to be, either rudimenter or embedded, cholangiography and incision of reflective area can be useful for the final management of the patient.

### INTRODUCTION

The types of congenital anomalies of the gallbladder are known today and their incidence is very low. Among the ectopic gallbladder abnormalities, the intrahepatic gallstones abnormality is a very rare congenital anomaly and it is estimated that it occurs in the 4<sup>th</sup> week of life [1]. Here, we present an intrahepatic gallbladder case diagnosed with cholelithiasis, which referred to our clinic after observing in the operation that gallbladder was absent.

### Case report

49 years old male patient with right upper quadrant pain for 6 months had been prepared for surgery after diagnosed as cholelithiasis through USG (Ultrasonography) performed in another center. No additional problems have been identified in the

preoperative examination of the patient. All of the complications were explained to the patient and informed consent were taken. During operation, the gallbladder had not been observed in its location, and patient referred immediately to our clinic postoperatively; then the patient underwent surgery in our clinic on postoperative 2<sup>nd</sup> day. There was an operation history of the patient due to cyst in the liver 15 years ago; and there was a median incision scar above the navel and there was no additional feature.

### Operative Technique

Under general anesthesia, the surgery was started through an incision above the navel median area, which was the location of the previous operation. The gallbladder was not observed in its location in the first exploration. After dissection of adhesions from previous operations, the choledochus was found. It wasn't possible to locate gallbladder by following the choledochus. Then, the surrounding of the possible localization of the gallbladder on liver was aspirated by entering with an injector. The area was dissected after observing dense bile sludge

Corresponding Author

**Serdar Yormaz**

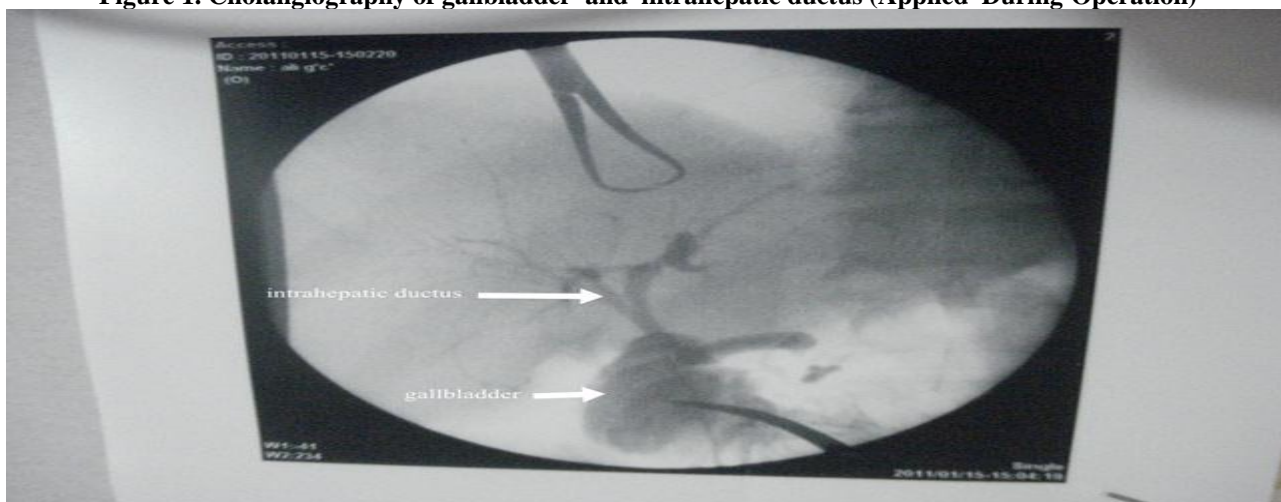
Email: - [serdaryormaz@gmail.com](mailto:serdaryormaz@gmail.com)



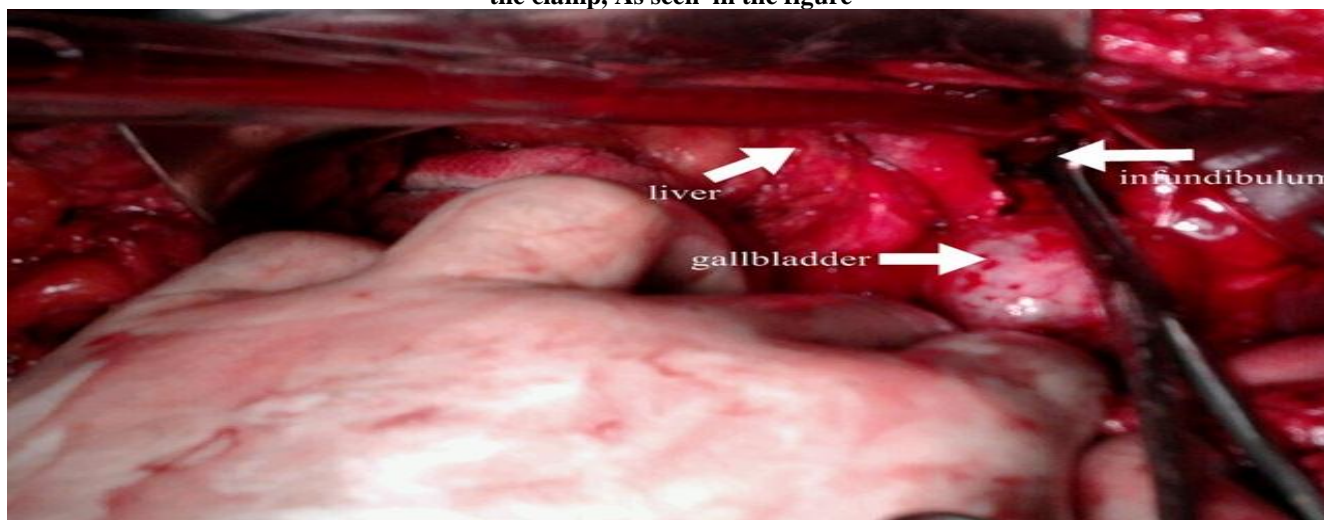
during aspiration performed with an injector in the possible localisation of the gallbladder, and the gallbladder was found, and liver parenchyma was separated (figure 1). After the hepatoduodenal ligament and hepatic hilus were revealed, the cystic duct and artery were seen alongside. It was found that the cystic artery comes out of the right hepatic artery. No additional anomaly was detected after the anatomical structures were dissected and revealed thoroughly. First, the cystic artery was connected and cut. Then, cholecystectomy was completed after the cystic duct

was cut and clamped on its proximal. A contrast agent was administered in the cystic duct to see hepatic and common bile duct branching, and images of the hepatic tree, intrahepatic paths and choledochus were taken (figure 2). There were no additional pathology. Cystic duct was ligated, one drainage tube was placed in subhepatic area and closed. 2 days after surgery, the patient's drain was removed due to lack of drainage. After waiting one more day, the patient was discharged on the 3<sup>rd</sup> postoperative day.

**Figure 1. Cholangiography of gallbladder and intrahepatic ductus (Applied During Operation)**



**Figure 2. View of gallbladder and infundibulum finding into the liver during the operation Infundibulum showed by the clamp, As seen in the figure**



## DISCUSSION

Gallbladder is normally located on the right of the falciform ligament, in the plane of the middle hepatic vein, in between right anterior sector and left medial segment. Intrahepatic gallbladder is a rare localization anomaly, and it is observed by 0.2% in population. Aberrant gallbladder can be any of the three different types, which are left, intrahepatic, and mobile types (1,2).

Among them, intrahepatic gallbladder is a very rare anomaly of 0.05% incidence. The first notification of anomalies was reported by Morgagni in 1769. Intrahepatic gallbladder may give an impression that it was not present since it is embedded in the liver parenchyma. The presence of this anomaly can only be seen by computed tomography or ultrasound [2]. The risk of stones in gallbladder is high. We haven't found an additional

finding, other than the clinical information given by the previous surgeon who had referred the patient to our clinic.

It is necessary to consider agenesis of the gallbladder in the differential diagnosis of intrahepatic gallbladder as well, which is an anomaly often confused with intrahepatic gallbladder abnormalities. Agenesis of the gallbladder has been presented in a case study by Aksoy et al [4].

Senecail et al. [2] have evaluated 1823 patients with USG, and as a result of their study, they have found a morphological variation or anomaly in more than 33% of gallbladders, a topographical variation by 3.5% approximately, and duplication in 3 cases [3,4]. This abnormal condition may be present alone or intraabdominal or intrahepatic anomalies may accompany this condition.

In a 30-year demographic study carried out by Chang et al. [5], the anomalies of gallbladder were reported as rare and genetic factors and hormonal drugs were considered as the reasons for these anomalies.

Intrahepatic gallbladder is rare case where surgeons are not accustomed to. Often it is characterized by the presence of stones, and the reason for patient's admission is the pain caused by stones usually. Anomalies that may be encountered during operations may lead to bile duct injuries and bleeding. As seen in our case, the localization anomaly cannot be understood in preoperative period in most cases. Although intrahepatic gallbladder diagnosis cannot be made in ultrasound clearly, advanced imaging techniques such as CT (computed tomography) scanning was helpful in the diagnosis; and it has been stated that imaging the biliary tract by cholangiography may be useful in preoperative conditions [6]. In this way, possible complications during surgery and iatrogenic injuries can be avoided. Intraoperative cholangiography application is an important diagnostic imaging method in our case and in pathologies with similar anomalies for diagnosis and reducing the potential complications. Intraoperative cholangiography helps by providing high-quality images for imaging normal anatomies and variations of the biliary tract and for evaluating whether

## REFERENCES

1. Skandalakis JE, Gray SW, Skandalakis LJ. , Skandalakis NP, Rowe JS, Nichols JJ. (2009). Editors Surgical Anatomy, Embryologic and Anatomic Basis of Modern Surgery 2nd ed, Atlanta, Georgia, 560-67
2. Senecail B, Texier F, Kergastel I, Patin-Philippe L. (2000). Anatomic variability and congenital anomalies of the gallbladder, Ultrasonographic study of 1823 patients. *Morphologie*, 84(264), 35-9.
3. Molmenti EP, Pinto PA, Klein J, Klein AS. (2003). Normal and variant arterial supply of the liver and gallbladder. *Pediatr Transplant*, 7(1), 80-82.
4. Aksoy F. , Demiral G. , Özçelik AA. (2008). Agenesis of gallbladder diagnosed unexpectedly during a laparotomy for cholecystectomy. *Marmara MJ*, 21(3), 252-256
5. Chang YR, Jang JY, Kwon W, Park JW, Kang MJ, Ryu JK et al. (2013). Changes in demographic features of gallstone disease, 30 years of surgically treated patients. *Gut Liver*, 7(6), 719-24.
6. Farnik H. , Weigt J, Malferteiner P. , Grützman A. , Gossner L. , Friedrichrust M. et al. (2014). A multicenter study on the role of direct retrograde cholangioscopy in patients with inconclusive endoscopic retrograde cholangiography. *Endoscopy*, 46(01), 16-21.

surgical clips were inserted correctly. However, this technically difficult procedure extends the period of operation, and has unsatisfactory, low success rates (71%) [7]. Since mobilization and resection of the cystic duct is required for injection of contrast material, confusing another ductal structure (such as choledochus) with cystic duct will cause injury during imaging process [7].

Although the specificity is low, the contrast agents have higher side effects, and ionizing radiation is used in three-dimensional helical CT cholangiography, it has higher reported success rate (97%) in imaging biliary anatomy and variations. [8]. In the light of recent studies by Ishikawa et al [9], three-dimensional CT cholangiography is reported as a clinically useful method in the preoperative evaluation of biliary anatomy Cabada et al [10] performed evaluations through three-dimensional reconstructions in their helical CT cholangiography study consisting of 101 patients. In their study, they have identified anatomic variations on biliary tree in 23 of the 101 cases (22.7%).

In our case, intraoperative cholangiography was performed on the patient for controlling the bile duct, and bile duct was found intact and it was possible to see the location of the connection of cystic duct to choledochus. In case of anomalies of the gallbladder, one should be prepared against possible abnormalities of the gallbladder for a safe surgery.

## CONCLUSION

As a result, as well as the rarely encountered cases of intrahepatic gallbladder, agenesis and other aberrant gallbladder pathologies should always be taken into consideration. Every surgeon should be careful of this type of injuries, and cholangiography must be performed after identifying the gallbladder against possible anomalies.

**Conflict Of Interest:** Serdar Yormaz and co –authors have no conflict of interest and financial support.



7. Aguirre-Olmedo I, Fernández-Castro E, González-Angulo Rocha JA, Cárdenas-Lailson LE, Beristain-Hernández JL. (2011). Anatomic variants of biliary ducts detected by endoscopic colangiography. *Rev Gastroenterol Mex*, 76(4), 331-8.
8. Kocaoğlu M, Uğurel MŞ, Bulakbaşı N, Somuncu İ. (2005). MR cholangiopancreatography of a case with a biliary tract variation and postoperative biliary duct injury. *Diag İnterv Radiol*, 11, 219-221.
9. Ishikawa M, Tagami Y, Toyota T, Nishioka M, Hanaki N, Sasaki K et al. (2000). Can three-dimensional Helical CT cholangiography before laparoscopic cholecystectomy be a substitute study for endoscopic retrograde cholangiography?. *Surgical Laparoscopy, Endoscopy & percutaneous Techniques*, 10(6) , 351-356
10. Cabada GT, Sarria ODTL, Martinez-Berganza AMT , Cozcolluela Cabrejas R, Alberdi Ibáñez I, Alvarez López A, et al. (2002). Helical CT cholangiography in the evaluation of the biliary tract, application to the diagnosis of choledocholithiasis. *Abdom Imaging*, 27 (1), 61-70.

