



EXPERIENCE OF SYPHILITIC AORTIC ANEURYSM – A CASE REPORT

Deivam S^{1*}, Guru T. Arun², Prabhu N³, Balasubramanian N¹

Department of Skin and STD¹, Radiodiagnosis² and Microbiology³,
Chennai Medical College Hospital and Research Centre (SRM Group), Tiruchirapalli – 621 105, Tamilnadu, India.

Corresponding Author:- **S.Deivam**
E-mail: leptoprabhu@gmail.com

<p>Article Info Received 15/10/2014 Revised 27/11/2014 Accepted 02/12/2014</p> <p>Key words: Ascending aorta dilatation, Syphilis, Radiography.</p>	<p>ABSTRACT Syphilitic aortic aneurysm is a rare occurrence in the antibiotic era, making the diagnose assumption even more infrequent. Nonetheless, this pathology can appear and should be suspected in patients with aortic aneurysm. We report a case of a 52-year old patient who presents with cardiovascular syphilis and, in the following study; a large ascending aorta aneurysm is identified. The authors discuss the diagnostic challenge, the epidemiologic concerns, surgical indication, treatment and subsequent follow-up.</p>
---	---

INTRODUCTION

The incidence of late manifestations of syphilis has declined almost to a rare entity since the era of antibiotics. Before the discovery of penicillin, tertiary syphilis infection was the most common cause of thoracic aortic aneurysm, resulting in 5–10% of cardiovascular deaths. The primary lesion of cardiovascular syphilis is aortitis, an inflammatory response to the invasion of the aortic wall by the *Treponema pallidum* that evolves to obliterative endarteritis of the vasa vasorum and results in necrosis of the elastic fibres and connective tissue in the aortic media [1]. Syphilitic aortitis takes place during the stage of tertiary syphilis between 5 to 30 years after appearance of primary syphilis. This is normally due to infection of aorta secondary to endarteritis obliterans of vasa-vasorum. Aortic wall becomes progressively weakened due to chronic inflammation. This will subsequently lead to aneurysm (10%), coronary artery narrowing at ostium (30%) and aortic valve insufficiency secondary to the involvement of aortic valve [2,3].

The resulting weakening of the aortic wall will progress into the late vascular manifestations of syphilis. Syphilitic aortitis is reported in 70–80% of untreated cases

after the primary infection, and in 10% of these patients, significant cardiovascular complications will occur, such as aortic aneurysm, aortic regurgitation and coronary ostia stenosis. The ascending aorta is the segment most commonly affected (50%), followed by the arch (35%) and the descending aorta (15%). The rich lymphatic arrangement in the ascending aorta that may predispose greater mesoaortitis is believed to be the cause for larger involvement of this segment [4]. Cardiovascular syphilis is a late form of syphilis, which usually manifests in the 4th–5th decade of life, typically 5–40 years after the primary infection [5,6]. It may become symptomatic with thoracic pain or symptoms of compression of the surrounding structures, but can enlarge asymptotically until incidental finding in chest X-ray or a catastrophic and often fatal aneurysmal rupture. Without surgical treatment, the mortality rate at 1 year can reach 80% due to the high rate of rupture of these aneurysms [5,6].

In the natural course of cardiovascular syphilis, the primary infection is followed by *T. pallidum* invasion of the aortic wall, initially within the adventitia and soon thereafter in the lymphatic vessels. The rich



lymphatic system of the ascending aorta is one of the main reasons for the tropism of spirochetes there. The vasa vasorum then undergoes a process of endarteritis obliterans, necrosis of medial layer (mesoarteritis) and infiltration of plasma cells [7]. Consequently, the elastic tissue of the vessel is destroyed and replaced by scar tissue. The inflammatory process may continue for as long as 25 years after the initial infection. The initial clinical presentation may then be of angina when there is obstruction of the coronary ostia or dyspnea when there is aortic valve incompetence or compression of the respiratory organs. However, the most common clinical symptom is chest pain secondary to rapid expansion of the aortic aneurysm [8]. A case report previously reported describes an abnormally advanced syphilitic aortic aneurysm for such a young patient, a condition likely exacerbated by his HIV infection [9]. The rupture of this aneurysm resulted in hypovolemic shock and sudden death, a tragedy, which could have been prevented with existing treatment, adequate screening, and additional resources. The authors report a currently rare case of syphilitic ascending aorta aneurysm at tertiary care teaching hospital in Tiruchirapalli, India.

Case report

A 52 year old male patient admitted with the complaints of vomiting, dyspnea and loss of appetite for 6 months duration. There was no co morbid association. He was an alcoholic for about 29 years with almost daily intake of alcohol. On examination, he was conscious and general examinations including vital signs were all normal. Cardiovascular and Respiratory systems were normal. Abdomen was soft on palpation with few dilated veins. Tremors of hands were present. With the apparently

normal examination, except for dilated neck veins and the history of alcoholism, he was provisionally diagnosed as acid peptic disease and treated accordingly. During the evaluation of dyspnea, a chest x-ray was taken and it showed anterior mediastinal mass.

On further work-up, CECT study of thorax showed large focally dilated contrast opacified ascending aorta with peripherally unenhancing hypodense thrombus and calcification involving ascending aorta extending to right side of anterior mediastinum. SVC was compressed suggestive of ascending aorta aneurysm. The non contrast axial image shows abnormal aneurysmal dilatation of arch of aorta with peripheral calcification and CECT axial image showed aneurysmal dilatation of arch of aorta are depicted in Figure 1 and 2 respectively. Entire lumen size was 11 cms, thrombus thickness is 4 cm, lumen size 6 cms. Figure 3 suggested the CECT sagittal image shows aneurysmal dilatation of the aortic root, ascending aorta, arch of aorta and descending thoracic aorta where the peripherally non-enhancing hypodense thrombus seen. Figure 4 suggested CECT axial image shows aneurysmal dilatation of arch and descending aorta with peripherally located thrombus.

ECHO suggested Mediastinal mass lymphoma. The scout image shows left side radio-opacification (Figure 5). Cardiothoracic surgeon opinion was obtained and suggested angiogram, fasting lipid profile, renal function test and blood VDRL for further evaluation of mediastinal compression syndrome. RPR was reactive in 128 dilutions. TPHA was also found to be reactive. He was diagnosed as a case of syphilitic aortic aneurysm and treated with procaine penicillin 8 lakh units for 20 days. The patient was referred to higher centre for further management.

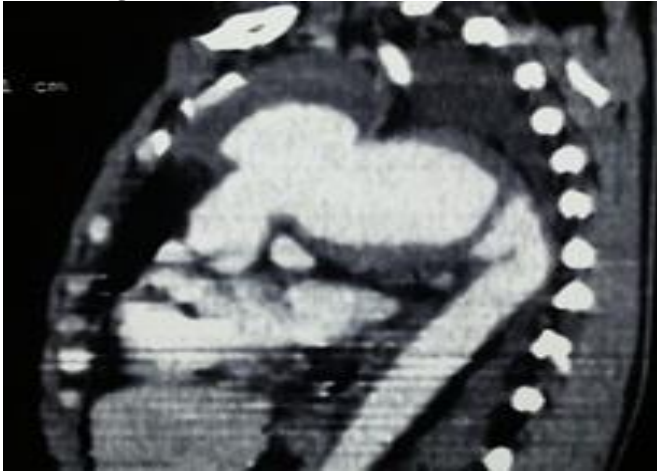
Fig 1. Non-contrast axial image shows abnormal aneurysmal dilatation of arch of aorta with peripheral calcification

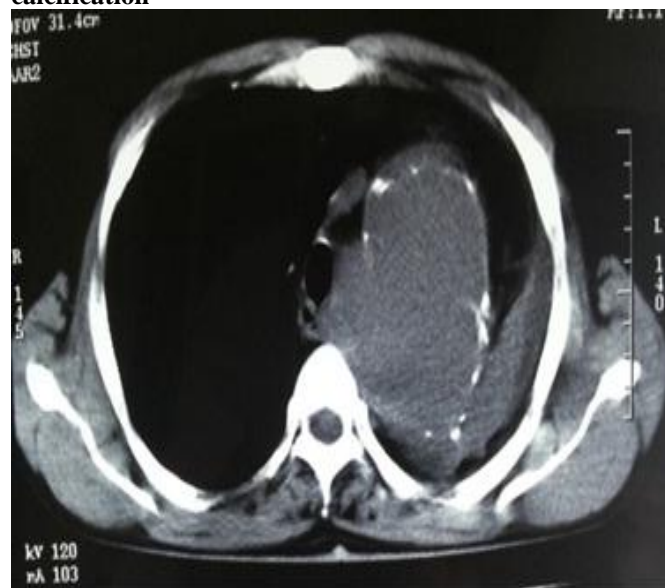

Fig 2. CECT axial image shows aneurysmal dilatation of arch of aorta

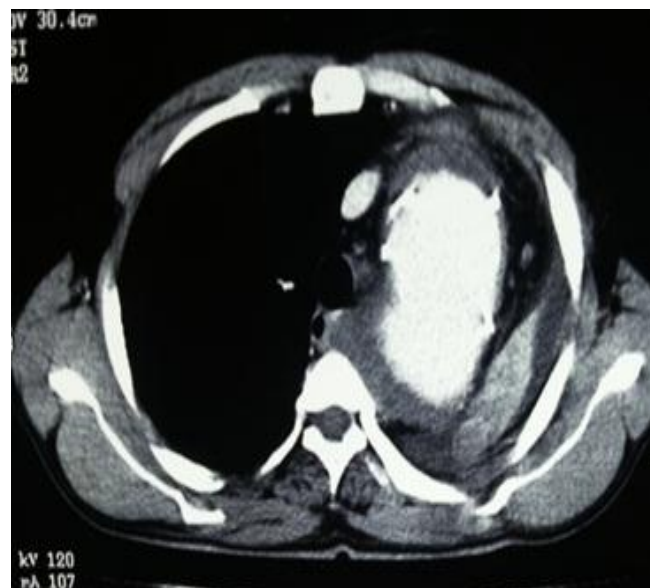

Fig 3. CECT sagittal image shows aneurysmal dilatation of the aortic root, ascending aorta, arch of aorta and descending thoracic aorta



[Note: Peripherally non-enhancing hypodense thrombus seen]

Fig 4. CECT axial image shows aneurysmal dilatation of arch and descending aorta with peripherally located thrombus

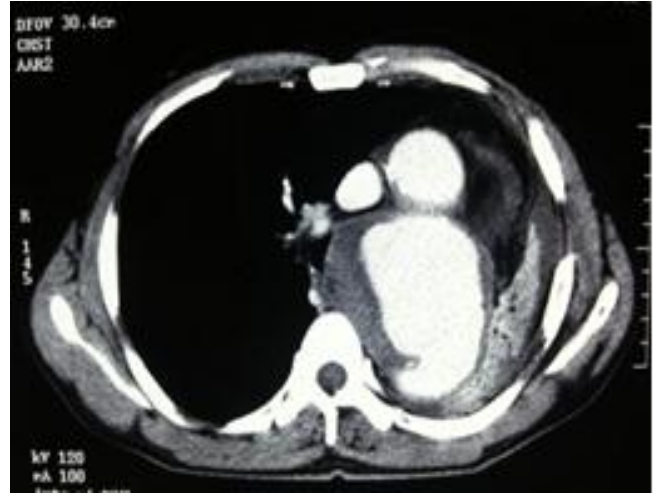
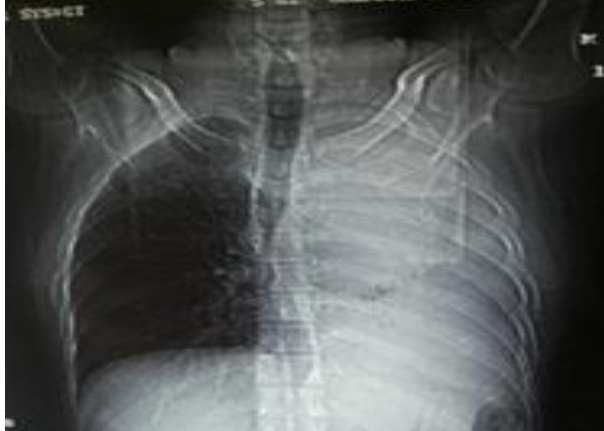
Fig 5. Scout image shows left side radio-opacification



DISCUSSION

Syphilis, the great imitator, the disease per se has become a rare occurrence. The reason being said is the wide use of antibiotics for other infections. Cardiovascular syphilis is the tertiary stage which occurs 15 to 30 years after primary syphilis. The changes are more marked in ascending aorta and aortic arch but syphilitic aneurysm have been reported in descending aorta also [10]. We present the case for its rarity in this era of higher antibiotics usage and also to emphasize the need for adequate therapy when a case of syphilis is diagnosed because inadequate therapy advances complications. We should always have a high index of suspicion and rule out cardiovascular syphilis in all the cases of mediastinal mass especially in adults of 4th to 5th decade as in our patient he was admitted for alcoholic gastritis and the aneurysm is an incidental finding.

Tertiary syphilis with cardiovascular complications is a rarity in the antibiotic era in developed nations although diagnoses of syphilitic aortitis are not

uncommon in developing countries. It usually presents in the 4th to 5th decade of life and is unusual in the elderly.

Aortic aneurysms and aortic regurgitation due to aortic root dilatation is the usual presentation. Nevertheless, it can remain undetected for the duration of its latent period which may extend upto 40 years and is often diagnosed on routine evaluation [11].

Syphilitic aortitis causes focal destruction of the media, with loss of the elastic smooth muscle fibres and scarring. This leads to an aortic dilatation and an aneurysm. The most common sites of these TAAs are the ascending thoracic aorta (36% of the cases), followed by the aortic arch (34% cases), the proximal descending thoracic aorta (25% cases), and the distal descending thoracic aorta (5% cases). Aortic sinus involvement occurs in less than 1% of the cases and it is most often asymmetric [10,11]. In late Syphilis, the non-treponemal tests like the VDRL test and the rapid plasma reagin test are less sensitive (70%-75%) as compared to the treponema specific tests such as TPHA, the micro haemagglutination

assay and the fluorescent treponemal antibody absorption test (94%-95%).

The imaging of an aortic aneurysm is best done with CECT of the chest and CT angiography. The MRI and MR angiography are slightly superior to CT in the evaluation of an aortic dissection. Morphologically, the syphilitic aneurysms are saccular but about 25% are fusiform. A pencil-thin dystrophic aortic wall calcification is found in up to 40% of the patients. This is most severe in or is entirely confined to the ascending aorta. The delicate calcification is frequently obscured by the thick, irregular, coarse calcification of secondary atherosclerosis. In the cases of arteritis, the wall of the aneurysm is frequently

thickened [12].

The location of an aneurysm can provide clue to its cause. In a study on 249 aneurysms of the aorta and its branches, it was found that the involvement of the ascending aorta alone was usually associated with annuloaortic ectasia. In contrast, atherosclerosis is a more diffuse process and it rarely involves only the ascending aorta [10,11]. We discuss the diagnostic challenge due to the unusually long latent period in our patient, the epidemiologic concerns, treatment options and possible complications.

REFERENCES

1. Revest M, Decaux O, Frouget T, Cazalets C, Cador B, Jego P. (2006). Syphilitic aortitis. Experience of an internal medicine unit. *Rev Med Intern.*, 27, 16-20.
2. Agarwal P, Chughtai A, Matzinger F. (2009). Multidetector CT of Thoracic Aortic Aneurysms. *Radiograph.*, 29, 537-552.
3. Bonnicksen CR, Sundt TM, Anavekar NS. (2011). Aneurysms of the ascending aorta and arch: the role of imaging in diagnosis and surgical management. *Expert Rev Cardiovasc Ther.*, 9, 45-61.
4. Isselbacher EM. (2005). Thoracic and abdominal aortic aneurysms. *Circul*, 111, 816-828.
5. Salas MJ, Martínez CJL, González VN, Castillo CJL. (2000). Cardiovascular syphilis: a case report. *Rev Esp Cardiol.*, 53, 1656-1658.
6. Nelson P, Jose C, Luis V. (2012). Syphilitic aneurysm of the ascending aorta. *Interact Cardiovasc Thorac Surg*, 14, 223-225.
7. Williams J, Krishnan G, Devarajan H. (2002). Syphilitic abdominal aortic aneurysm. *AIDS Patient Care and STDs*. 16, 467-470.
8. Chetty R, Batitang S, Nair R. (2000). Large artery vasculopathy in HIV-positive patients: another vasculitic enigma. *Hum Pathol.*, 31, 374-9.
9. Juan CC, Isabel CR. (2011). Syphilitic aortic aneurysm in a young HIV infected man: case presentation. *Case Rep Infect Dis*.
10. Restrepo CS, Ocazonez D, Suri R. (2011). Aortitis: imaging spectrum of the infectious and inflammatory conditions of the aorta. *Radiograph*. 31, 435-51.
11. Müller AM, Hoffmann J, Weber A. (2004). Differential diagnosis of saccular aneurysms of the isthmus aortae: example of a penetrating atherosclerotic ulcer. Case-report and review of the literature. *Chirurg*, 75, 713-738.
12. Youatou P, Derluyn M, Roman A. (2004). Ascending aorta syphilitic aneurysm presenting as a dystrophic disease. *Acta Chir Belg.*, 104, 231-233.

