



**POST-OPERATIVE OBSTRUCTED INTERNAL PARACECAL
HERNIA THROUGH CONGENITAL MESENTERIC DEFECT
PRESENTING AFTER TRANSVAGINAL SURGERY IN
AN 83-YEAR-OLD LADY**

Cho Cho*¹, Govani Dhaval², Bako Abdulmalik², Dhawan Vikram³ and Patel Ramnik⁴

¹Specialist Registrar, Dept of O & G, Chesterfield Royal Hospital, Calow, Chesterfield, Derbyshire, UK.

²Medical Student, University of Birmingham Medical School, Pilgrim Hospital, O & G, Birmingham, UK.

³QMC, Nottingham, O & G, UK.

⁴Clinical Fellow, Pediatric Urology, UCLH and GOSH, UK.

Corresponding Author:- **Cho Cho**
E-mail: cho.cho.dr@gmail.com

<p>Article Info <i>Received 12/11/2014</i> <i>Revised 20/11/2014</i> <i>Accepted 26/12/2014</i></p> <p>Key words: Congenital, mesenteric, Hernia, Intestinal obstruction, Post-operative, Midgut, Malrotation, Paracecal.</p>	<p>ABSTRACT</p> <p>An 83 -year-old lady with a genital prolapse had undergone elective transvaginal hysterectomy with pelvic floor repair uneventfully. She developed features of intestinal obstruction after initial recovery. Plain abdominal radiograph and ultrasound suggested low small bowel obstruction which was confirmed by CT scan and gastrograffin follow through study. She underwent exploratory laparotomy at which a congenital mesenteric defect was found in the ileocecal region with internal herniation of the terminal ileal loops through it. The defect was enlarged and hernial contents were reduced. The constriction rings at entry and exit sites were over sewn and bowel was viable without any need for resection. Paracecal internal hernia with a congenital defect in the mesentery presenting in the post-operative period is rare, interesting and challenging. Preoperative diagnosis is usually difficult. Gastrointestinal studies with contrast media and abdominal CT are helpful. Early diagnosis and prompt intervention and appropriate treatment reduce morbidity and mortality.</p>
---	--

INTRODUCTION

Congenital lesions leading to intestinal obstructions secondary to internal herniation are generally seen in neonatal and pediatric age group and its presentation in the post-operative period has been reported earlier but mainly in the paraduodenal or paramesocolic region rather than paracecal region [1-2]. Internal hernias are rare causes of small bowel obstruction and diagnosis can be easily missed due to vague symptoms. Paracecal hernia is one of the internal hernias which accounts for 13 % of all internal hernias. Symptoms are usually nonspecific and old female patients are particularly vulnerable. Computed tomography plays an important role in early diagnosis. We report a case of small bowel obstruction due to paracecal hernia after vaginal surgery.

Case report

An 83 -year-old female patient suffering from a genital uterovaginal prolapse and with a background of hypertension and systemic lupus erythematosus (SLE) was admitted electively. She never had any abdominal surgery previously.

She underwent elective transvaginal hysterectomy with pelvic floor repair and sacrospinous fixation of vaginal vault uneventfully. She opened bowels on second post-operative day. However, she suddenly developed colicky abdominal pain, pallor, increasing vomiting despite antiemetic injections. Vomiting turned bilious followed by feculent associated with abdominal distension and absolute constipation.



Abdomen was markedly distended but non tender and bowel sounds were high pitched and exacerbated.

Urine dipstick, microscopy and culture were normal. Her electrolytes, renal and liver functions were within normal limits. Complete blood count showed haemoglobin 128 G/L, white cell count 21.3 X10⁹/L, neutrophils 18.3 X10⁹/L and C-reactive protein 94 mg/L.

Upright chest radiograph showed normal lungs and heart with a dilated loop of bowel in the upper abdomen (Figure 1). Plain abdominal radiograph showed multiple small bowel loops with *venae conniventes* and step ladder pattern suggesting a mechanical cause of bowel obstruction rather than a paralytic ileus or functional obstruction due to electrolyte imbalance and hypokalemia (Figure 2).

Abdominal ultrasound demonstrated dilated fluid filled bowel loops with strong peristalsis waves down to terminal ileum which was collapsed. Abdominal CT scan with 100 ml of Omnipaque 350 showed diffuse dilatation of small bowel loops down to terminal ileum which was collapsed and possibility of Meckel's diverticulum, congenital band or internal hernia was considered (Figure 4,5).

Passage of nasogastric tube drained 1.5 litre of bilious and feculent fluid. Gastrograffin follow through study via nasogastric tube showed dilated loops of small

bowel with contrast and faint contrast has reached the large bowel, features were suggestive of partial small bowel obstruction with luminal integrity.

Clinically delayed ileus due to electrolyte imbalance or infection and a remote possibility of post-operative intussusception were considered. After initial partial septic screen and imaging; low mechanical small bowel obstruction with differential diagnosis of Meckel's diverticulum, congenital band or internal hernia was considered.

Examination under anesthesia revealed a soft 6 cm size mass. She underwent exploratory laparotomy at which a congenital mesenteric defect of 10 cm diameter was found in the ileocecal region with internal herniation of the terminal ileal loops through the mesenteric defect causing mechanical obstruction. The herniated bowel loops were dusky and cyanosed and the defect was compressing the vascular pedicle of the herniated small bowel. The defect was enlarged and hernial contents were reduced. The constriction rings at entry and exit sites were over sewn and bowel was viable and there was no need for resection.

The post-operative period was uneventful; she made smooth recovery and discharged home on 5th post-operative day. At 3 year follow up she is asymptomatic and well.

Figure 1. Chest radiograph in erect position with normal chest and dilated loop in left abdomen

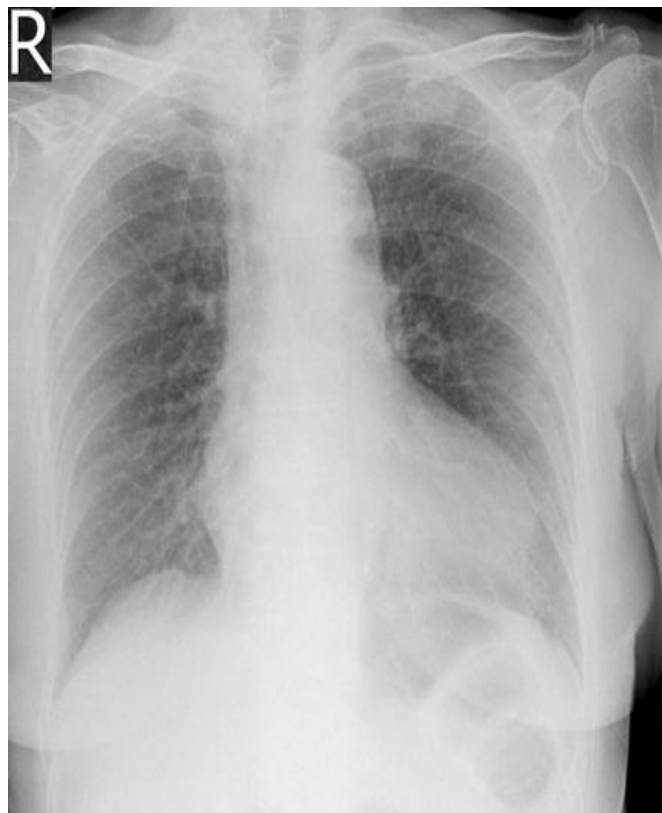

Figure 2. Abdominal radiograph showing multiple small bowel loops with step ladder pattern and *venae conniventes* of dilated jejunal loops suggestive of mechanical obstruction

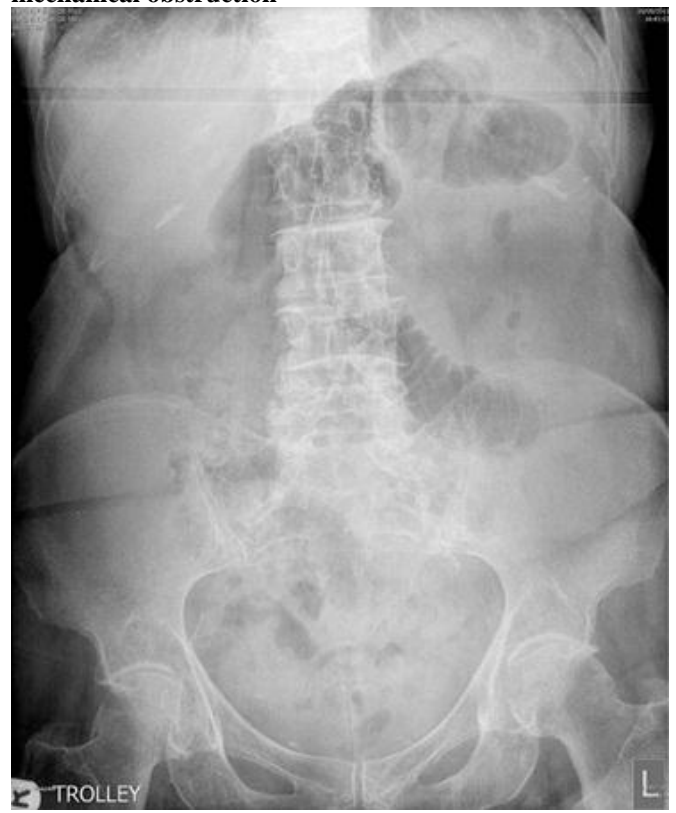


Figure 3. CT Scan of abdomen showing dilated small bowel loops in the upper abdomen

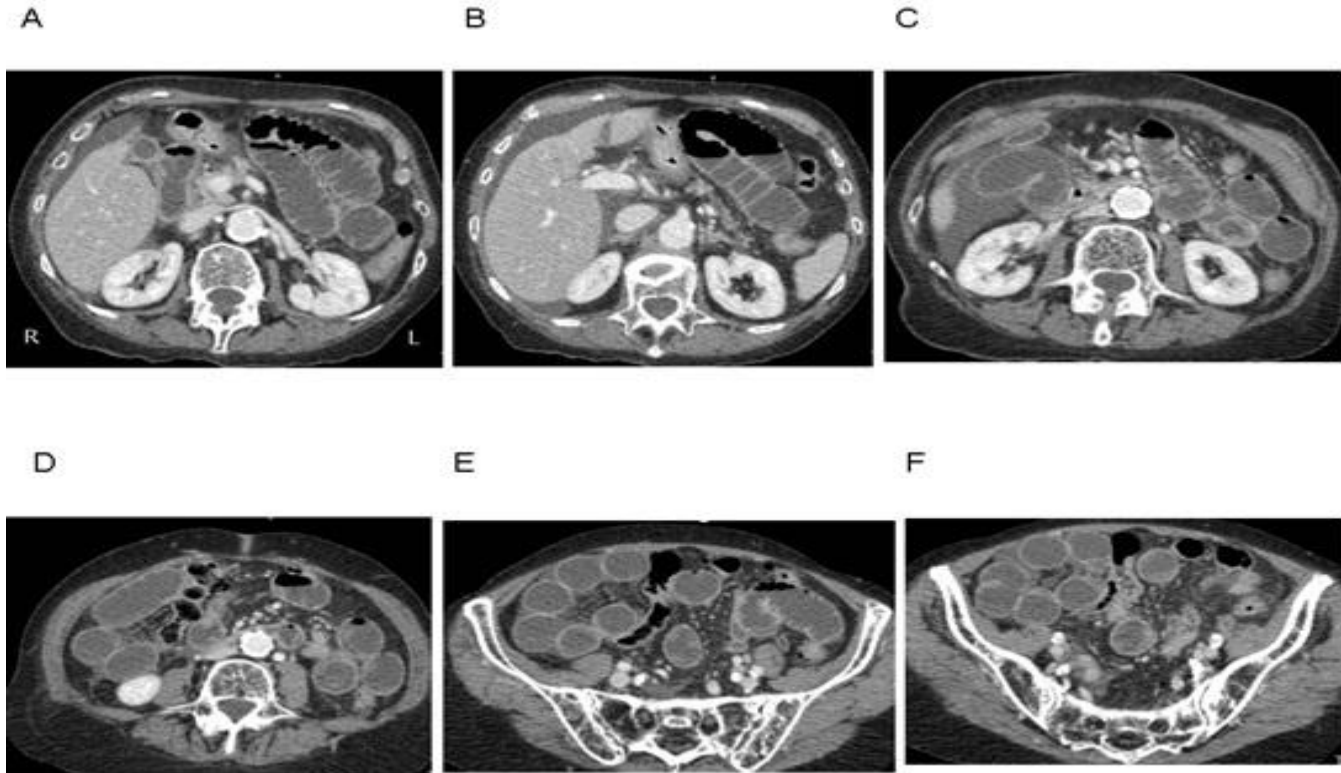
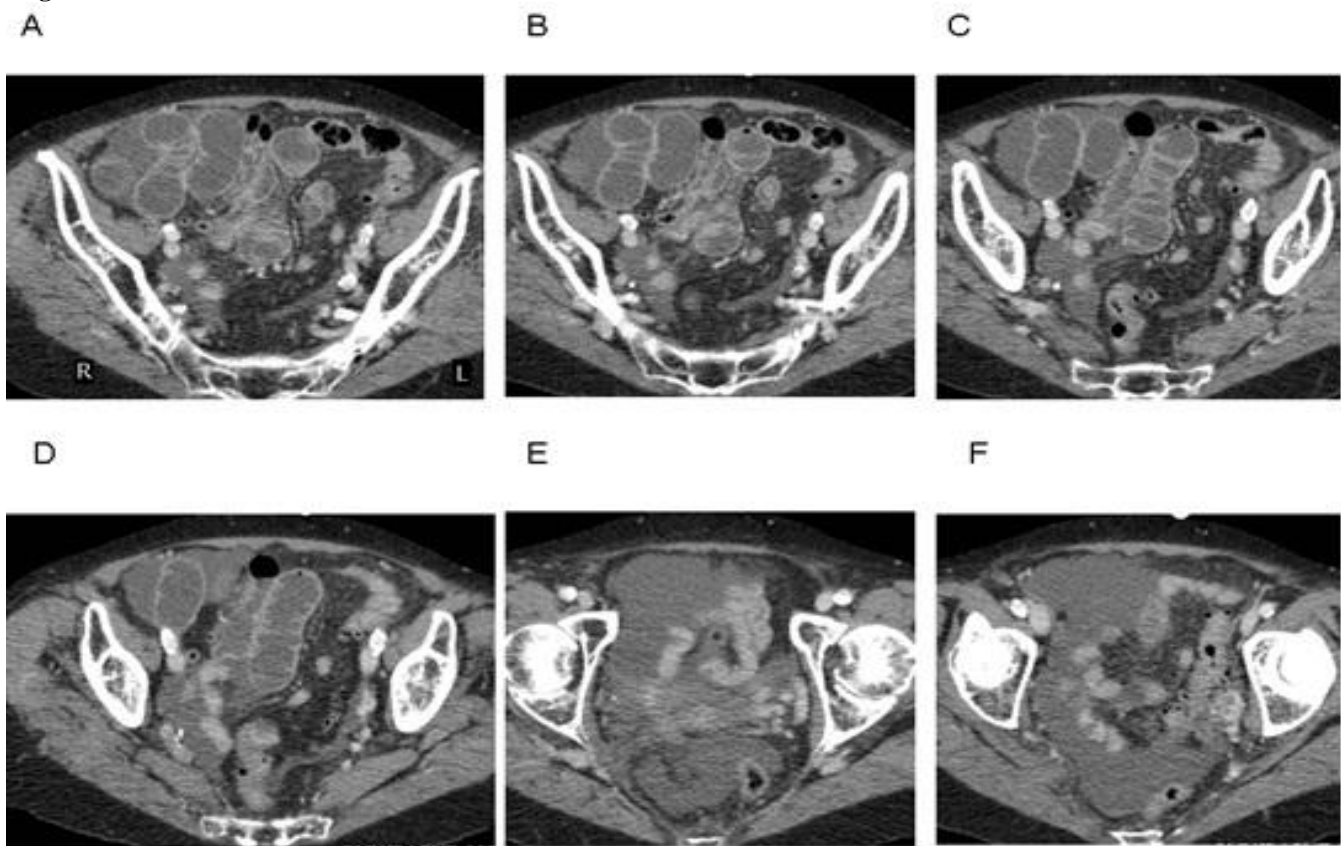


Figure 4. CT Scan of pelvis- note the collapsed small bowel loops with trickle of contrast and no gas in the rectum and large bowel



DISCUSSION

Small bowel obstruction is the one of the leading causes of acute surgical admission. Early diagnosis and timely intervention is important as delayed diagnosis can lead to fatal consequence of strangulation which is associated with tenfold increase in mortality. Hernias are the most common causes of strangulation in patients presenting with small bowel obstruction [1]. Internal hernias are the result of alteration in the normal process of intestinal rotation during embryological development and are the infrequent causes of small bowel obstruction [2]. Although internal hernias accounts for less than 1% of all abdominal hernias, they are responsible for up to 5.8% of all small bowel obstructions [3]. We here report a case of small bowel obstruction due to paracecal hernia. Paracecal hernia is one of the internal hernias that accounts for 13% of all internal hernias [4]. Internal hernias involve protrusion of viscera through the peritoneum or mesentery and into a compartment in the abdominal cavity [5]. The most common presentation is an acute intestinal obstruction of small bowel loops that develops through normal or abnormal apertures [6,7]. The responsible hernial orifices are usually pre-existing anatomical structures such as foramina, recesses or fosse. Pathological defects of the mesentery and visceral peritoneum, which are caused by the congenital mechanisms, surgery, trauma, inflammation, and circulation, are also potential hernial orifices [8].

In review of the embryological development of paracecal hernia, it is important to understand the rotation of midgut as those hernias are as a result of alteration of normal embryological development. The development of the cecum started from small budding and then subsequently exteriorised through anterior abdominal wall into umbilicus. The anatomy of the cecal and pericecal peritoneum is not determined until the 5th fetal month when the migration of the midgut is complete. After 5th month of fetal development, migrated midgut subsequently retracted into abdominal wall and cecum was fixed into right iliac fossa and peritoneal surfaces resolved. Alteration in this normal process of intestinal rotation predisposes to development of number of recesses or pockets [9]. Cecum is entirely retroperitoneal and cecal fossa is formed by two peritoneal folds: lateral fold is continuation of the white line of Toldt and medial fold is formed by peritoneal reflection of medial part of cecum. Superior and inferior ileocecal recesses are formed by a peritoneal fold originating from terminal ileum to cecum. Paracecal hernia commonly develop from a retrocecal recess is which formed by cecum anteriorly, the iliac fossa posteriorly, the colic gutter laterally and mesentery medially [10]. In our case, distal ileum was herniated through 10 cm mesocolic defect and symptoms were vague due to a large defect. Preoperative diagnosis of internal hernias is usually difficult due to rarity of the condition, slow development of the symptoms which may take up to months or years depending on the size and type of defects.

It may suggest that internal hernias get spontaneously reduced [11]. However; challenging diagnosis of internal hernias may lead into devastating consequences such as strangulation which is associated with high mortality (Ihedioha et al. 2006a). Paracecal hernia is rarest type of internal hernias and diagnosis can be easily missed. Presenting symptoms are epigastric discomfort, periumbilical pain, recurrent episodes of intestinal obstruction associated with some abnormal findings in the right lower abdomen, such as spontaneous pain, tenderness, or palpation of a mass lesion [12,13]. Ileal entrapment with incarcerated paracecal hernia can mimic acute appendicitis and high index of suspicion should be born in mind in the management of patients with localized peritonism and mass in right iliac fossa even in the absence of obstructive symptoms and presence of normal inflammatory markers. Paracecal hernias are usually associated with old female preponderance [11]. Computed tomography usually plays an important role in diagnosis of early or partial obstruction of all internal hernias. CT has superiority in revealing site, level and cause of obstruction and demonstrating threatening sign of bowel vitality. In addition, CT is also useful in revealing both intrinsic and extrinsic causes of small bowel obstruction such as masses, adenopathy, soft tissue infiltration, fluid collection and abscesses [14]. Combination of gastrointestinal studies enhanced with intraluminal contrast material presenting with post-operative intestinal obstruction and abdominal CT enables the accurate diagnosis of any type of internal hernia [15,16]. (Blachar, Federle 2002, Blachar et al. 2001) In our case, diagnosis was made by gastrograffin follow through study. The two characteristic features of CT findings suggestive of strangulation are sac like masses or clusters of dilated bowel loops and changes of mesenteric vascular pedicle which is engorged, stretched and displaced. These warning signs warrant immediate surgical intervention [17].

Management of small bowel obstruction is laparotomy. However, evidence indicates that small bowel obstruction due to internal hernias can be successfully managed laparoscopically. In low risk patients, laparoscopy offers combined advantages of immediate diagnosis and definitive treatment of acute pathology [18-20]. Internal hernias are rare causes of intestinal obstruction. Transmesenteric hernia is commonest type and usually associated with prior abdominal surgery. Paracecal hernia is rarest type of internal hernia and may or may not be preceded by prior surgery. (Blachar et al. 2001, Sciacca et al. 1997) Late diagnosis is associated with high morbidity and mortality. Knowledge of normal anatomy of the peritoneal cavity and characteristic anatomical location of each internal hernia helps to get early diagnosis and timely intervention. Computed tomography plays an important role in early diagnosis, identification of intrinsic and extrinsic causes and demonstration of threatening sign of bowel vitality. Most of the small bowel obstructions due



to paracecal hernias are managed by laparotomy without need for further bowel surgery. In low risk patients with early diagnosis, laparoscopic release of obstruction can lead to satisfactory outcome.

CONCLUSION

Paracecal internal hernia with a congenital defect in the mesentery is the rarest form of lesion in an octogenarian lady who had no previous abdominal surgery.

The occurrence in the post-operative period of transvaginal surgery makes it more challenging cause of small bowel obstruction. Preoperative diagnosis is usually difficult due to vague symptoms and rarity of the condition. Gastrointestinal studies with contrast media and abdominal CT can diagnose most of the internal hernias with high accuracy. Early diagnosis and prompt intervention and appropriate treatment reduce morbidity and mortality.

REFERENCES

1. Patel RV, Lawther S, Boneza S, et al. (2013). Neonatal Treitz's hernia with abdominal cocoon simulating volvulus neonatorum. *BMJ Case Reports*.
2. Patel R, Gabra HO, Nour S. (2010). Left paramesocolic hernia presenting as post appendicectomy abdominal cocoon. *Indian Pediatr*, 47, 969-671.
3. Jang E, Cho SH, Kim, D. (2011). A case of small bowel obstruction due to a paracecal hernia. *J Korean Soc Coloproctology*, 27, 41-43.
4. Mehta MH, Patel RV, Patel CK, et al. (1994). Peritoneal encapsulation and Abdominal cocoon in a male child. *Pediatr Surg Intl*, 9, 415-416.
5. Birchley D. (2009). Ileal entrapment within a paracaecal hernia mimicking acute appendicitis. *Ann Royal Coll Surg Eng*, 91, 1-3.
6. Barbary C, Floquet M, Riebel N et al. (2004). Small bowel obstruction caused by enteroliths and Meckel's diverticulitis associated with internal paracecal hernia in an adult. *J De Radiologie*, 85, 49-50.
7. Weiner RA, Pomhoff I, Schramm M et al. (2005). Complications after laparoscopic Roux-en-Y gastric bypass.", *Chirurgische Gastroenterologie Interdisziplinär*, 21, 13-22.
8. Coulier, B, Menten, R, Ramboux, A. (1999). Diagnosis using spiral computed tomography of an internal hernia through the uterine broad ligament. *Organe de la Societe Royale Belge de Radiologie*, 82, 151-2.
9. Newsom, BD, Kukora, JS. (1986). Congenital and acquired internal hernias, unusual causes of small bowel obstruction. *Am J Surg*, 152, 279-285.
10. Schumpelick V, Dreuw B, Ophoff K et al. (2000). Appendix and cecum, Embryology, anatomy, and surgical applications. *Surg Cl North Am*, 80, 295-318.
11. Meyer A, Nowotny K, Poeschl M. (1963). Internal hernias of ileo-caecal region. *Ergebnisse der Chirurgie und Orthopadie*, 44, 176-204.
12. Sciacca P, Bertolini R, Borrello M et al. (1997). Intestinal obstruction due to paracecal hernia. Description of three cases and review of the literature. *Minerva chirurgica*, 52, 983-8.
13. Ohishi, J, Yoshioka, S, Maki, T et al. (). Two cases of paracecal hernia. *Japanese J Gastroenterol Surg*. 2004, 37, 1894-9.
14. Rivkind, AIMD, Shiloni, EMD, MuggiaSullam, MMD et al. (1986). Paracecal hernia, A cause of intestinal obstruction. *Dis Colon Rect*, 29, 752-4.
15. Boudiaf M, Soyer P, Terem C et al. (2001). CT evaluation of small bowel obstruction, Radiographics, a review. *Publication of the Radiologic Soc North Am*, 21, 613-624.
16. Blachar A, Federle MP. (2002). Internal hernia, An increasingly common cause of small bowel obstruction. *Semi Ultrasound CT and MRI*, 23, 174-183.
17. Blachar A, Federle MP, Brancatelli G et al. (2001). Radiologist performance in the diagnosis of internal hernia by using specific CT findings with emphasis on transmesenteric hernia. *Radiology*, 221, 422-8.
18. Blachar A, Federle MP, Forrest Dodson, S. (2001). Internal hernia, Clinical and imaging findings in 17 patients with emphasis on CT criteria. *Radiology*, 218, 68-74
19. Omori, H, Asahi, H, Inoue, Y, et al. (2001). Laparoscopic paracecal hernia repair. *J Lap Adv Surg Tech*, 13, 55-7.
20. Kabashima A, Ueda N, Yonemura Y et al. (2010). Laparoscopic surgery for the diagnosis and treatment of a paracecal hernia repair, Report of a case. *Surg Today*, 40, 373-5.
21. Hirokawa T, Hayakawa T, Tanaka M et al. (2007). Laparoscopic surgery for diagnosis and treatment of bowel obstruction, Case report of paracecal hernia. *Medical Science Monitor*, 13, CS79-82.

