



## MANAGEMENT OF HORIZONTAL AND OBLIQUE CROWN FRACTURE OF ANTERIOR TEETH BY REATTACHMENT USING FIBER POST : A CASE REPORT

Paromita Mazumdar<sup>1</sup>, Utpal Kumar Das<sup>2</sup>, Sanhita Goswami<sup>3</sup>

<sup>1</sup>Associate Professor, <sup>2</sup>Professor and H.O.D, <sup>3</sup>Post Graduate Student,  
Department of Conservative Dentistry & Endodontics, Guru Nanak Institute of Dental Sciences and Research,  
157/F Nilgunj Road, Panihati, Kolkata-700114.

Corresponding Author:- **Sanhita Goswami**  
**E-mail:** [sanhita.goswami18@gmail.com](mailto:sanhita.goswami18@gmail.com)

<p><b>Article Info</b> <i>Received 15/08/2014</i> <i>Revised 27/08/2014</i> <i>Accepted 22/09/2014</i></p> <p><b>Key words:</b> dental trauma, crown fracture, esthetic rehabilitation.</p>	<p><b>ABSTRACT</b> Coronal fractures of the anterior teeth are a common form of dental trauma that mainly affects children and adolescents. One of the options for managing coronal tooth fractures is reattachment of fracture fragments keeping in mind factors like site and extent of fracture, involvement of biologic width etc. Reattachment of fractured tooth fragments by use of glass fiber post restores esthetics, function, provides a positive psychological response, and is a relatively simple procedure. Patient cooperation and understanding of the limitations of the treatment is of utmost importance for good prognosis. This article reports on a coronal tooth fracture case that was successfully treated using tooth fragment reattachment by fiber post.</p>
---	--

### INTRODUCTION

Dentoalveolar trauma resulting from an accidental fall, a traffic accident, contact sports or play—is frequently encountered by dental practitioners. Dental trauma can cause fractures in the maxillary anterior teeth leading to esthetic, functional and phonetic problems. Because of protrusion, or their alignment in the dental arch, maxillary incisors are the teeth most commonly involved in dental trauma [1].

Treatment options for such fractures include reattachment, fragment removal and immediate restoration, restoration after gingivectomy or osteotomy, forced orthodontic extrusion, forced surgical extrusion, vital tooth submergence, resin crowns, ceramic crowns and resin composite restoration with and without pins or tooth extraction followed by rehabilitation.

Several factors influence the conservative management of tooth fractures, including the extent and pattern of fracture, restorability of the fractured tooth, secondary injuries, the presence or absence of the fractured tooth fragment and its condition (the fit between the

fragment and the remaining tooth structure), occlusion, esthetics, cost and prognosis [2].

Technical, biologic and esthetic problems are exacerbated when the fracture extends subgingivally and impinges on the biologic width, as access to the most cervical margin of the fracture and adequate isolation of the operating field area are difficult to achieve. If the fracture extends further subgingivally, flap surgery, combined with osteoplast/osteotomy procedures, is typically required [3]. Reattachment of tooth fragment is a conservative, esthetic and cost-effective restorative option that has been shown to be an acceptable alternative to restoration with a resin-based composite or a full crown. Advantages include maintaining the colour and size of the original tooth, the emotionally and socially positive response due to preservation of the natural tooth structure and the rapid and conservative nature of the treatment [4]. Glass-fiber posts with adhesive can be used to reattach the tooth fragments [5,6]. Using this technique, the fractured tooth pieces can be bonded to one another and root



reinforcement can be achieved. This reduces stress in the tooth, catastrophic root fractures<sup>7</sup> and creates a central support stump to restore the dental morphology [7]. Clinical trials and long-term follow-up have reported that treatment using modern dentin-bonding agents or adhesive luting systems may achieve good functional and esthetic results [8].

This clinical report describes the treatment of horizontal and oblique crown fractures in upper central and lateral incisors using a reattachment technique with Glass-fiber posts, light cured composite resin and full veneer crowns.

### Case Report

An 18-year-old boy presented with horizontal cervical fracture in the right upper central and a split oblique fracture in the right upper lateral incisor along with subluxation in the left upper central incisor in the department of Conservative Dentistry & Endodontics, Guru Nanak Institute of Dental Sciences and Research, Sodepur, Kolkata. Clinical and radiographic examination revealed complex crown fractures. The fracture line extended a little below the gingival level at the palatal surfaces of the lateral incisor. While the fracture was horizontal in upper central incisor, the lateral incisor crown was split in an oblique manner. The fractured fragments of both teeth were mobile but held in place (fig 1 a and 1b).

The fracture line in the upper central incisor incorporated gingival ingrowth and made isolation difficult to achieve. So removal of entrapped tissue was done and preliminary reattachment of the fragments in 11 was carried out with glass ionomer cement. In case of 12, since split fracture of the crown allowed access into the root canal and optimal isolation was achieved, reattachment of the fragments was done with composite resin, keeping a no 10 K file in the root canal to avoid inadvertent entry of composite resin and blockage in the root canal space. Both the teeth were then immobilised by splinting the upper anterior segment with light cured composite resin from 13 to 23.(fig 2). Gingivectomy was performed in 11 and 12 to expose the fracture line. Access cavity was prepared in 11 and endodontic treatment was performed (BMP upto # F4 was done in 11 and upto # F3 in 12)(fig 3). Obturation was done with gutta percha by lateral compaction technique(fig 4). Although isolation with rubber dam is considered a pre-requisite for successful endodontic treatment, it was not possible in this case to prevent iatrogenic trauma and the risk of disengagement of fracture fragments owing to the cervical location of fracture line.

Removal of gutta percha was done in the same appointment from 11 and 12 by a hot endodontic plugger with minimal apical pressure keeping 4-5mm of apical gutta-percha intact to provide the apical seal (fig 5). Peeso reamers were not used to prevent transmitting undue stresses to the fractured fragments causing separation.

The root canal spaces of 11 and 12 were treated with Multilink Automix selfcuring primer according to the

manufacturer's instructions. The fiber posts (Tenax R Fiber White, Coltene) were treated with silane coupling agent and cemented in the individual root canal spaces using dual cure adhesive resin cement(Multilink Automix , Ivoclar Vivadent)following the manufacturer's instructions and light cured(Bluephase N, Ivoclar Vivadent) for 20 secs(fig 6).

Thus intraradicular stabilisation of the fractured teeth was achieved and patient was recalled after 2 weeks. Both 11, 12 and 21 were discluded (fig 7).

After 2 weeks the patient was asymptomatic and the teeth showed no mobility. The patient was recalled again after 2 weeks (fig 8).

At 4th week, the splint was removed. The teeth showed no mobility. Tooth preparation for PFM crown was done in both 11 and 12 and temporary crowns were given(fig 9). The patient was recalled again after 72 hrs and PFM crown fixation was done in 11 and 12 and esthetics was restored (fig 10).

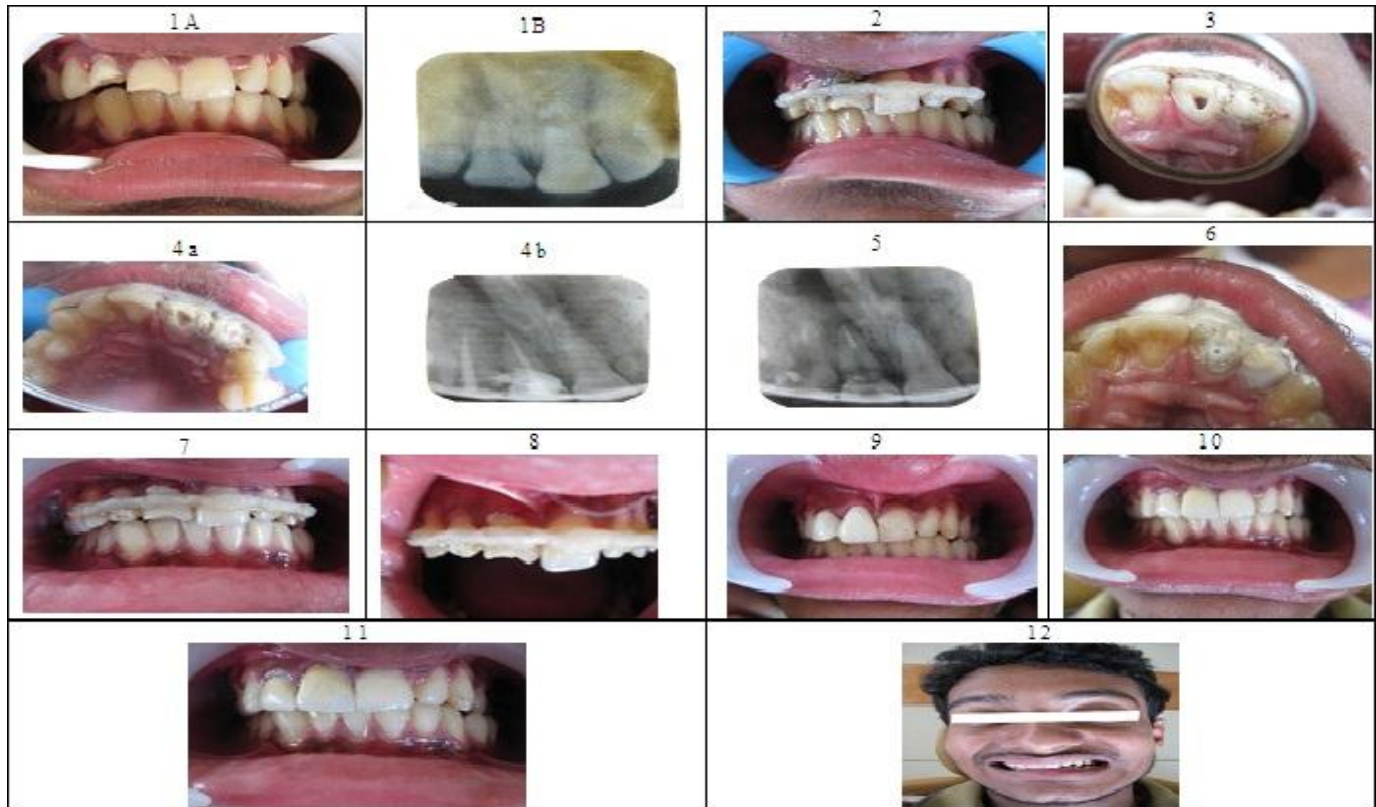
### DISCUSSION

Loss of the coronal part of a permanent incisor in a young patient can cause esthetic and functional problems, which in turn can lead to severe emotional problems. Extraction must not be the first treatment choice for fractured and extremely broken down, permanent teeth in the anterior region [9]. Although evidence based literature shows that materials do not play an important role in fracture strength recovery, the advantage of reattachment of fractured fragments include immediate esthetics, possibility of maintaining the occlusal function, absence of differential wear, lowered economic burden and excellent time resource management [10]. The direction of fracture line is an important aspect in reresstorability and has a direct bearing on the prognosis of teeth. The fracture line was in a favourable direction in that it did not extend deep into the alveolus in the case undertaken. Extensive damage of the tooth structure and missing fragment warrants reinforcement using fiber posts. Tooth colored fiber posts have several advantages .They are more aesthetic, bonded to tooth tissue, modulus of elasticity similar to that of dentin and less chances of fracture. An additional use of fiber posts is that it helps to distribute the stress to remaining radicular dentin and causing intraradicular stabilization of fracture fragments. When they are used with resin cements they have a decreased chance of micro leakage .The resin luting cements exhibits good bond strength to the tooth, easy to use and predictable. The most common complication of post and core system is debonding ; another reason for failure is root fracture. Restoration with cast metal posts can cause wedging forces coronally that may result in irreversible failure because of fracture of an already weakened root. Whereas fiber-reinforced composite resin post has demonstrated negligible root fracture. In addition, the fiber-reinforced posts are used with minimal preparation because it uses the undercuts and surface irregularities to increase the surface



area for bonding, thus reducing the possibility of tooth fracture during function or traumatic injury [11]. Since in this case minimal invasion of biologic width occurred, gingivectomy of 1 mm was performed eliminating the need for flap surgery with ostectomy. Moreover the treatment

time for the orthodontic extrusion is a drawback and the image-conscious patient may not want to wait for a definitive esthetic restoration following orthodontic treatment.



Conflict of interests:- none

## CONCLUSION

The patient is followed up periodically and as of 2 months postoperative till date, the involved teeth are completely functional with no mobility, pain and discomfort (fig 11 and 12). The patient will be recalled at 6 months, 8 months and 12 months intervals for periodic follow-up.

However further long-term studies should be conducted to establish the success of this technique as an effective method to treat cases of complicated fracture in anterior teeth.

## REFERENCES

1. Bora Bagis, Yavuz Tolga Korkmaz, Fatih Mehmet Korkmaz, Rukiye Durkan, Ali Alper Pampu. (2011). Complicated Subgingivally Fractured Central and Lateral Incisors: Case Report. *J Can Dent Assoc*, 77b, 145.
2. Macedo GV, Diaz PI, De O Fernandes CA, Ritter AV. (2008). Reattachment of anterior teeth fragments: a conservative approach. *J Esthet Restor Dent*, 20(1), 5-18, 19-20.
3. Oz IA, Haytaç MC, Toroglu MS. (2006). Multidisciplinary approach to the rehabilitation of a crown-root fracture with original fragment for immediate esthetics: a case report with 4-year follow-up. *Dent Traumatol*, 22(1), 48-52.
4. Yilmaz Y, Zehir C, Eyuboglu O, Belduz N. (2008). Evaluation of success in the reattachment of coronal fractures. *Dent Traumatol*, 24(2), 151-8.
5. Durkan RK, Ozel MB, Celik D, Bağış B. (2008). The restoration of a maxillary central incisor fracture with the original crown fragment using a glass fiber-reinforced post: a clinical report. *Dent Traumatol*, 24(6), e71-5.
6. Oliveira GM, Oliveira GB, Ritter AV. (2010). Crown fragment reattachment: report of an extensive case with intra-canal anchorage. *Dent Traumatol*, 26(2), 174-81.
7. Altun C, Tözüm TF, Güven G. (2008). Multidisciplinary approach to the rehabilitation of a crown fracture with Glass-fiber-reinforced composite: a case report. *J Can Dent Assoc*, 74(4), 363-6.

8. Andreasen FM, Norén JG, Andreasen JO, Engelhardt S, Lindh-Strömberg U. (1995). Long-term survival of fragment bonding in the treatment of fractured crowns: a multicenter clinical study. *Quintessence Int*, 26(10), 669-81.
9. Mamta Dali. (2013), Management of complicated crown fracture by reattachment technique: A clinical report. 1(2), 46-49.
10. Hegde Deepak Divakar, Moksha Nayak, Rajesh Shett. (2007). Changing concepts in fracture reattachment of teeth, A case series. *Eur J Dent*, 1(3), 174–178.
11. Yahya Orcun Zorba and Erdal Özcan. (2007). Reattachment of Coronal Fragment Using Fiber-Reinforced Post: A Case Report. *Eur J Dent*, 1(3), 174–178.

