



## UNUSUAL PRESENTATION OF A POSTPARTUM OVARIAN VEIN THROMBOSIS AS AN OBSTRUCTIVE ACUTE PYELONEPHRITIS: A CASE REPORT AND REVIEW OF THE LITERATURE

**Tlili Ghassen\*, Bouassida Khaireddine, Ben Ahmed Khaled, Hmida Wissem, Jaidane Mehdi, Mosbah Ali Faouzi**

Teaching Hospital of Sahloul, Department of Urology. Sousse, Tunisia.

Corresponding Author:- **Tlili Ghassen**  
E-mail: [g\\_tlili@yahoo.fr](mailto:g_tlili@yahoo.fr)

<p><b>Article Info</b> <i>Received 18/11/2015</i> <i>Revised 29/11/2015</i> <i>Accepted 15/12/2015</i></p> <p><b>Key words:</b> Ovarian vein, Thrombosis, Post partum, Pyelonephritis, Uretero hydronephrosis.</p>	<p><b>ABSTRACT</b> Ovarian vein thrombosis (OVT) is a rare postpartum complication. Although infrequent, it may progress to involve the inferior vena cava, the renal vein and it may also cause sepsis and septic pulmonary embolism, all of which are potentially life-threatening. Clinical misdiagnosis is common and unfortunately most affected women undergo laparotomy for suspicion of appendicitis. This case illustrates an unusual presentation of postpartum OVT as acute pyelonephritis.</p>
--	--

### INTRODUCTION

The postpartum OVT is a rare pathological entity whose first case was described in 1956 by AUSTIN [1]. The incidence varies, depending on the series, between 0.18% and 0.049% of pregnancies [2] [3] [4]. 90% of cases present right abdominal pain, within 10 days of the puerperal period [5].

However, in our knowledge the presentation of a postpartum OVT as ureteral obstruction has only been reported in the literature seven times previously and only two cases of OVT miming an obstructive pyelonephritis has been reported. Here is a rare case of an unusual presentation of a postpartum OVT as right obstructive pyelonephritis.

We will discuss the physiopathology, epidemiology, clinical and therapeutic aspects of this disease through the study of this case and a review of the literature.

### Case report

A 34 - year - old woman presented at 13 days postpartum to an emergency department with severe stabbing, a right flank pain associated with fever and thrills. On examination, the patient was febrile (temperature 39.5 degrees) and we found a tenderness on the palpation of the right lumbar and the right flank however the other parts of the abdomen were soft and non-tender, with no organomegaly. Urine dipsticks were positive.

Her antenatal period was uneventful. She had a spontaneous vaginal delivery of a live born-term female. The immediate postpartum period was unremarkable. There was no other significant past medical or surgical history.

Laboratory analysis showed a leucocytosis of 18000 cells/mm<sup>3</sup> and a protein C-reactive (CRP) level of 163 mg/L.



The diagnosis of acute right pyelonephritis was established.

Abdominopelvic ultrasonography with Doppler (Figure 1) associated with abdominal computed tomography (CT) with intravenous contrast (Figures 2 and 3) revealed a thrombosis of the right ovarian vein which became dilated and causes compression of the right ureter responsible of hydronephrosis (Figure 3).

We conclude that the thrombus was probably responsible for the ureter obstruction and then for the urine infection.

Medical treatment was immediately introduced, combining antibiotics and continuous intravenous infusion of 400 units / kg / day of heparin.

200 mg of intravenous Ciprofloxacin was administrated every 12 hours for 48 hours then relayed by

oral form during 14 days. Urine culture was positive for fluoroquinolone-sensitive E. coli.

A right ureteral double J stent was inserted to treat the obstruction temporarily.

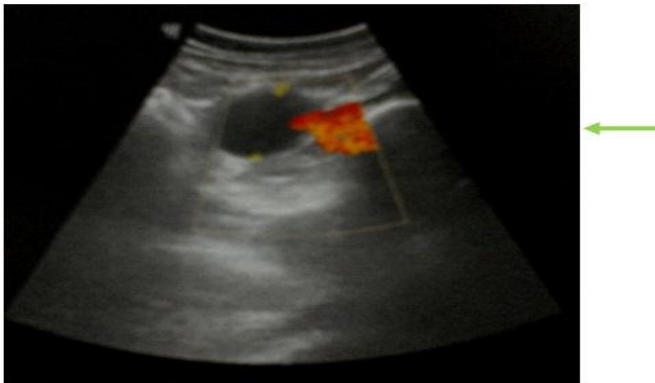
A switch to oral anticoagulant was performed 7 days after the infusion of intravenous heparin.

Vitamin K antagonist has been taken for 6 months with the International Normalized Ratio (INR) maintained between 2 and 3.

The outcome was favorable, the patient was afebrile 24 hours after starting the treatment and the lumbar pain disappeared.

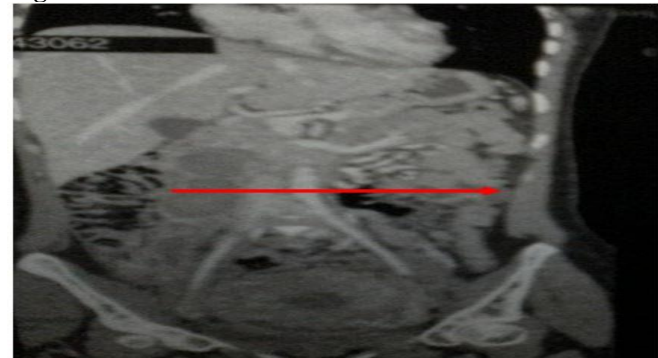
A CT scan was performed 3 months later and it showed the vanishing of the OVT with no right hydronephrosis and the double-J stent was removed.

**Figure 1. Abdominopelvic Ultra Sono Graphy with Doppler Revealed a Thrombosis of the Right Ovarian Vein**



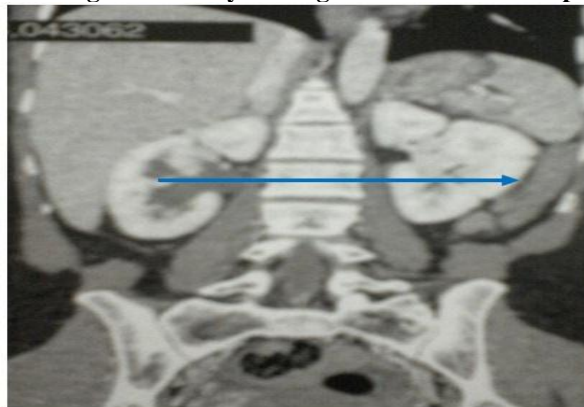
Green arrow: Thrombosis of the right ovarian vein

**Figure 2. Abdominal Computed Tomo Graphy with Intravenous Contrast Revealed a Thrombosis of the Right Ovarian Vein Which Became Dilated**



Red arrow: dilatation of the right ovarian vein

**Figure 3. Compression of the Right Ureter by the Right Ovarian Vein Responsible of Hydronephrosis**



Blue arrow: right uretero-hydronephrosi

## DISCUSSION

OVT during the puerperium is a rare pathology that is characterized by inflammation or thrombosis of one or both ovarian veins [4]. It occurs in the right ovarian vein in 80% to 90% of the cases [3]. This is believed to be due, in part, to the commonly occurring dextrotorsion of the enlarging uterus, which causes compression of the right

ovarian vein and right ureter as they cross the pelvic brim or to the incompetent valves of the right ovarian vein that are a cause for stasis. The right ovarian vein is also longer than the left and has many valves which may act as niduses for thrombus formation [6]. In addition, during pregnancy there is an increase in the retrograde drainage from the left

to right ovarian vein, which results in a greater number of bacteria entering the right ovarian vein [2]. Furthermore, due to hormonal and mechanical changes that occur during gestation, a state of hypercoagulability persists from pregnancy up to 6 weeks after delivery [7]. The typical presentation of OVT includes fever, Lower quadrant pain and flank pain with associated nausea. Leukocytosis of more than  $12\,000/\text{mm}^3$  occurs in 70% to 100% of the cases [2,8]. The differential diagnoses of ovarian vein thrombosis are appendicitis, septic pelvic thrombophlebitis, ureteric colic with sepsis, peritonitis, adnexal torsion, pyelonephritis and tubo-ovarian abscess [9]. The first case of postpartum OVT presenting as ureteral obstruction was reported in 1974 by Schapira et al [10]. In our knowledge only 2 cases of acute pyelonephritis caused by OVT were reported in the literature, this is probably due to the ureter compression and to the urine stagnation which promotes infections.

Prior to the advent of modern imaging tools, the only definitive way to diagnose OVT was by surgery, but the mortality was high [7]. Currently, positive diagnosis of postpartum OVT can be made by Ultrasonography, Magnetic resonance imaging (MRI) or CT scan with a sensitivity of 52%, 92% and 100%, respectively [11]. Doppler Study of inferior vena cava (IVC) and ovarian veins also show the thrombus and is a useful tool for follow up [12]. Magnetic resonance angiography can provide a better and more reliable visualization of the vascular systems and the coronal source images are useful in evaluating the extent of the thrombus. CT scan study with bolus injection of iodinated contrast and a conventional venography are also accurate methods for diagnosing postpartum OVT.

OVT is treated initially with broad-spectrum antibiotics and intravenous heparin. Prompt resolution of symptoms, within 24 to 72 h, has been reported with therapeutic heparin therapy [2] [8], as in our case. Once thrombolysis has begun, warfarin is introduced and continued for 3 to 6 months. Antibiotics are continued for

at least 1 week [9] [13]. Ureteral extrinsic compression can be treated by placing a long duration double-J stent. Historically, early laparotomy for diagnosis and treatment was recommended once OVT was suspected. Currently, surgery is indicated in some cases after failure of conservative therapy or when the risk of pulmonary embolism is high [2].

## CONCLUSION

Diagnosis and treatment of OVT are non-invasive in 90% of cases. It is therefore necessary to entertain a diagnosis of postpartum OVT when faced with a postpartum patient with lower quadrant abdominal pain and fever. The initial modality of study is an Ultrasound examination with Doppler. A high index of clinical suspicion should necessitate a CT or MRI scans for confirmation. Knowledge of this entity should guide to appropriate diagnosis and treatment, avoiding misdiagnosis, unnecessary laparotomy and potential complications.

## ACKNOWLEDGEMENTS

We would like to thank the College of Medicine Research Center (CMRC) at College of Medicine, King Saud University for funding of this study. KKA is supported by a grant from the Glaucoma Research Chair of the Department of Ophthalmology, College of Medicine, King Saud University, Riyadh, Saudi Arabia.

## CONFLICT OF INTEREST:

The authors declare that they have no conflict of interest.

## STATEMENT OF HUMAN AND ANIMAL RIGHTS

All procedures performed in human participants were in accordance with the ethical standards of the institutional research committee and with the 1964 Helsinki declaration and its later amendments or comparable ethical standards. This article does not contain any studies with animals performed by any of the authors.

## REFERENCES

1. Austin OG. (1956). Massive thrombophlebitis of the ovarian vein. A case report. *Obstet. Gynecol*, 72, 428-429.
2. Brown TK, Munsik RA. (1971). Puerperal ovarian vein thrombophlebitis, a syndrom. *Am J Obstet Gynecol*, 109, 263-273.
3. Dunning DR, Gallaspy JW, Wise RB, Otterson WN. (1991). Postpartum ovarian vein thrombophlebitis, a review. *Obstet. Gynecol. Surv*, 46, 415-427.
4. Munsik RA, Gillanders LA. (1981). A review of the syndrom of puerperal ovarian vein thrombophlebitis. *Obstet. Gynecol. Surv*, 36, 57.
5. Manjula Dhinakar, Logesan Dhinakar. (2010). Puerperal Ovarian Vein Thrombosis Presenting as Rt Loin Pain and Hydronephrosis, Report of 2 Cases. *Oman Medical Journal*, 25(4).
6. Savader SJ, Otero RR, Savader BL. (1988). Puerperal ovarian vein thrombosis, evaluation with CT, US and MR imaging. *Radiology*, 167, 637-9.
7. Chawla K, Mond DJ, Lanzkowsky L. (1994). Postpartum ovarian vein thrombosis. *Am J Emerg Med*, 12, 82-5.
8. Witlin AG, Mercer BM, Sibai BM. (1996). Septic pelvic thrombophlebitis or refractory postpartum fever of undetermined etiology. *J Matern Fetal Med*, 5, 355-8.
9. Warde L, McDermott EW, Hill AD et al. (2001). Post-partum ovarian vein thrombosis. *J R Coll Surg Edinb*, 46, 246-8.



10. Schapira HE, Mitty HA. (1974). Right ovarian vein septic thrombophlebitis causing ureteral obstruction. *J Urol*, 112, 451–3.
11. Baran GW, Frisch KM. (1987). Duplex Doppler evaluation of puerperal ovarian vein thrombosis. *AJR Am J Roentgenol*, 149(2), 321-322.
12. Al-toma A, Heggelman BG, Kramer MH. (2003). Postpartum ovarian vein thrombosis, report of a case and review of literature. *Neth J Med*, 61(10), 334-336.
13. Duff P, Gibbs RS. (1983). Pelvic vein thrombophlebitis, diagnostic dilemma and therapeutic challenge. *Obstet Gynecol Surv*, 38, 365–73.

